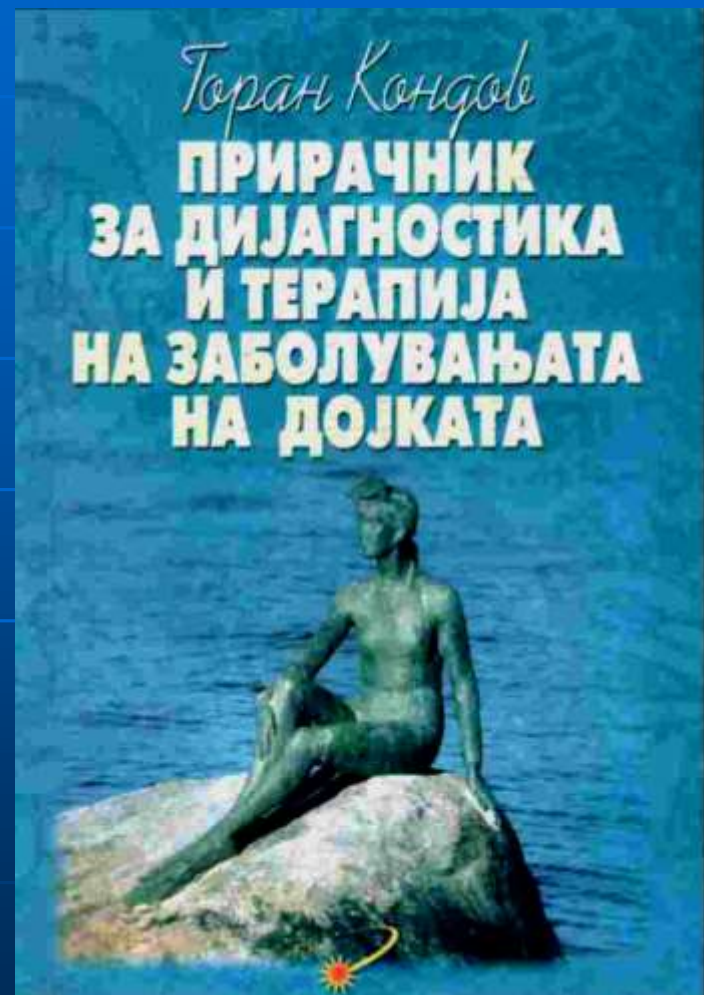
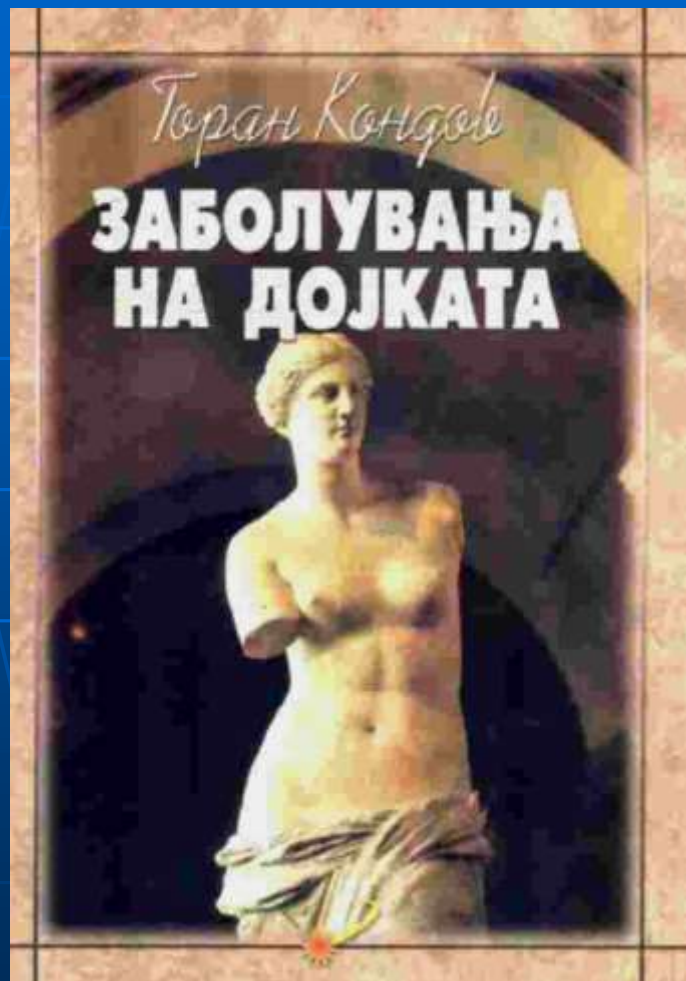
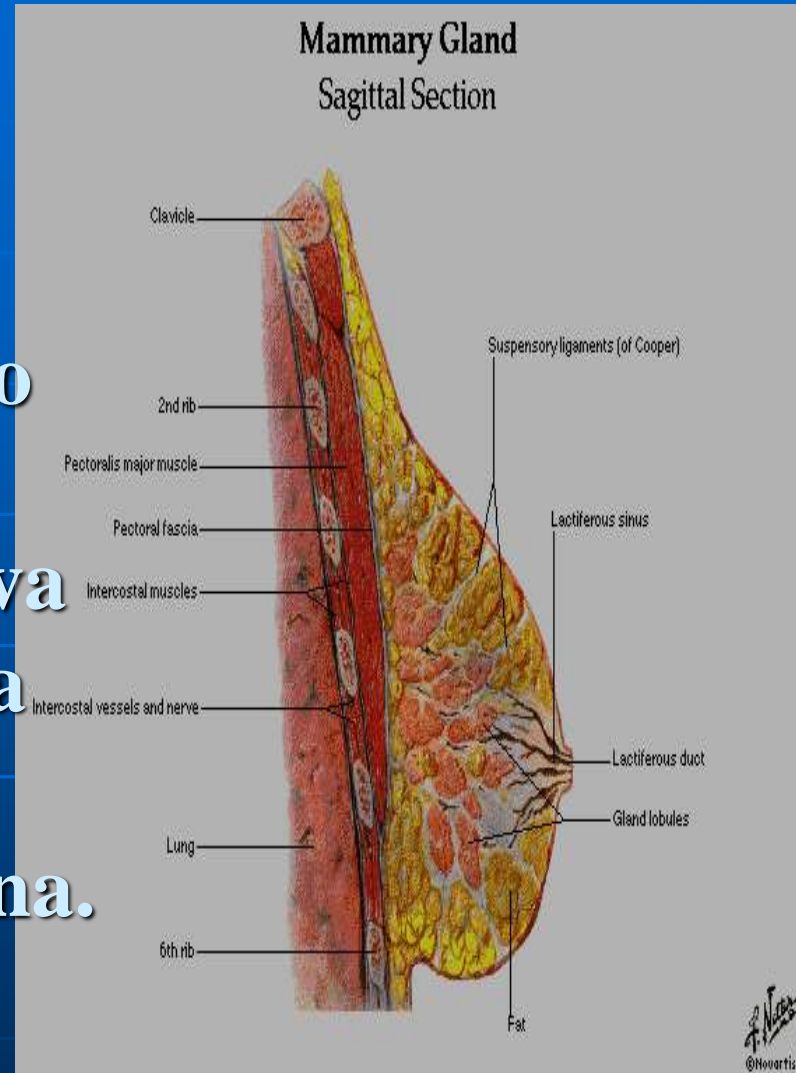


# Zaboluva na dojkata

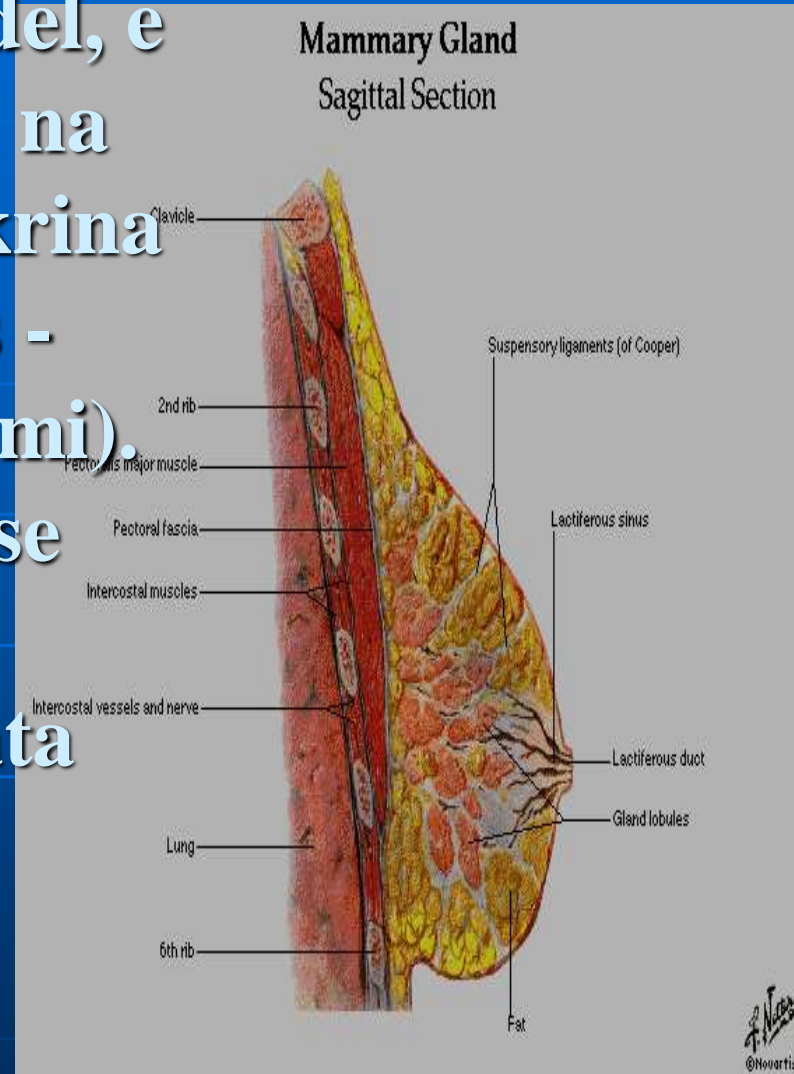
Prof. d-r Kondov Goran



Dojkata, mle~nata `lezda, **glandulae mammae**, e paren `lezden organ, karakteristi~en za cica~ite. Vo puberetetot pod dejstvo na polovite hormoni taa se razviva i dobiva forma koja se sre}ava kaj zrelata `ena, dodeka kaj ma`ite ostanuva rudementirana.



Dojkata, osobeno `lezdeniot del, e del od reproduktivniot sistem na `enata. Taa e pod neuroendokrina kontrola (**CNS** - hipotalamus - hipofiza - nadbubreg - ovariumi). @lezdenoto tkivo na dojkata se nao|a vo razli~na sostojba vo zavisnost od vojrasta, nejzinata reproduktivna sostojba i hormonskata sostojba na organizmot.





# Dijagnostika na promeni na dojkata:

- Koi se osnovni dijagnosti~ki metodi koi se primenuvaat vo dijagnostika na dojkata?

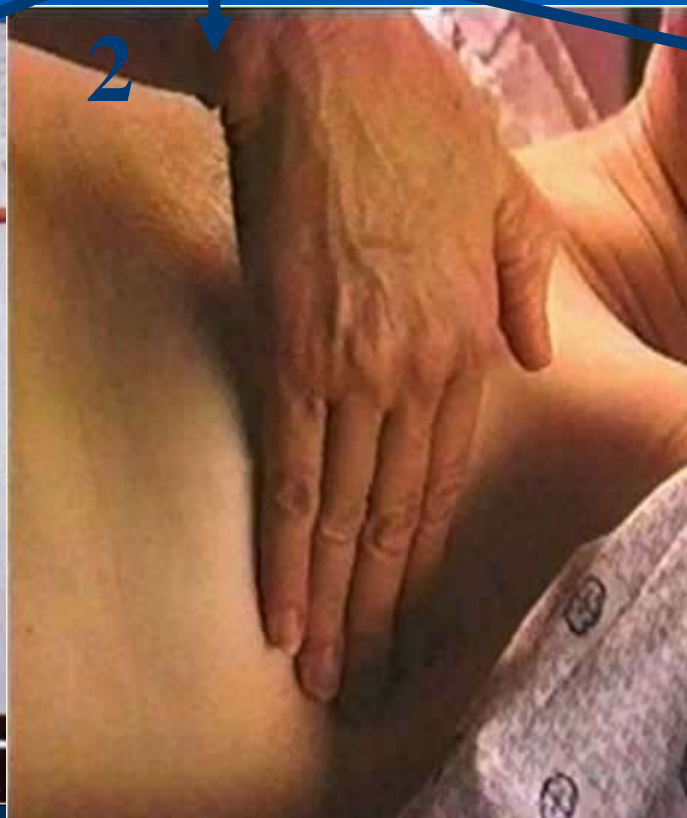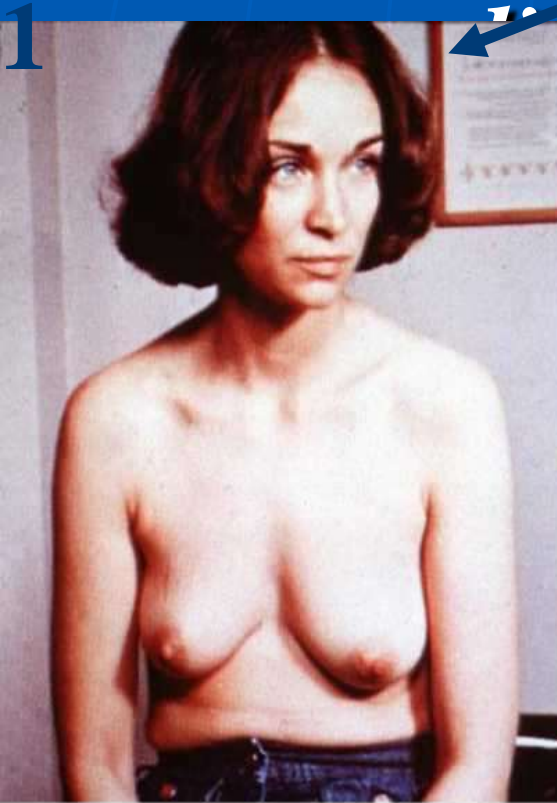# 1.

## Dijagnostika na promeni na dojkata:

- *klini~ki pregled*
- *radiodijagnostika*  
(ehotomografija i/ili mamografija)
- *fina tenkoiglena biospija.*
- *hirur{kata ekcizija*

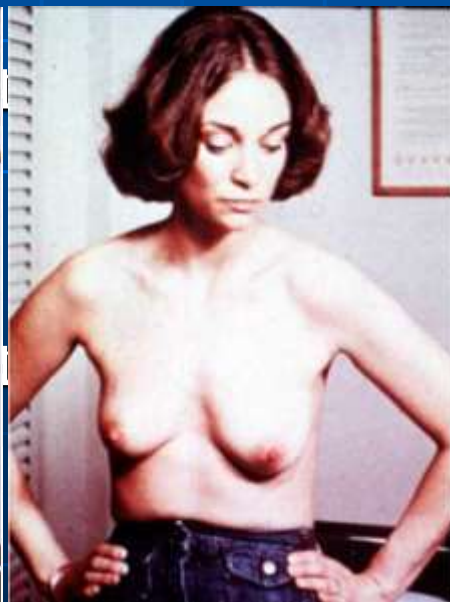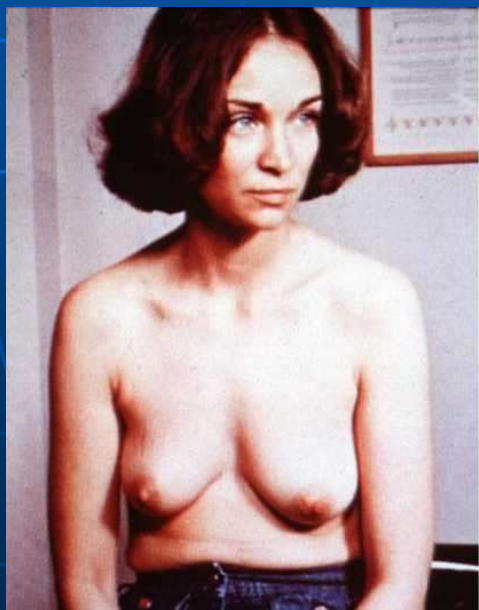# Dijagnostika na promeni na dojkata:

## ■ klinički pregled



# DOJKA

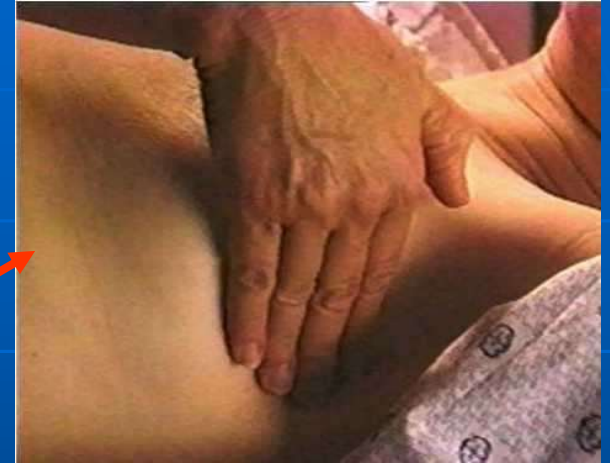## ■ .Inspekcija





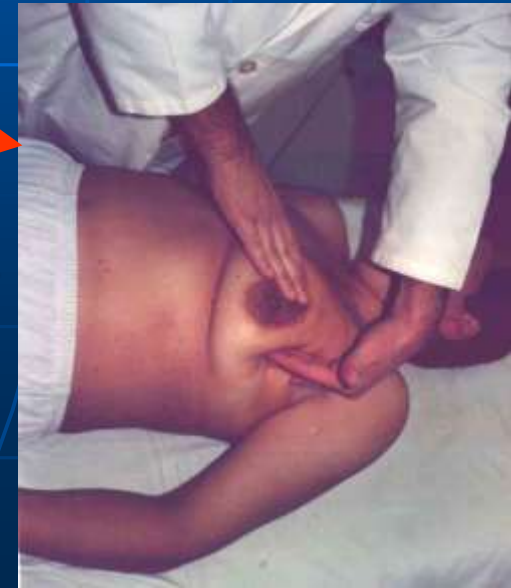# DOJKA

- .Inspekcija



- .Palpacija na dojka

- .Palpacija na aksilarna jama



# DOJKA

- .Inspekcija

- .Palpacija na dojka

- .Palpacija na aksilarna jama

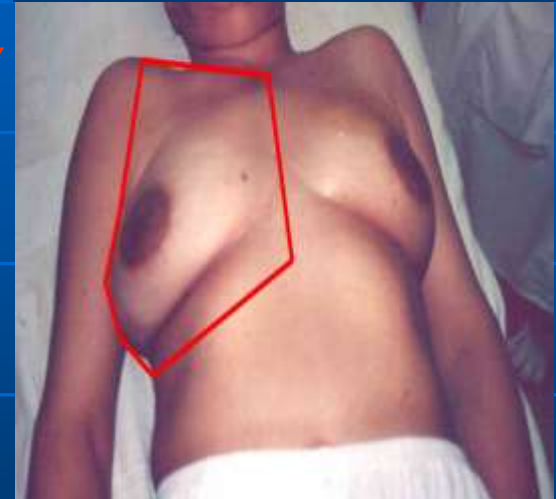

# DOJKA

- .Inspekcija

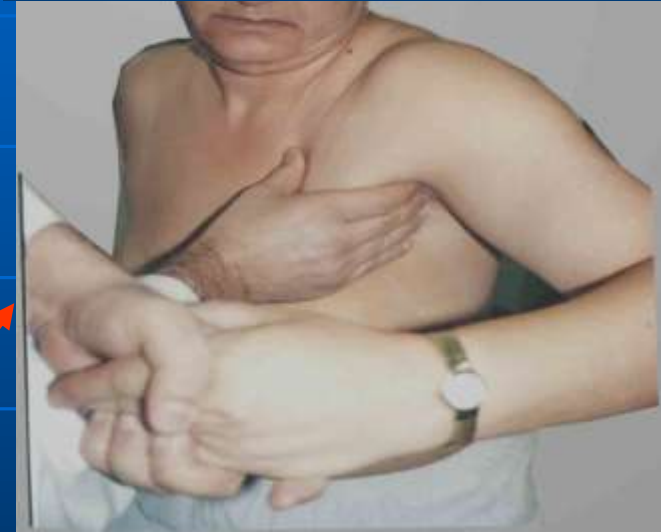- .Palpacija na dojka

- .Palpacija na aksilarna jama



# DOJKA

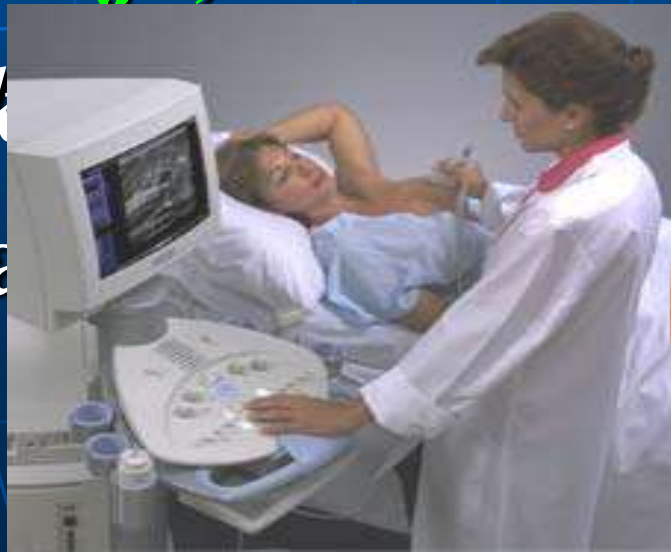- .Inspekcija
- .Palpacija na dojka
- .Palpacija na aksilarna jama



# Dijagnostika na promeni na dojkata:

- *klinički pregled*
- *radiodijagnostika*  
(*ehotomografija i/ili mamografija*)

- *fina tenka*
- *hirurška*

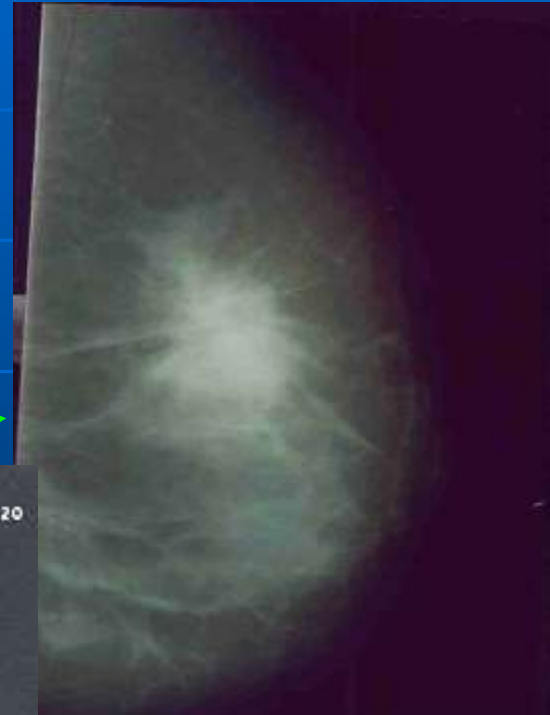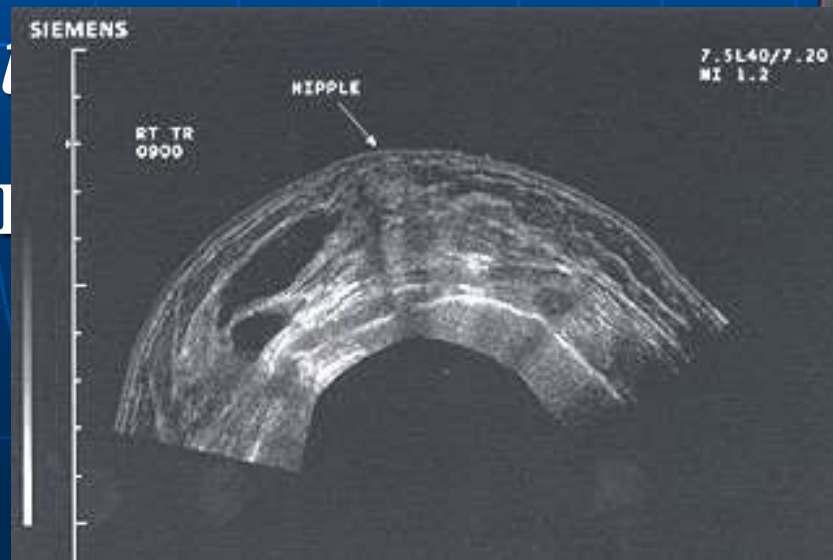


# Dijagnostika na promeni na dojkata:

- *klini~ki pregled*
- *radiodijagnostika*  
(ehotomografija i/ili mamografija)

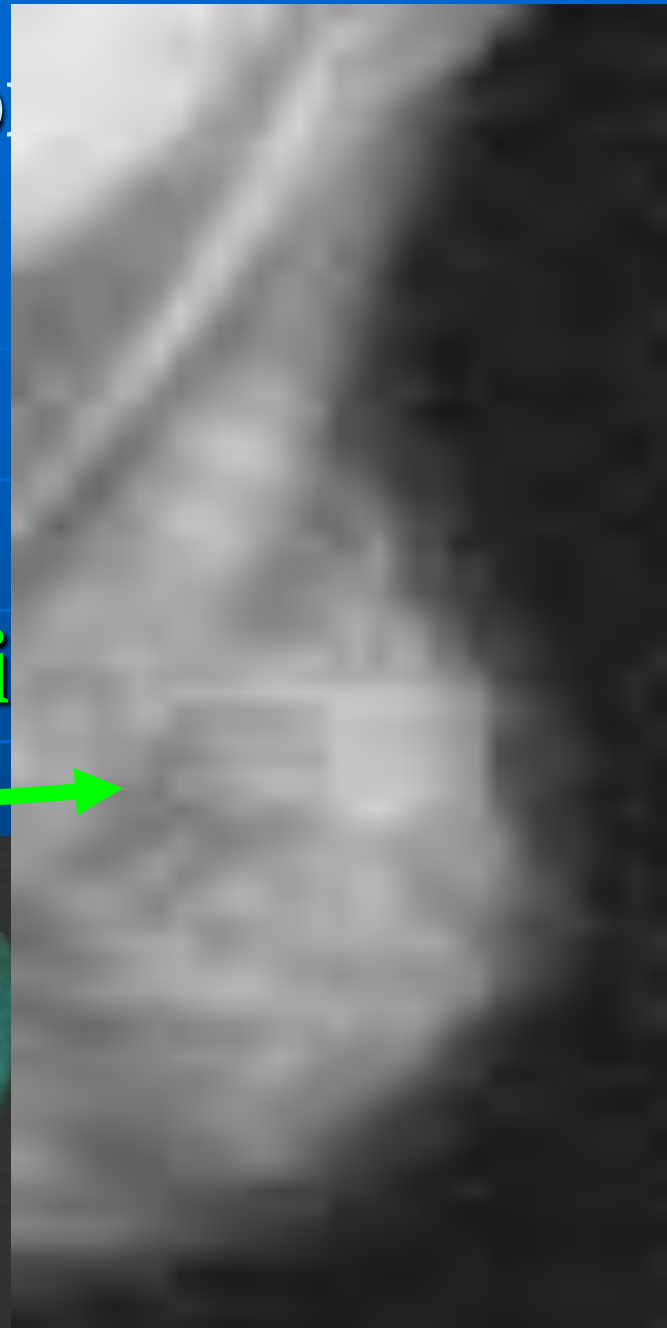
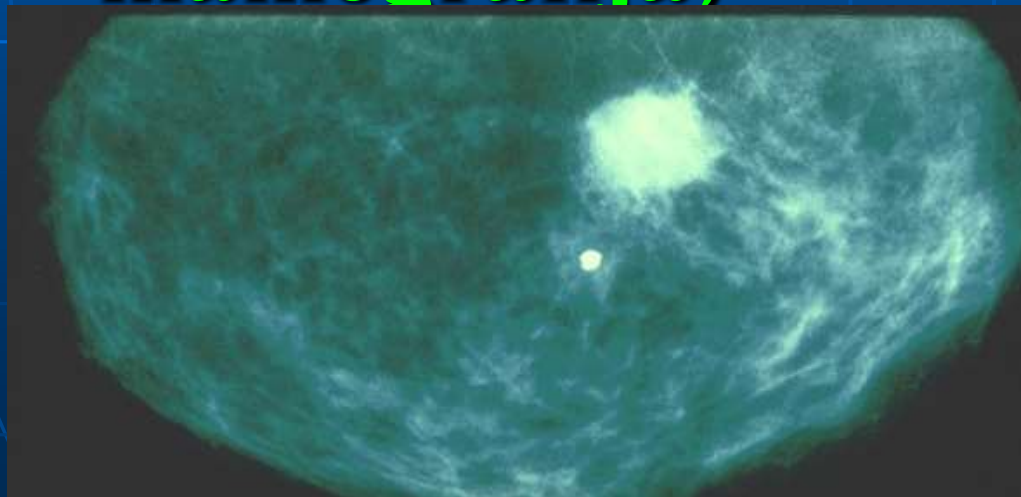
- *finalna*

- *hirur*



# Dijagnostika na pro dojkata:

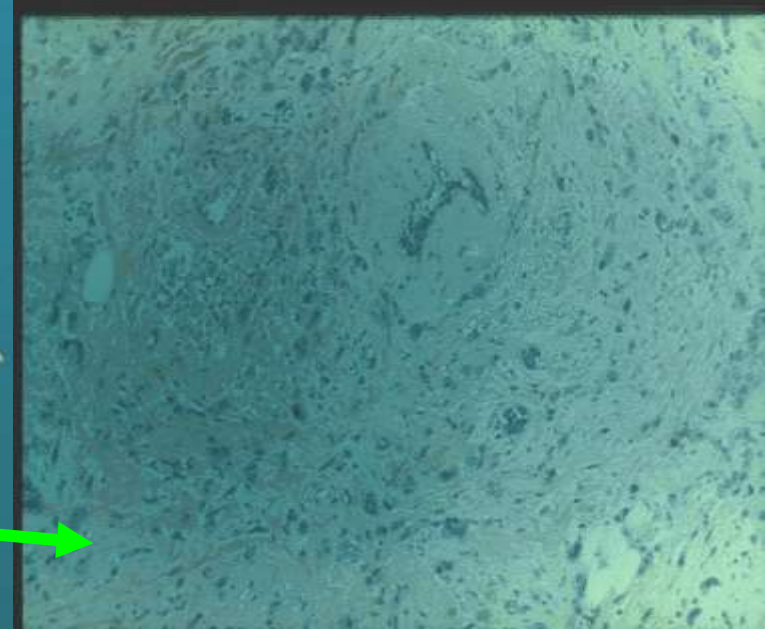
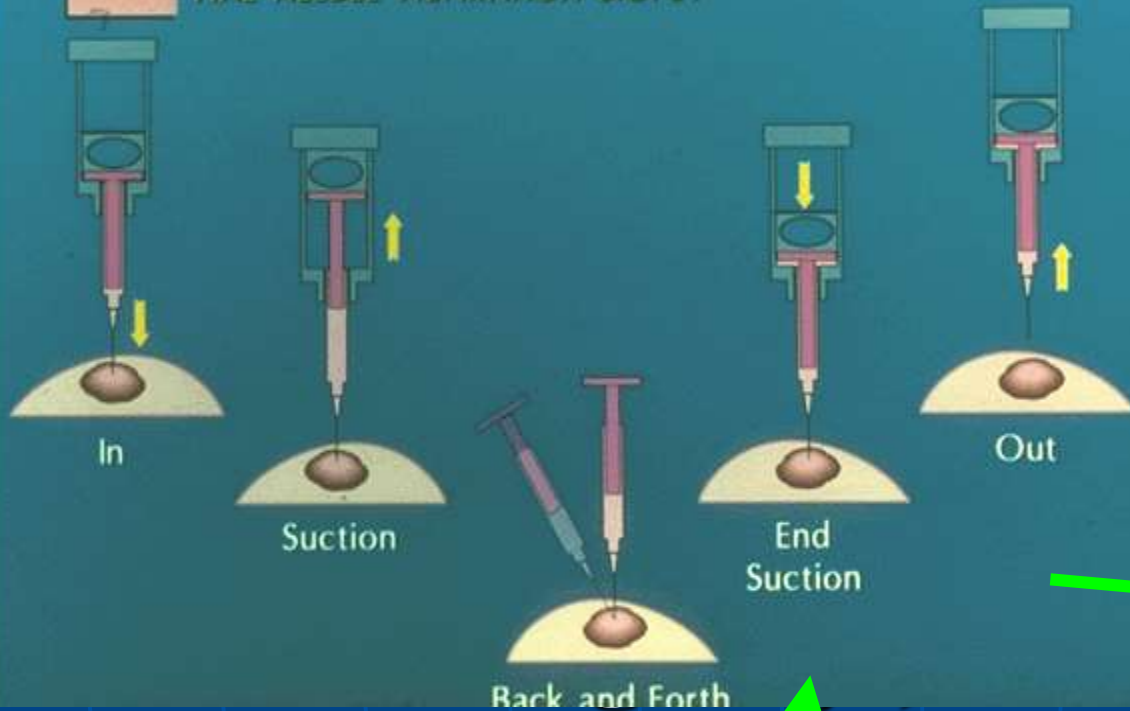
- *klini~ki pregled*
- *radiodijagnostika*  
(*ehotomografija i/ili*  
*mamografija*)



omeni na

## BREAST CANCER

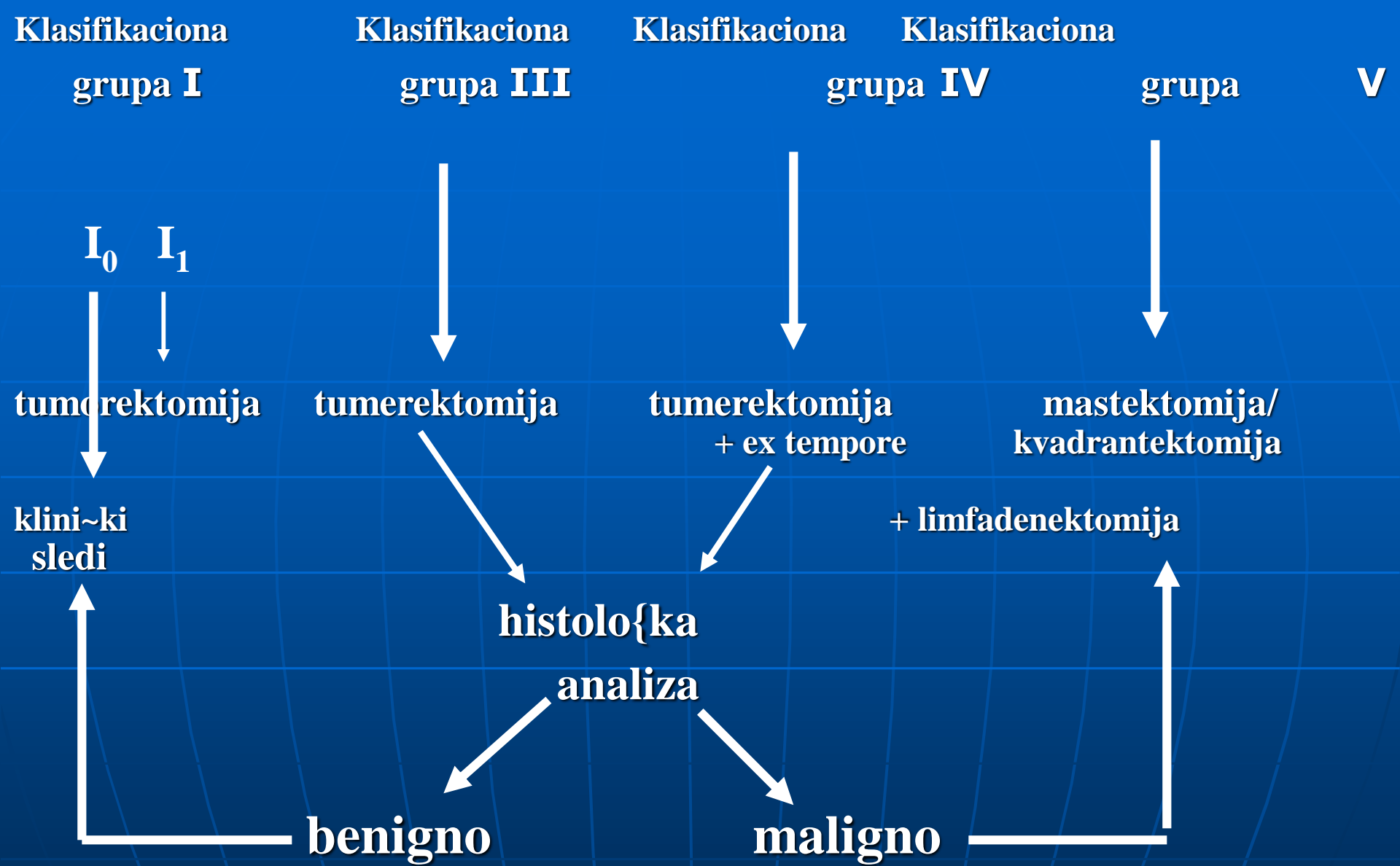
FINE-NEEDLE ASPIRATION BIOPSY



- *fina tenkoiglena biospija.*
- hirur{kata ekcizija

93%





# Dijagnostika na promeni na dojkata:

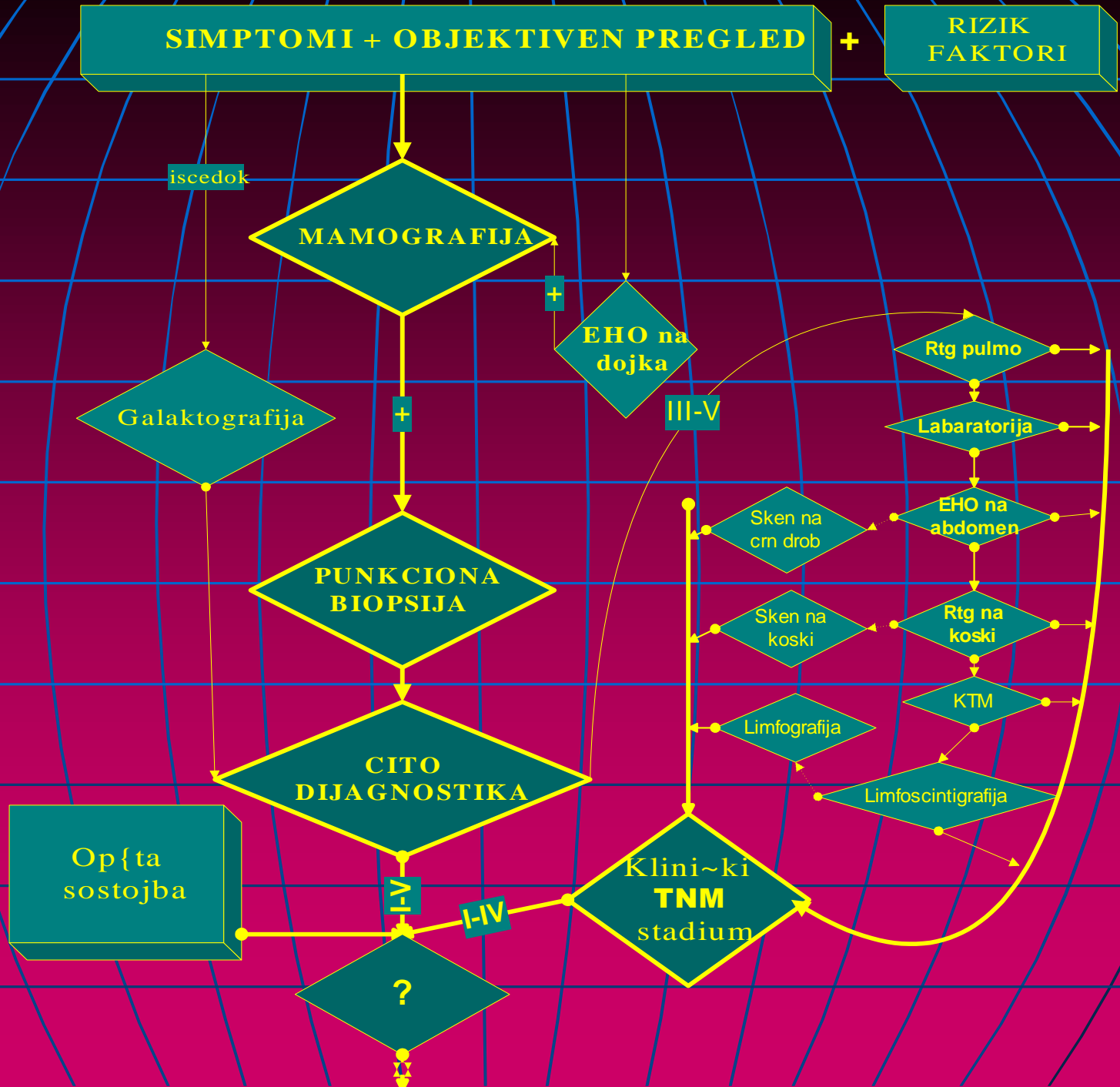
- *klinički pregled*
- *radiodijagnostika*  
(ehotomografija i/ili  
mamografija)
- *fina tenkoiglena biospij*
- **hirurška ekcizija**

**Trojna dijagnostička  
postapka**

**96,5%**

# Dijagnostika na promeni na dojkata:

- *klini~ki* Hirur{kata ekcizija e
- *radiodija* standarna procedura
- (ehotomo koga trojnoto
- mamogra ispituvawe ne daje
- definitiven rezultat.
- *fina ten*
- **hirur{kata ekcizija**



S A M O P R E G L E D N A D O J K I  
( mese ~ no )



SK RI N I N G  
( mamografski )

DG. P R O C E D U R I  
- mamografija  
- ehonadojki



suspektno neodređeno

palpabilna  
masa  
( necista )

neodređena  
suspektna

verojatno  
benigna

cista nepalabilna  
masa

f i n a t e n k o i g l e n a  
b i o p s i j a F N A

sledi

punkcija  
aspiracij

B I O P S I J A P O D  
K O N T R O L A N A

- ultrazvuk (s FNA)  
- Ro z r a c i (s FNA)

- ultrazvuk (s CNB)  
- Ro z r a c i (s CNB)

n e d o v o l n o  
m a t e r i j a l //

I I I

I V

V

f i n a t e n k o i g l e n a  
b i o p s i j a F N A

B I O P S I J A P O D  
K O N T R O L A N A

- u l t r a z v u k ( s F N A )  
R o z r a c i s F N A )

- u l t r a z v u k ( s C N B )  
- R o z a c i ( s C N B )

n e d o v o l n o  
m a t e r i j a l //  
n e o d r e d e n o

I

III

IV

V

b e n i g n a

m a l i g n o m

t u m e r e k t o m i j a +  
e x t e m p o r e

i s k l u ~ i  
M S

s l e d i

b e n i g n a

r a d i k a l n a o p e r a c i j a

t u m e r e k t o m i j a //  
h i s t o l o { k a d g .

- m a s t e k t o m i j a  
- k v a d r a n t e k t o m i j a

m a l i g n o m

h e m i o t e r a p i j a

n e o a d j u v a n t n a  
h e m i o t e r a p i j a

# DETEKCIJA NA SISTEMSKI METASTAZI

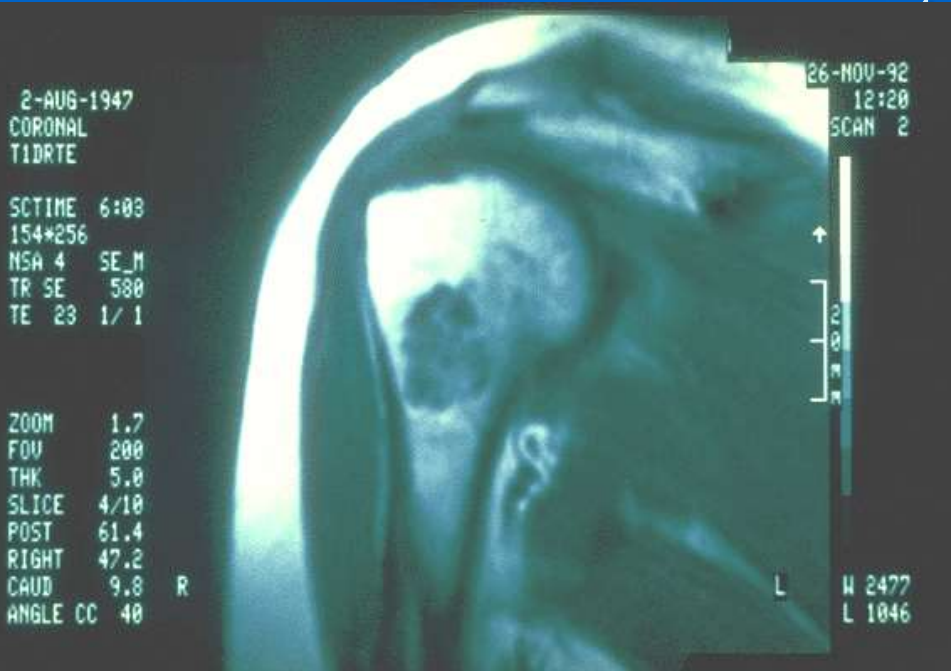- **.Rtg grafija na beli drobovi**
- **.Ehotomografija na abdomen**
- **.Rtg na koski**
- **Labaratorija (SE, ALP,  
hepatalni)**

# DETEKCIJA NA SISTEMSKI METASTAZI

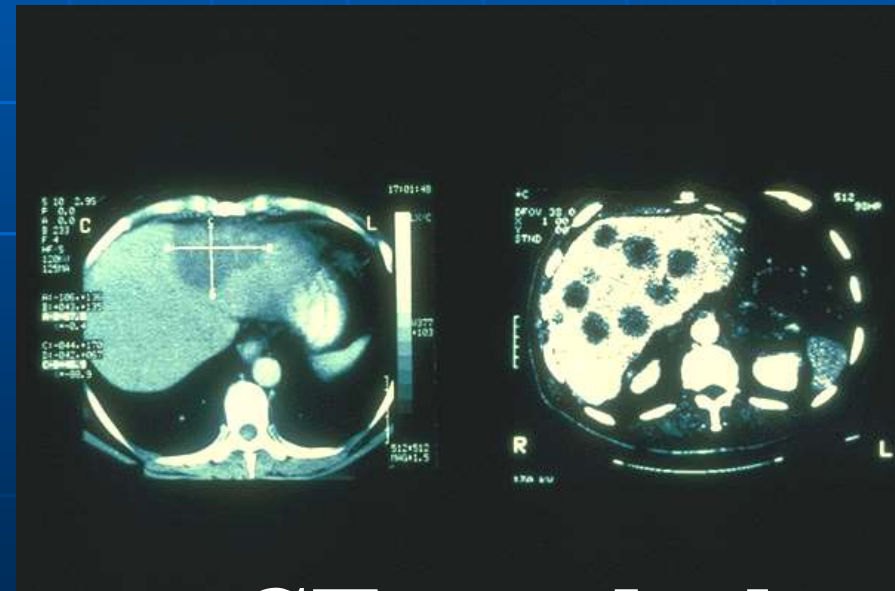
- **.CT na mozok**
- **.CT na beli drobovi**
- **.CT na abdomen**
- **.Sken na crn drob**
- **.Sken na koski**
- **Labaratorija (tumorski markeri)**



# Detekcija na astazi



**MRI- humerus**



**CT-crni drob**

2.

**Kade e potrebna primena na  
dijagnosti~ki proceduri?**

# 2.

## Kade e potrebna primena na dijagnosti~ki proceduri:

1. Diskretna masa vo dojkata.
2. Iscedok od dojkata.
3. Mastalgija (bolka vo dojkata).

# Kade e potrebna primena na dijagnosti~ki proceduri:

4. Vovlekuvawe na bradavkata, promena na konturi na ko`ata ili ekcema na bradavkata.
5. Na barawe od pacientkata koja nema simptomatologija a ima pozitivna familna istorija za malignom na dojka.

# 3. Novi dijagnostički proceduri

- digitalna mamografija
- CT
- NMRI
- termografija
- dopler ultrasonografija
- pozitron emisiona tomografija

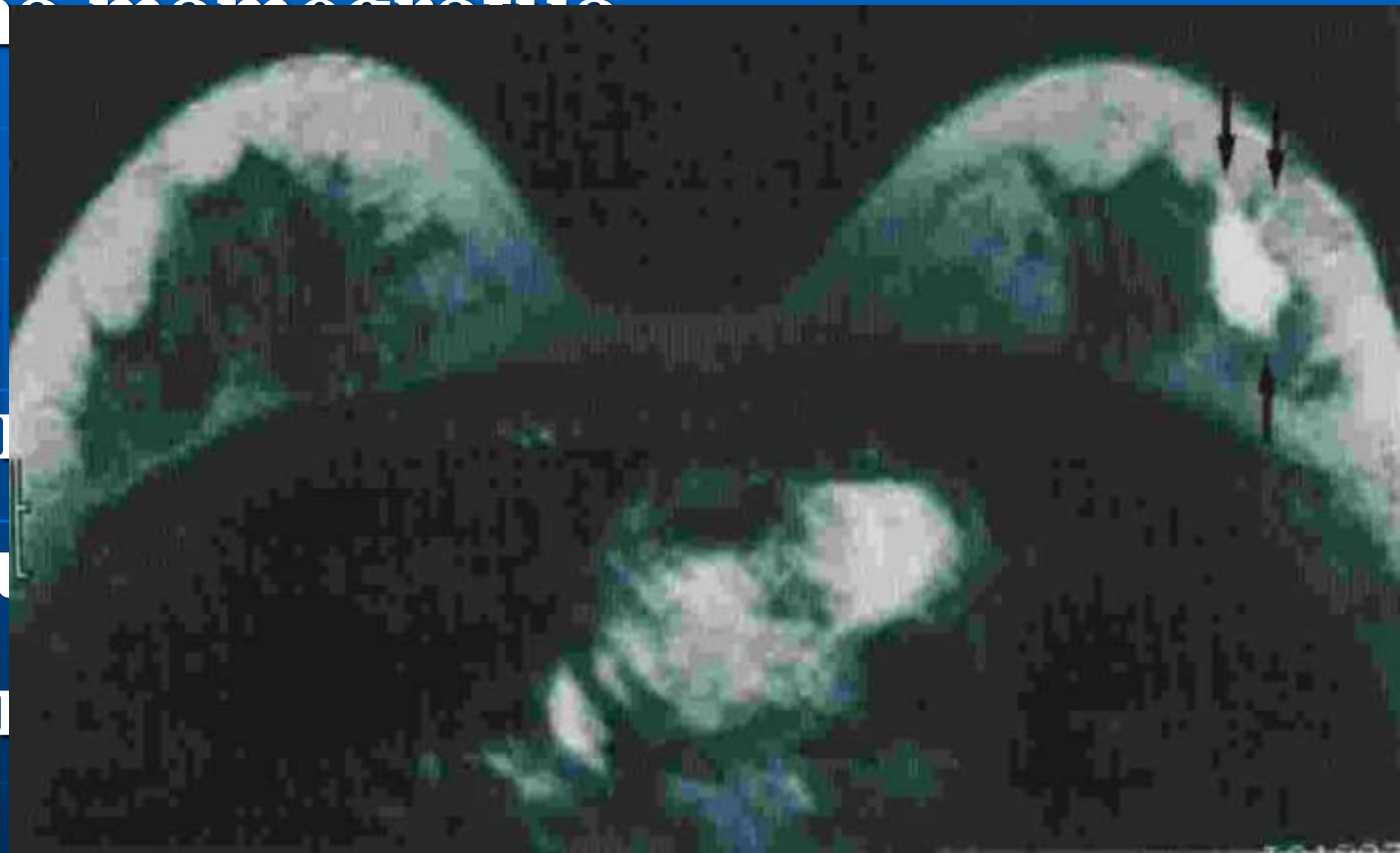# Novi dijagnostički proceduri

- radioizotopski isleduvawa,
- endoskopija na duktusi,
- "core" biopsija,
- stereotaksi~ka biopsija

ne se prepore~livi za standardna  
upotreba.

# Novi dijagnostički proceduri

- digitalna mammografija
- CT
- **NMRI**
- termografija
- dopler ultrazvuk
- pozitronna tomografija



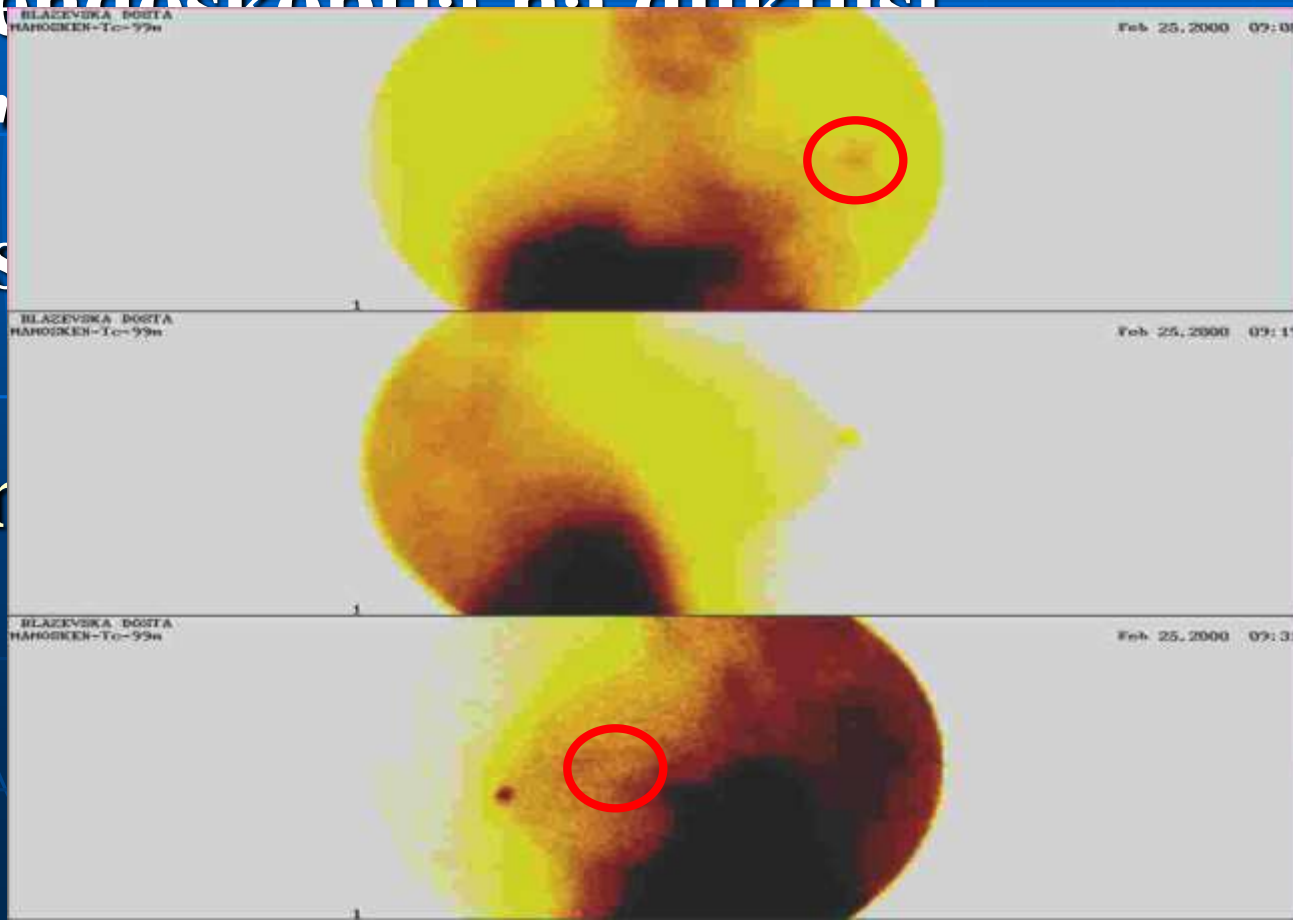
# Novi dijagnostički proceduri

- **radioizotopski isleduvawa,**

- **endoskopija na duktusi**

- **W**

- **S**

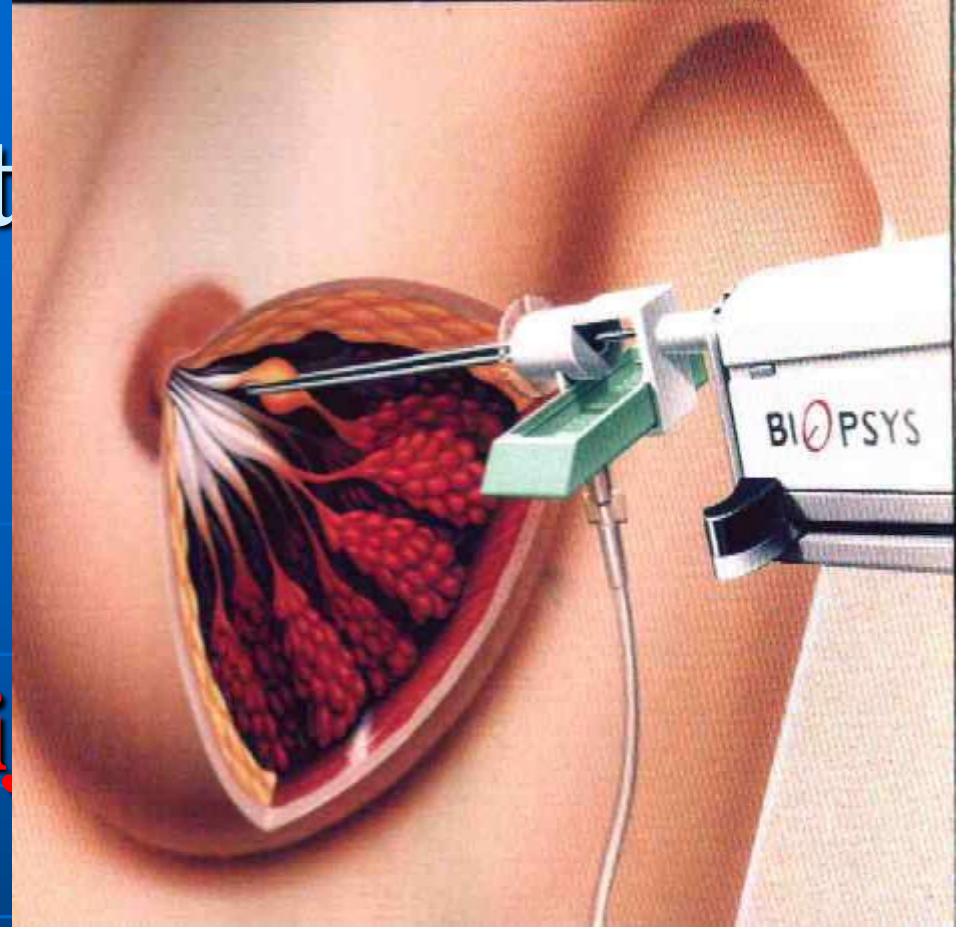


lardna

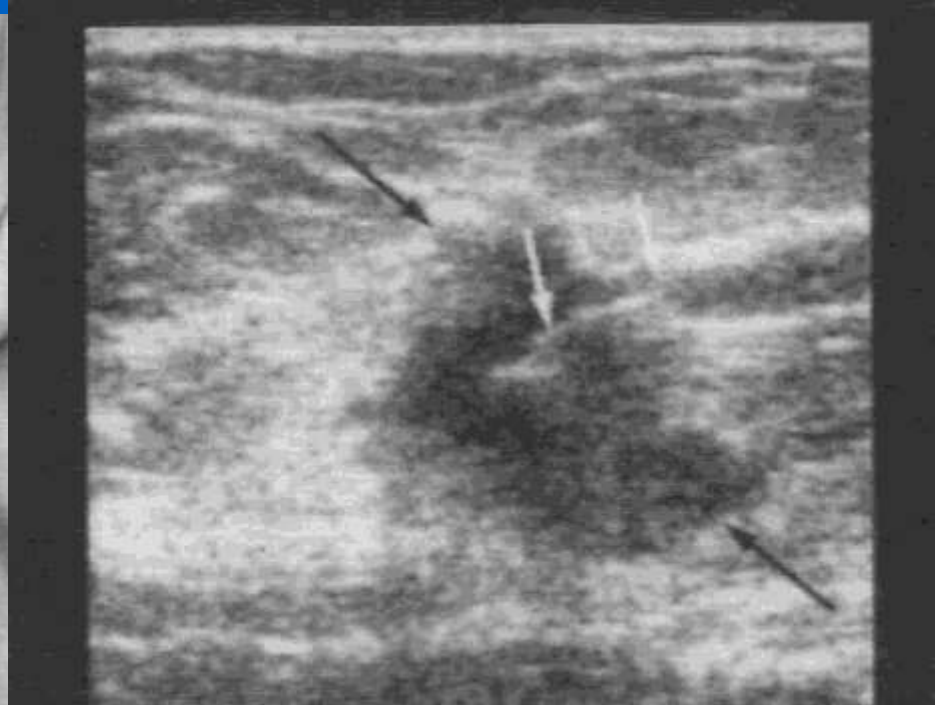
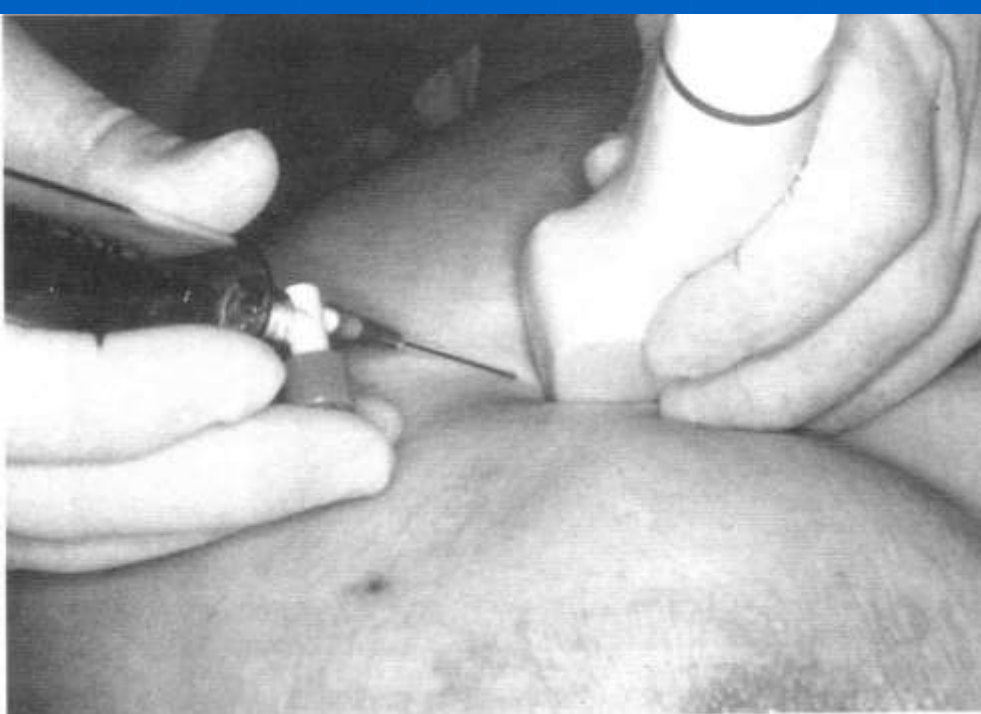


# Novi dijagnostički

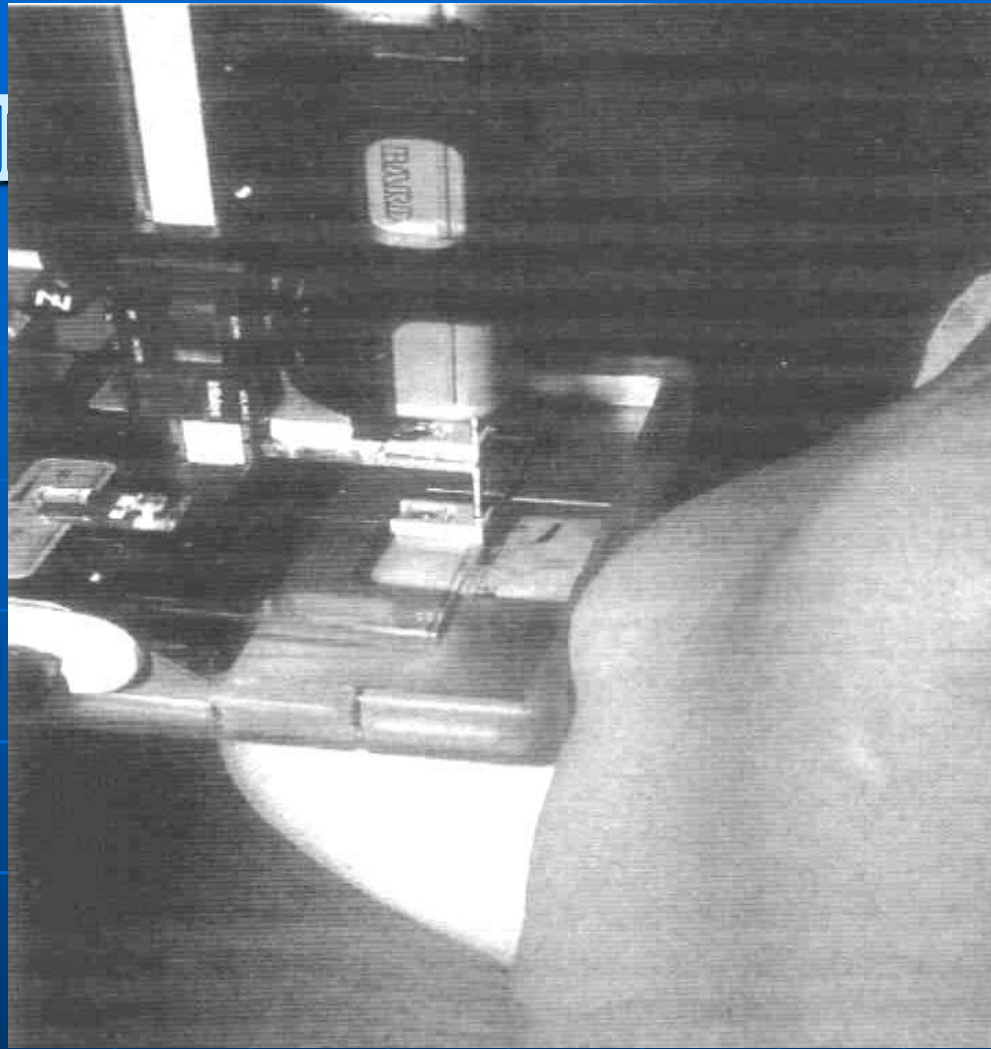- radioizotopski endoskopija na
- **"core"** biopsija
- stereotaksi~ka biopsija



# Novi dijagnostički proceduri



- **biopsija pod kontrola na ultrazvuk**



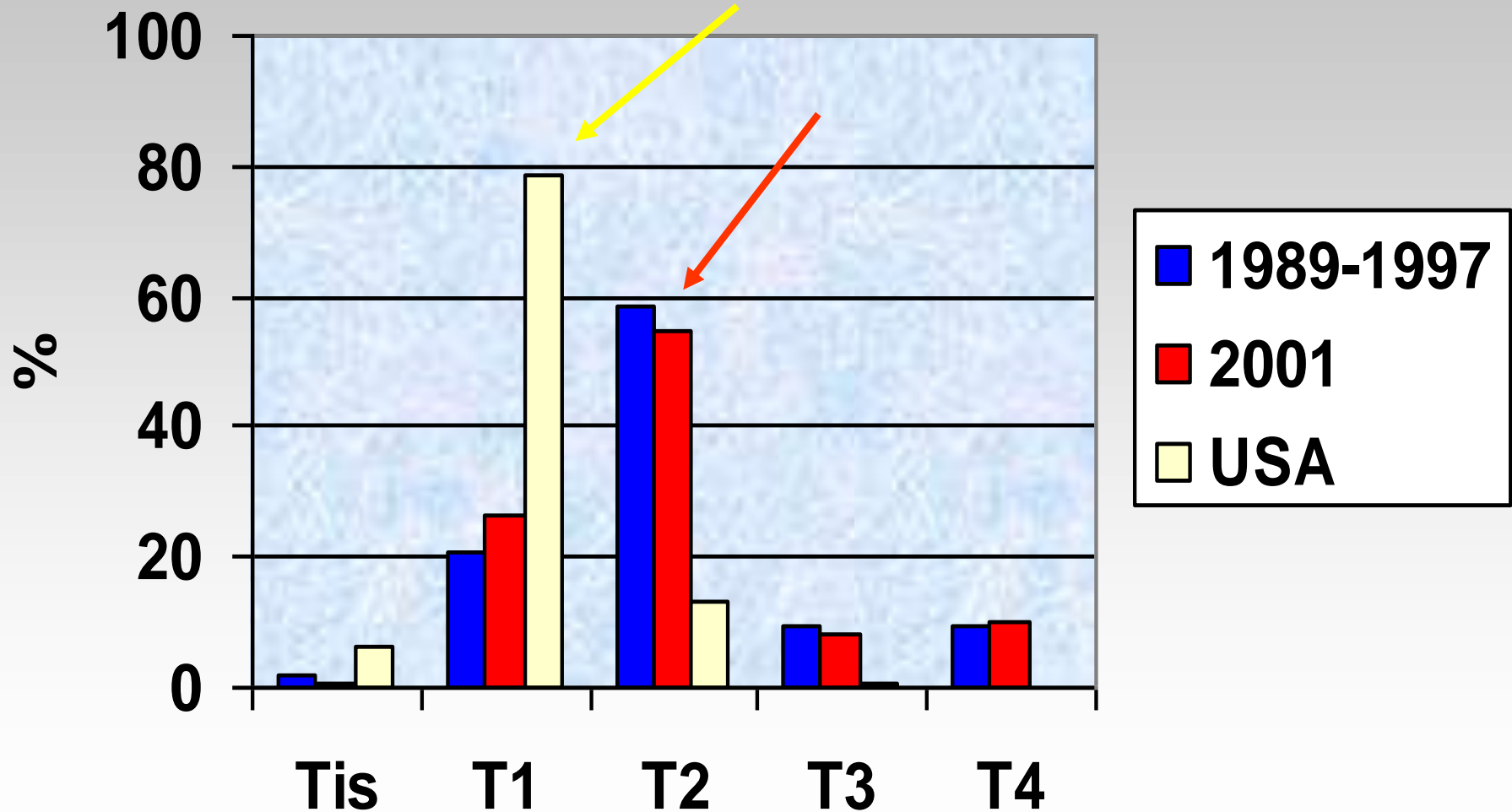
i proceduri

duvawa,  
tusi,

- stereotaksi~ka biopsija

Senzitivnost %	Tehnika	Specifičnost %
	<b>Nepalpabilen tumor</b>	
73-97	S-FNA	91-100
94-97	US-FNA	98-100
71-100	S-CNB	99-100
100	US-CNB	100
	<b>Palpabilen tumor</b>	
77-99	FNA	99-100

# Gol emi na na tumor



- Za **palpabilnite lezii finata tenkoiglena biopsija** e mnogu poefektivna, poeftina i realno primenliva metoda.
- Za **nepalpabilnite lezii** prva linija na izbor e **fina tenkoiglena biopsija vodena pod ehosonografija**.
- **Stereotaksi~koto vodewe mamografski** e potrebno pri postoeve na **kalcifikati i lezii** koi ne se vizualiziraat pod eho.

# Novi dijagnostički proceduri

Detekcija na genski mutaciji  
(**BRCA 1, BRCA 2 . . . .**)

# 4

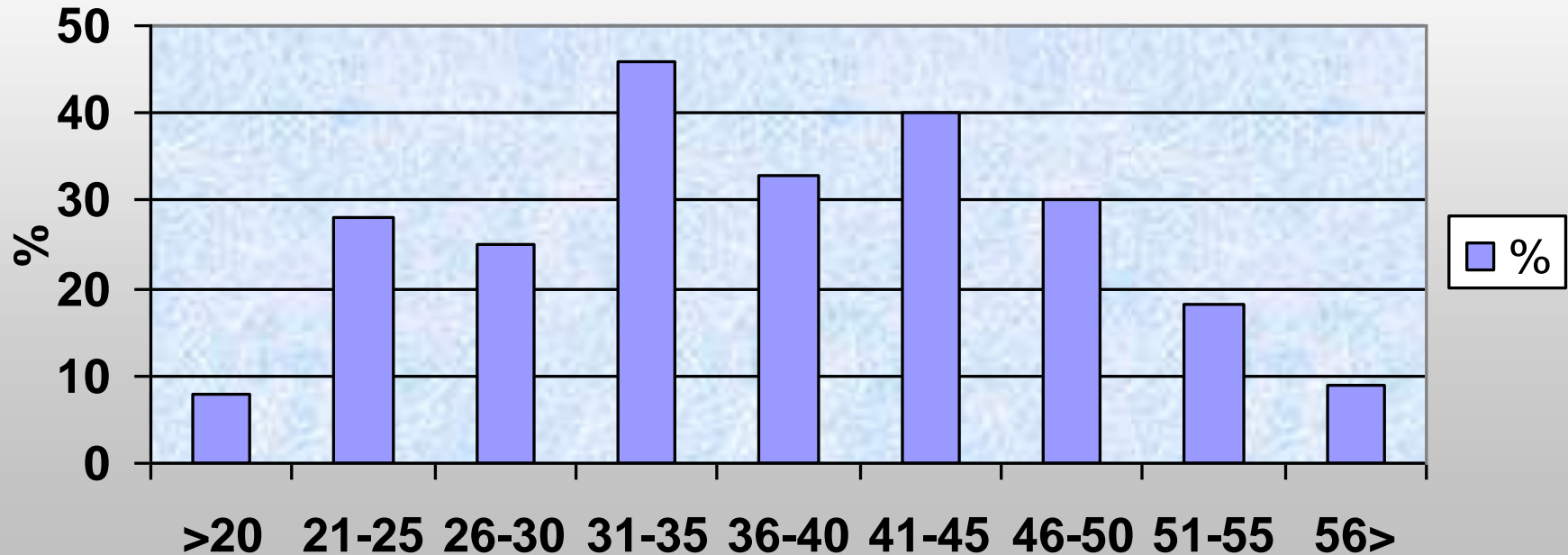
## SIMPTOMI NA ZABOLUVAVATA NA DOJKATA

- **Bolka**
- **Iscedok**
- **Promeni na bradavica**
- **Tvrđina (dojka, pazuvna jama)**
- **Promeni na ko`a**

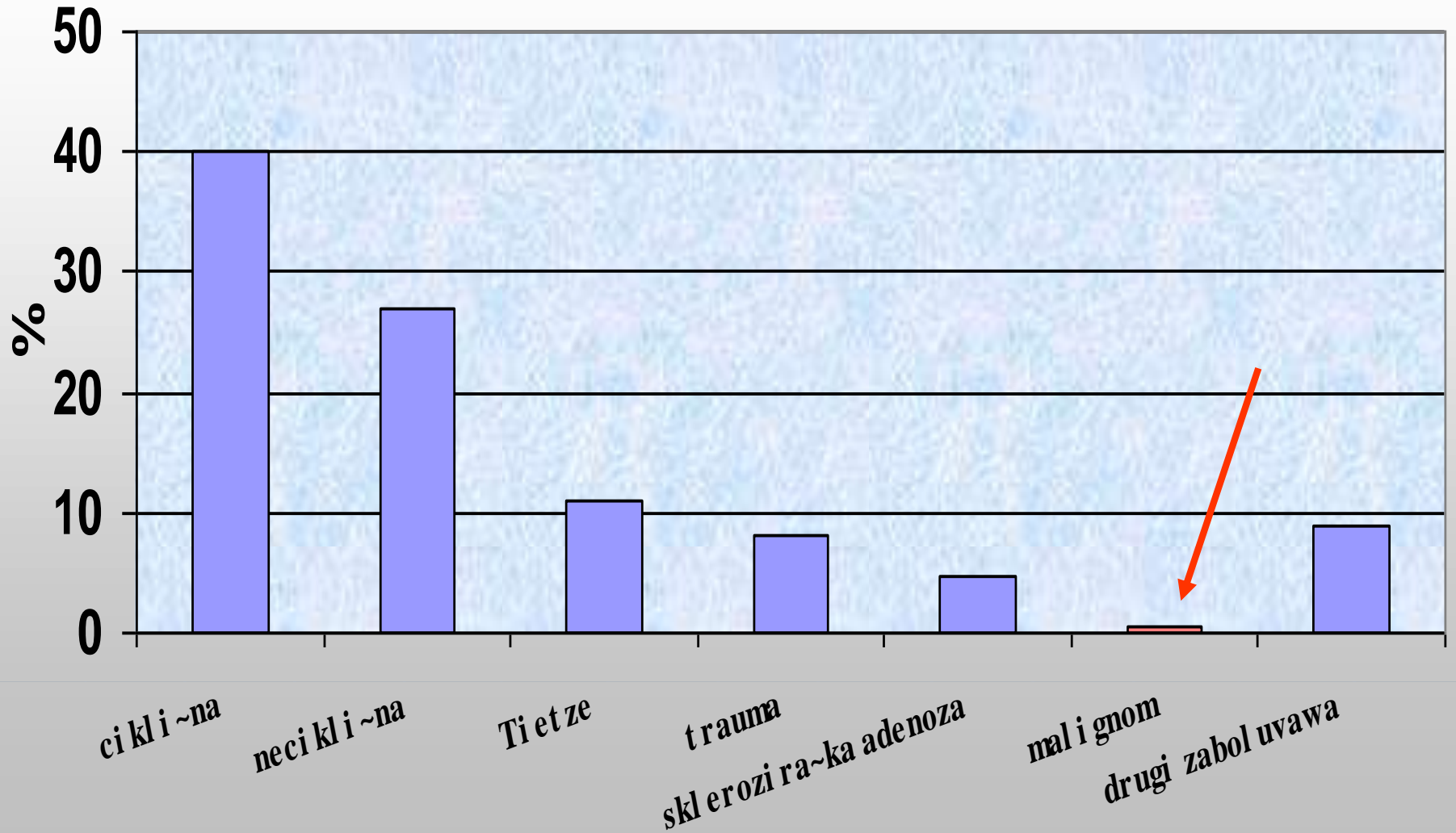


# Bolka

**PROCENTNA @ENI KOI I MAAT  
BOLKA VO RAZLI ^NI VOZRASI**



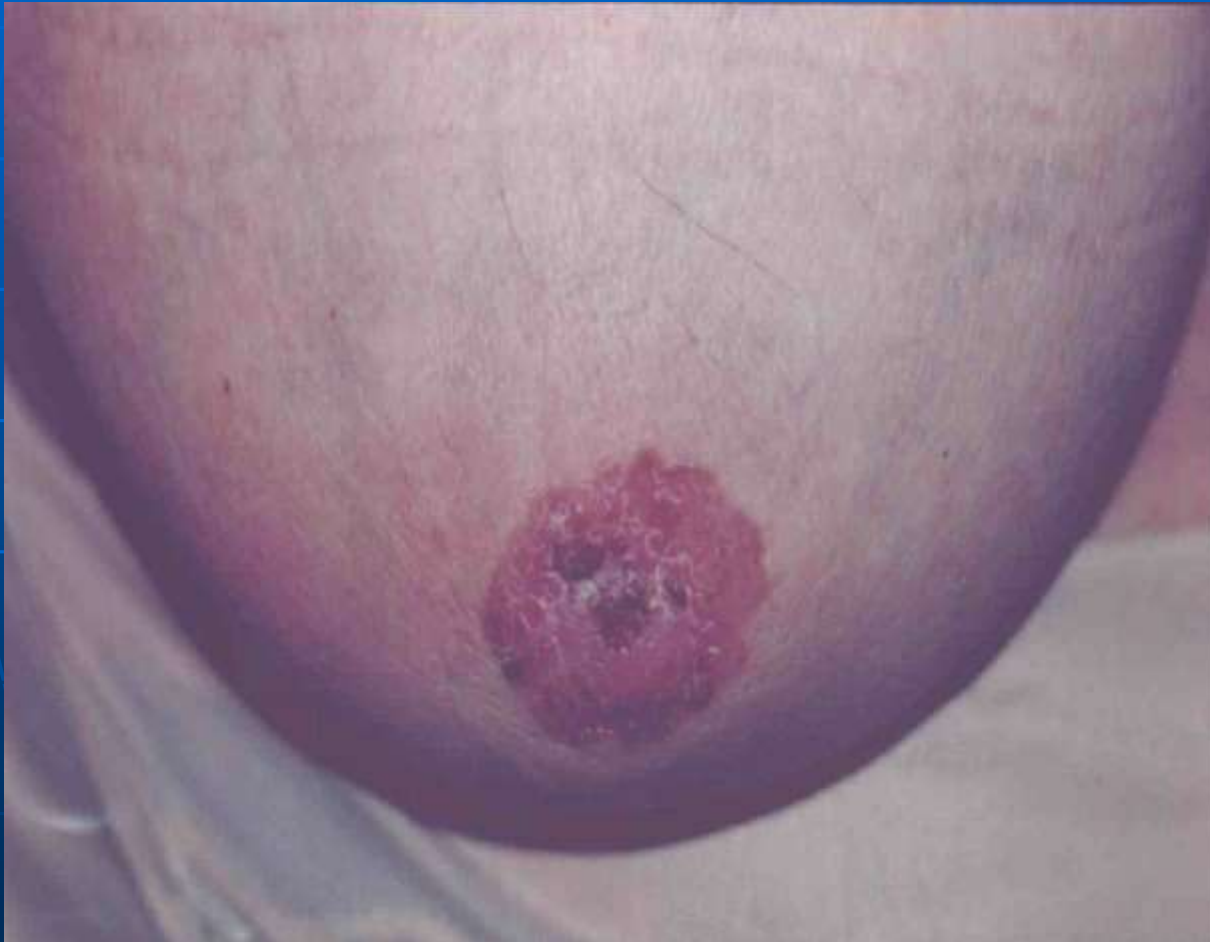# Priloznosti za bolka v dojki



# Iscedok

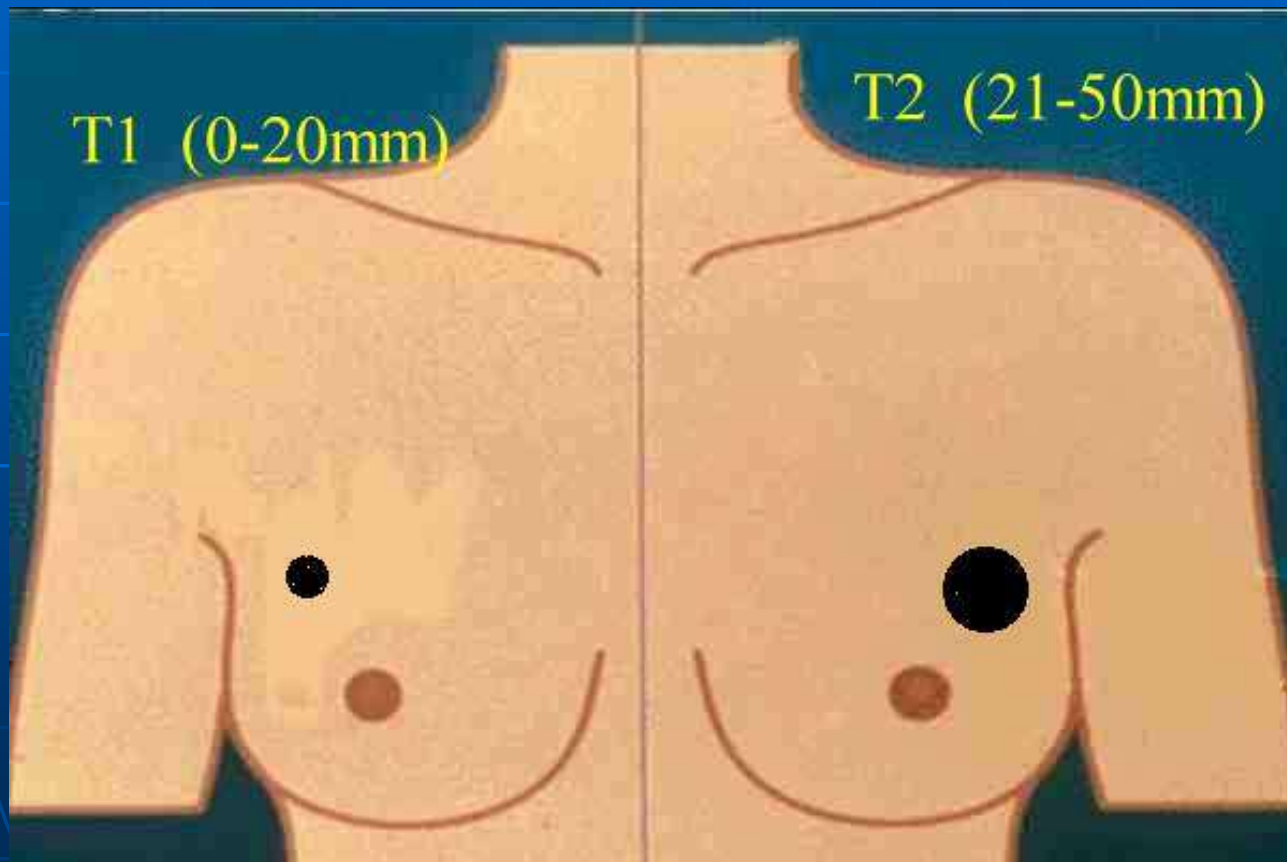
- proziren (serozen)
- zakrvaven (serohemoragi~en)
- mle~en
- sivozelen
- **krvav**

# Promeni na bradavica



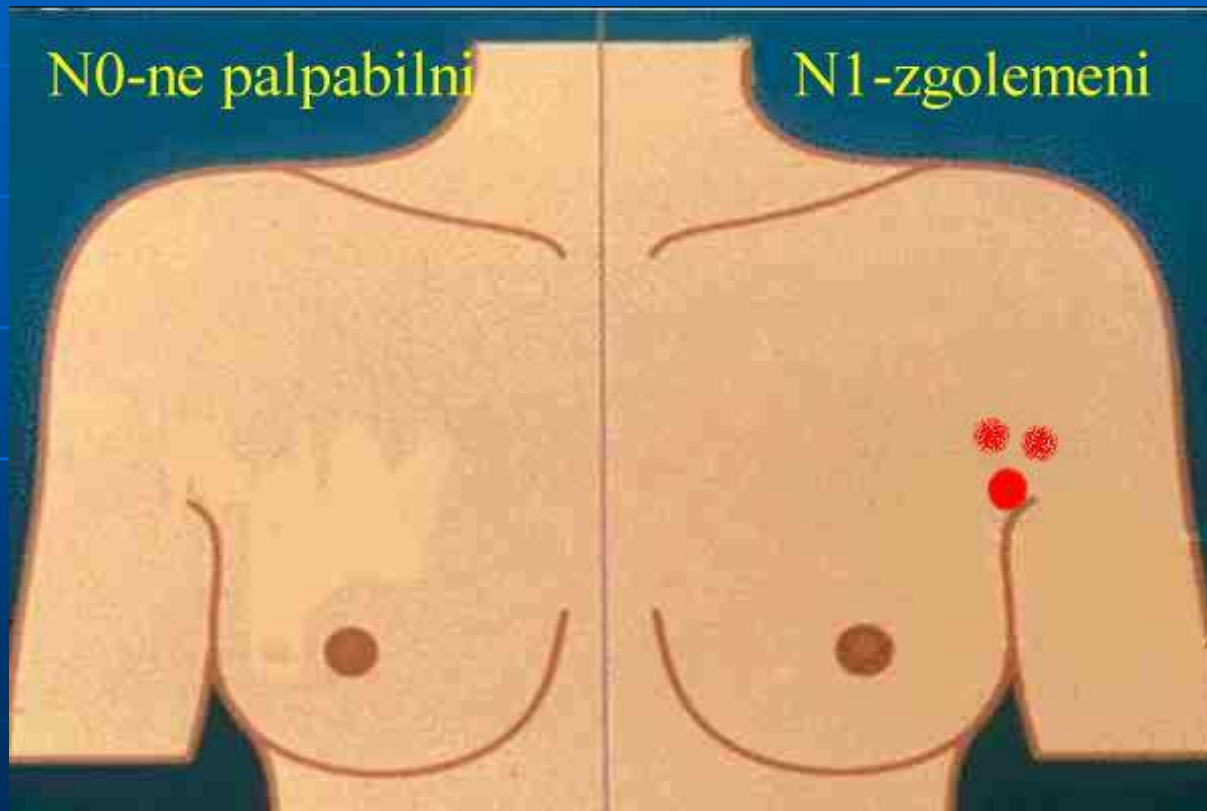
# Tvrđina (tumor)

~vor, zadebeluvawe



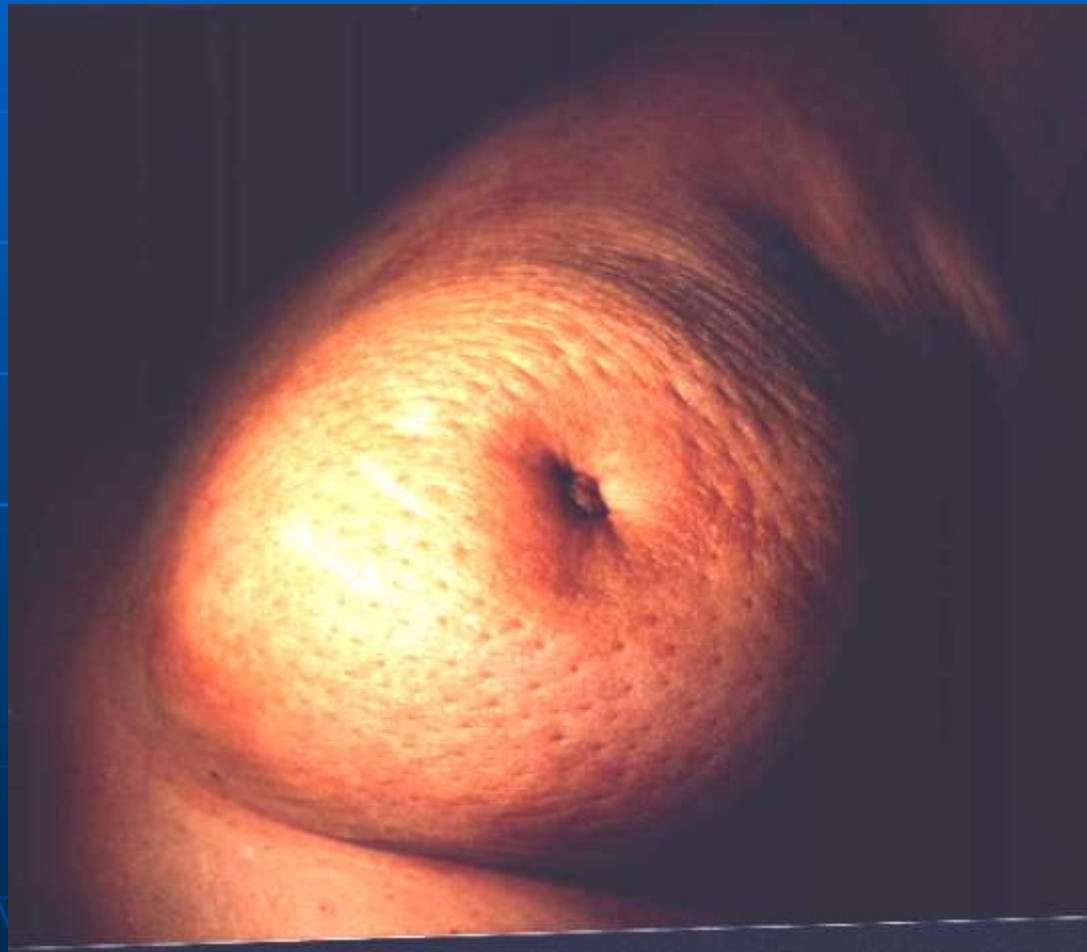vo dojka

# Tvrđina (tumor)

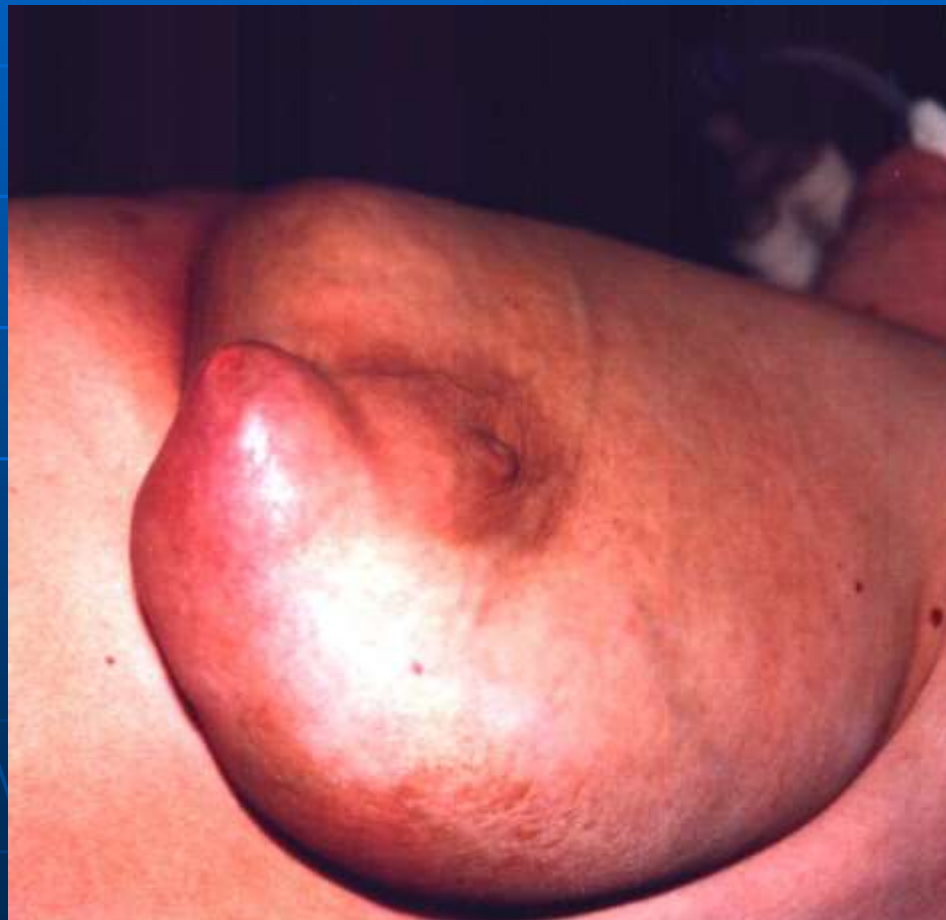

vo pazuvna jama

# Promeni na ko`a



# Promeni na ko`a





# **5. Patološki promeni na dojkata**

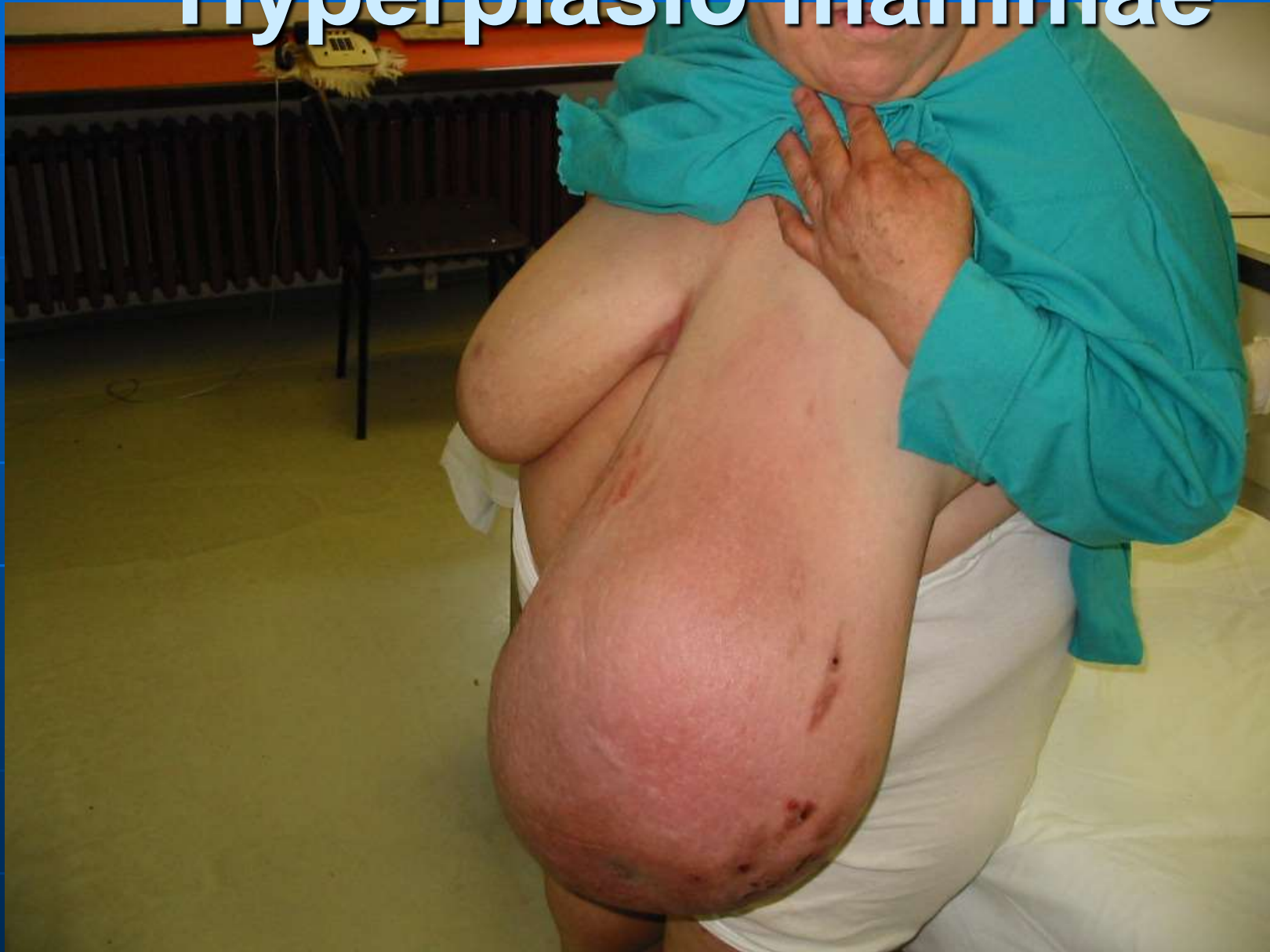- **Poremetuvawa na razvojot**
- **Povredi na dojkata**
- **Postoewe na tumor**

# Patološki promeni na dojkata

## ■ Poremetuvawa na razvojot

- Povr potpoln nedostatok na del ili cela dojka (amastija, athelia, hypomastija), prisastvo na
- Post pogolem broj (polimastia), nesimetri~en razvoj, inverzija na mamila

# Hyperplasio mammae



vleguvaat povredi nastanati od dejstvo na mehani~ka sila, dejstvo na hemikalii, elektricitet ili dejstvo na oru`je. Se manifestiraat so postoewe na rana, otok, krvarewe (hematom).

- **Povredi na dojkata**

- **Postoewe na tumor**

• **vospalitelno poteklo** (specifi~no i nespecifi~no).

• **hormonsko poteklo** (displasio fibrocistica).

• **prav tumor** [benigni i maligni

■ **Postoewe na tumor**



# 1. Absces na dojkata

- **lokalna infekcija vo dojkata naj~esto predizvikana od patogeni bakterii**
- **vo tek na doewe**
- **se manifestira so: otok, bol, crvenilo, fluktuacija i febrilnost.**
- **se dijagnsoticira so punkcija.**

# Absces na dojkata

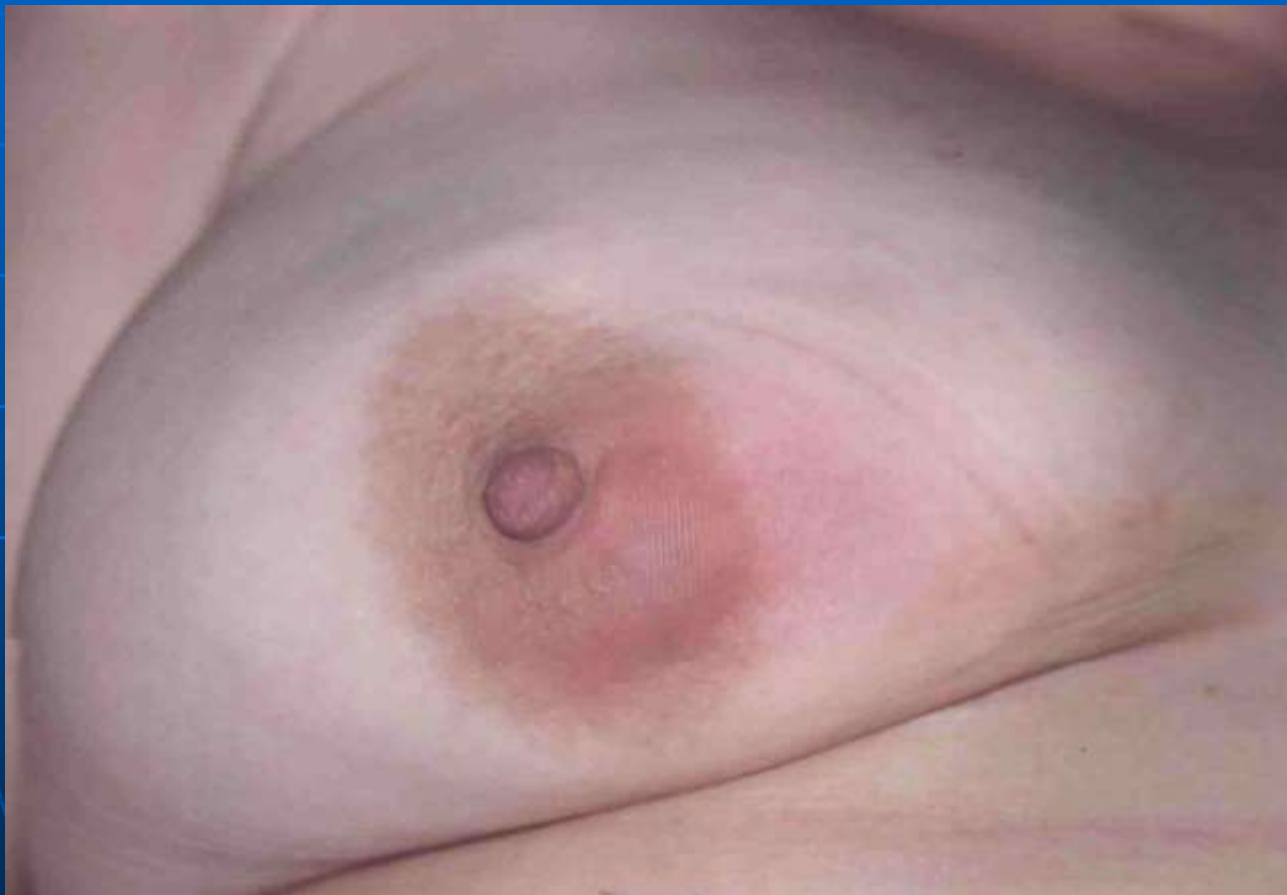- **Na po~etok –mastitis acc** po pojava na bolna topla tvrdina.

Terapija- antibiotska terapija, izmolzuvawe i lokalna aplikacija na oblozi.

- **Po kolikvacija** na inflamatarriot tumor, so sozdavawe gnojna {uplina ispolneta so gnoj, se pojavuva fluktuacija.

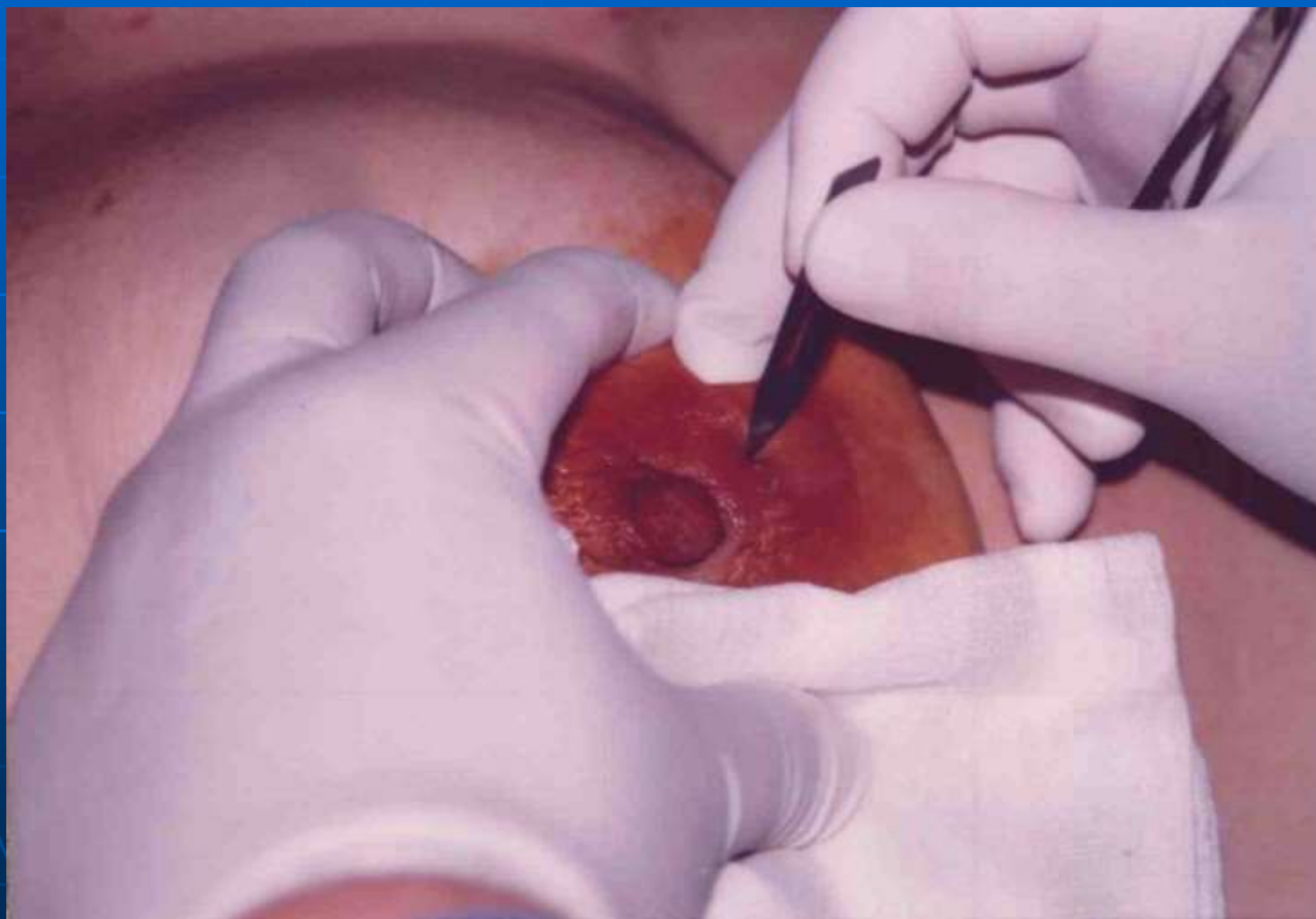
Tretmanot e so hirur{ka incizija, drena`a i sistemska primena na antibiotik.

# Incizija na absces na dojka

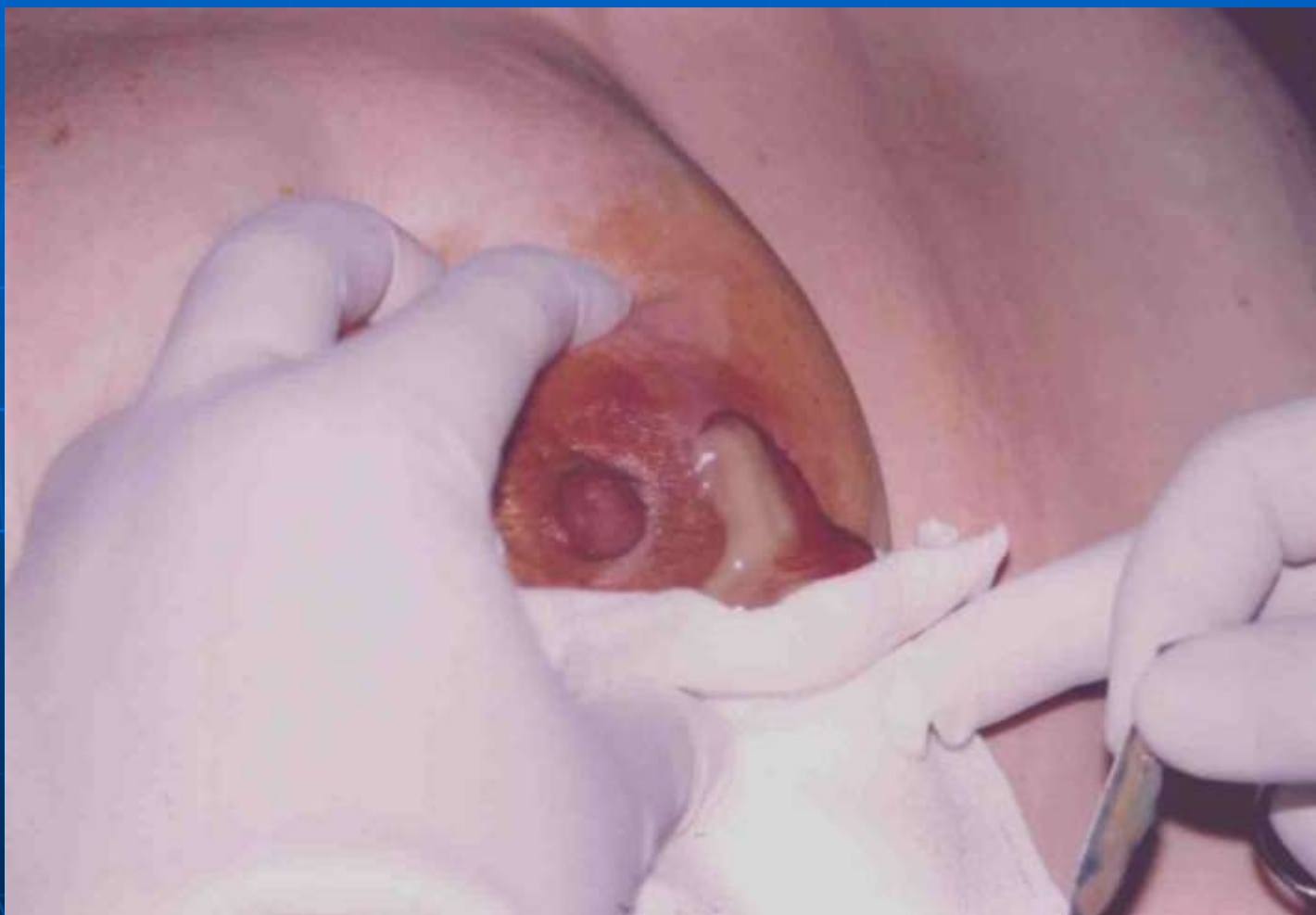



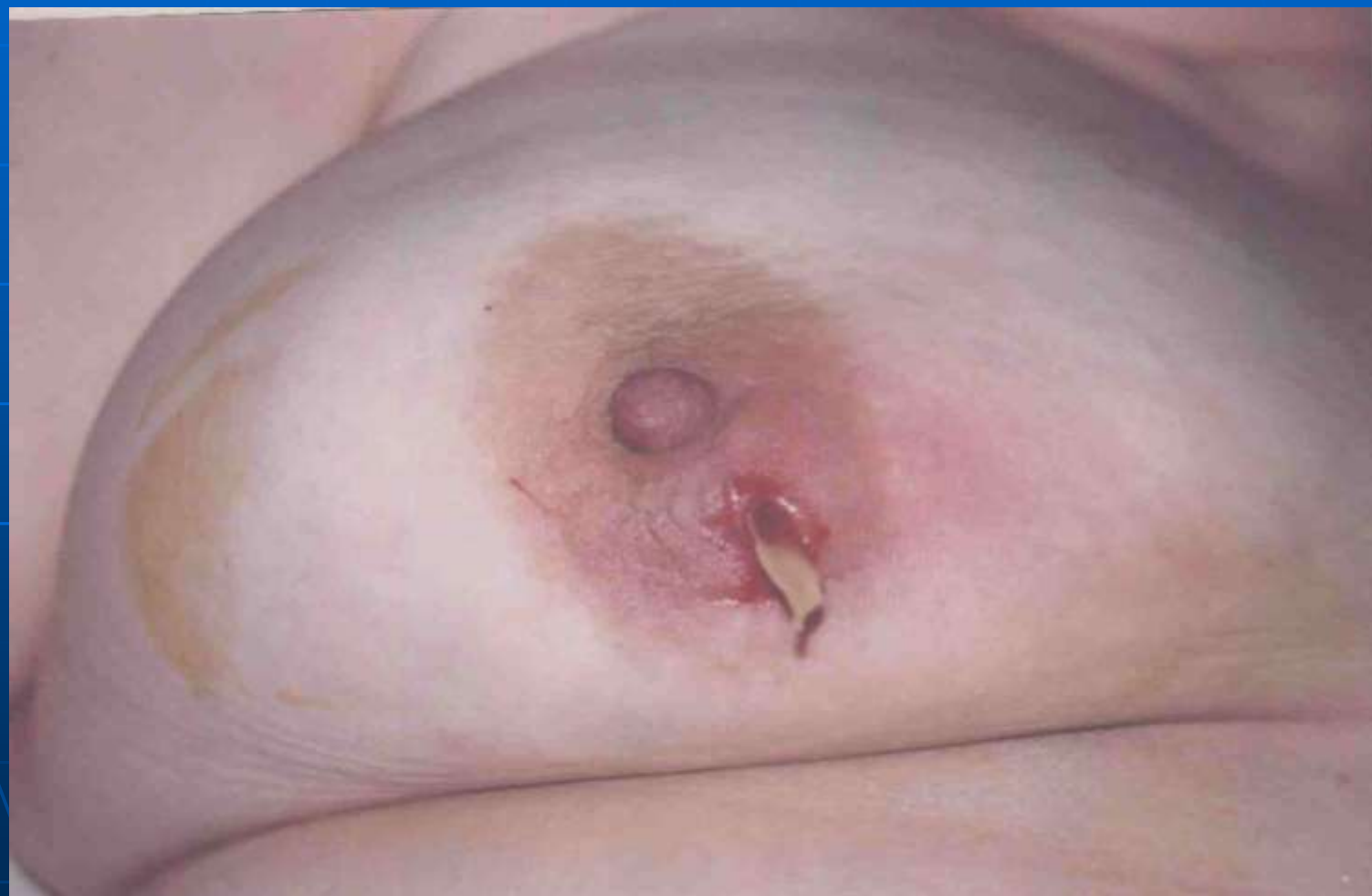# Incizija na absces na dojka



# Incizija na absces na dojka



# Incizija na absces na dojka



## **2. Fibrocisti~na displazija- (mastitis chronica cystica, dysplasio fibrocistica**

- **naj~esta patolo{ka sestojba**
- **naj~esto se manifestira na voзраст od 30 do 60 godini, povrzuvaj}i se so desjtvoto na hormoni, osobeno estrogeni.**
- **promena na dojkite se javuva premenstrualno**
- **ekstenzivnosta na promenite se namaluva po dobivawe na menstruacijata.**

# Fibrocisti~na displazija

prisastvo na premenstrualno nabreknuvawe na dojkite, zgolemuvawe na volumenot na dojkite, pojava na brojni difuzni ili lokalizirani ~vorovi, bolna osetlivost na promenite, ponekoga{ ose}aj da nadoa|a mleko i dr.

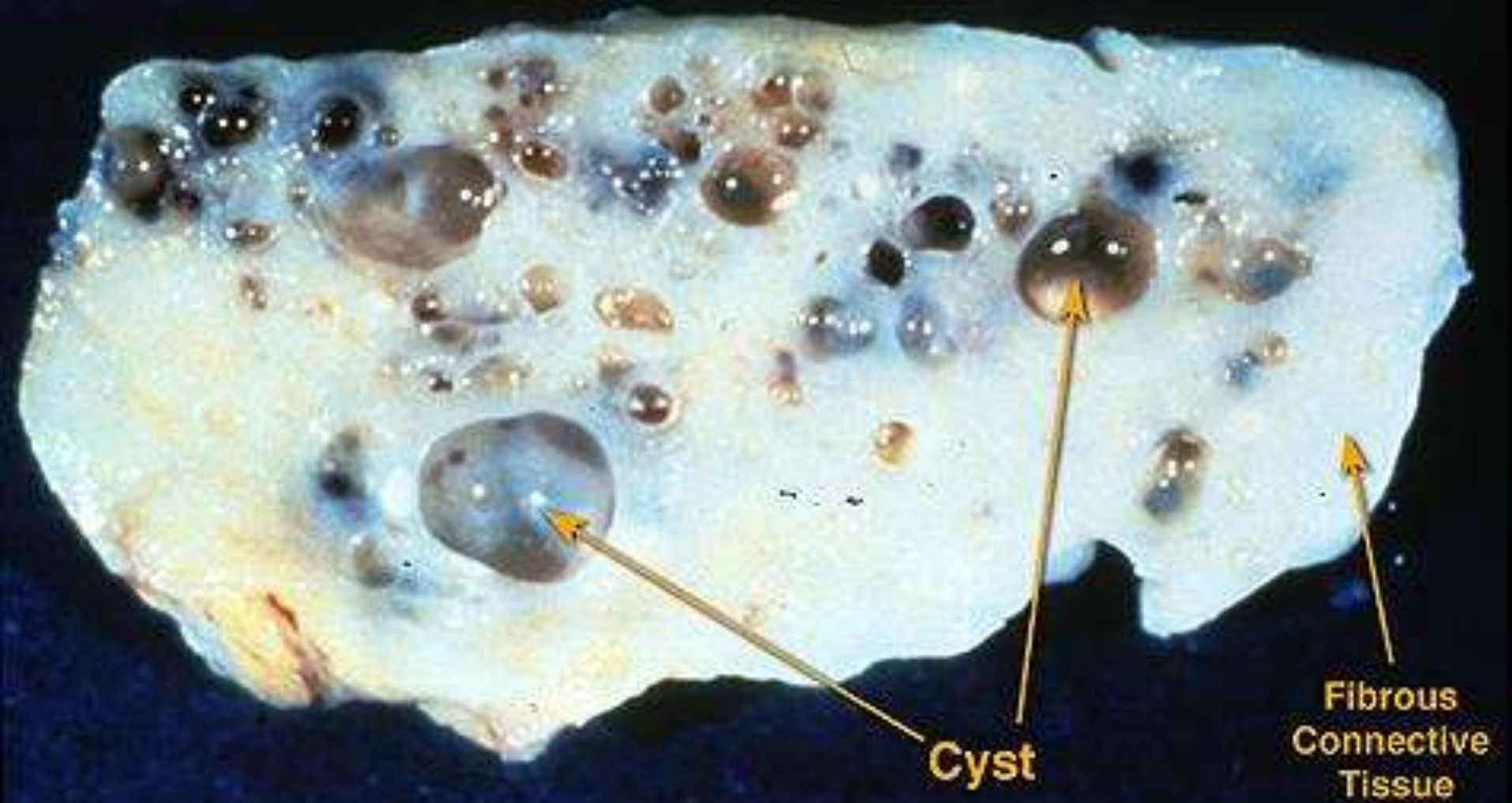
# Fibrocisti~na displazija

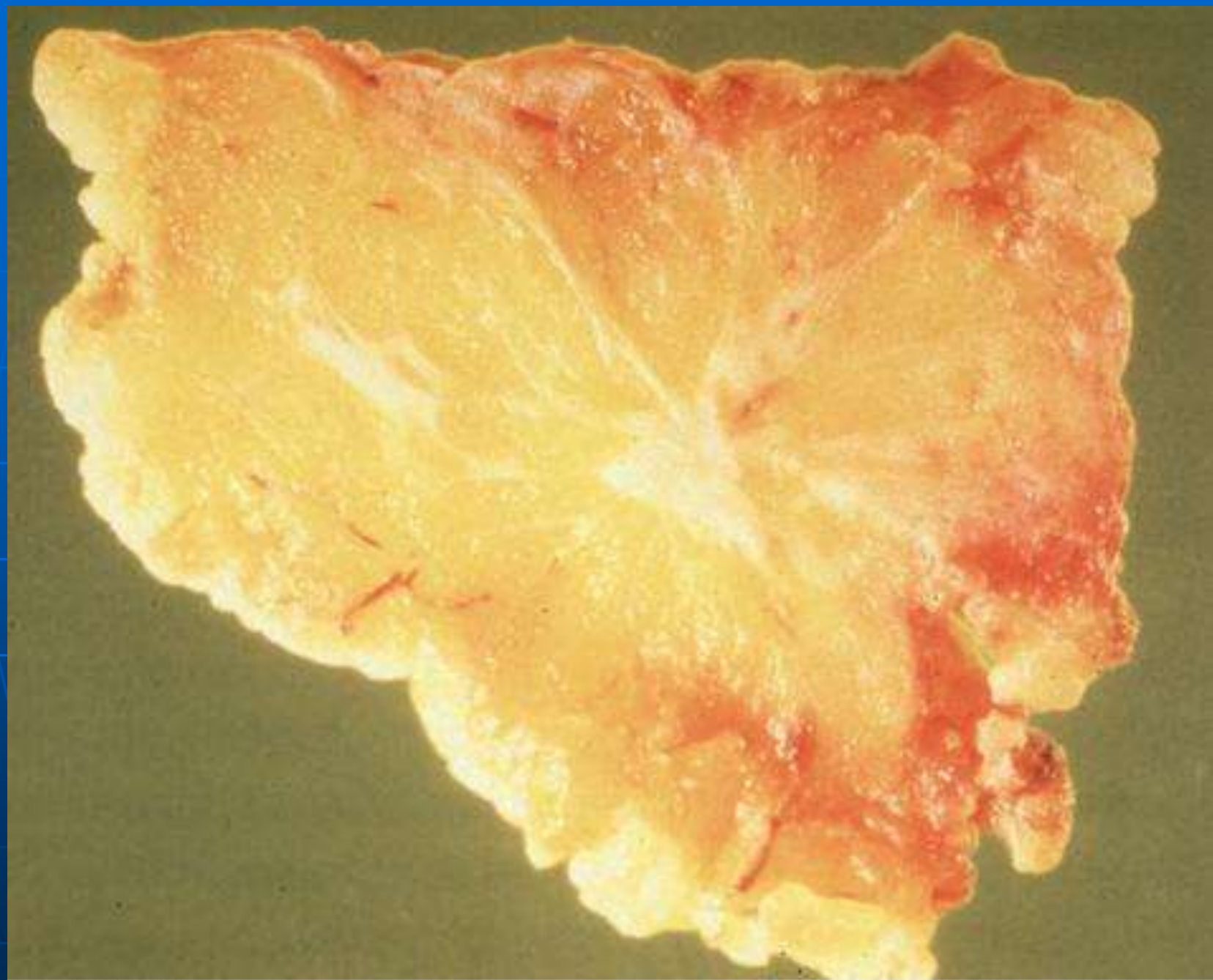Patolo{kite sestojbi se dol`at na dominacija ili kombinacija na edna od slednive fazi: faza na **hiperplazija**, faza na **sekrecija** i faza na **sklerozacija**.

Se manifestira so brojni ~**vorovi od mikrocisti, makrocisti, so fibrozna komponenta vo okolinata.**

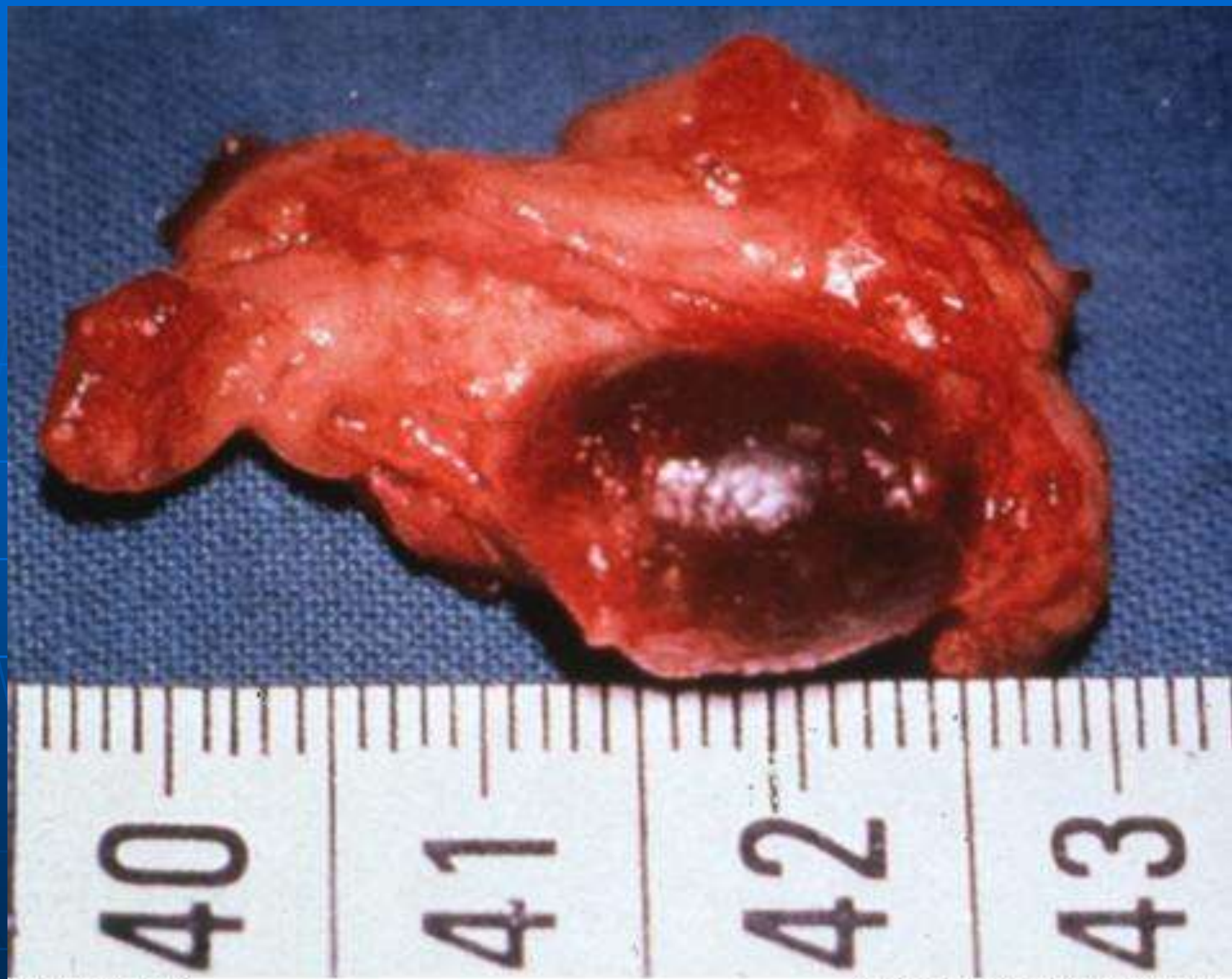Promenite se `ari{ni.

# Fibrocystic Mass

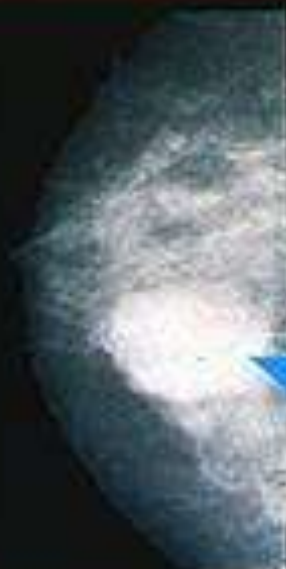






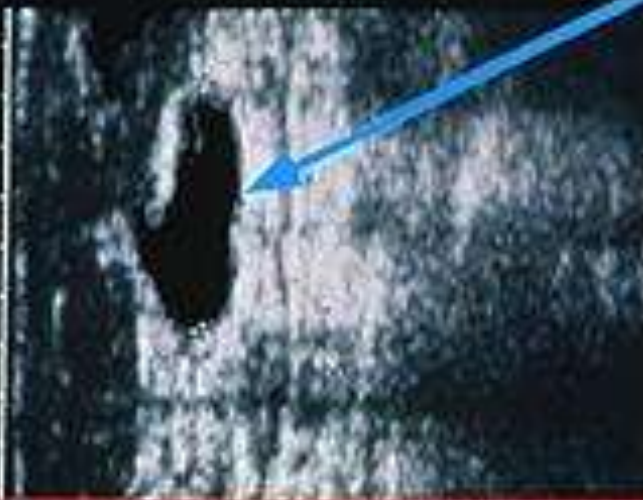
*Mammogram*



**Cyst**

*Ultrasound*



**AMERICAN  
CANCER  
SOCIETY**

Florida Division, Inc.

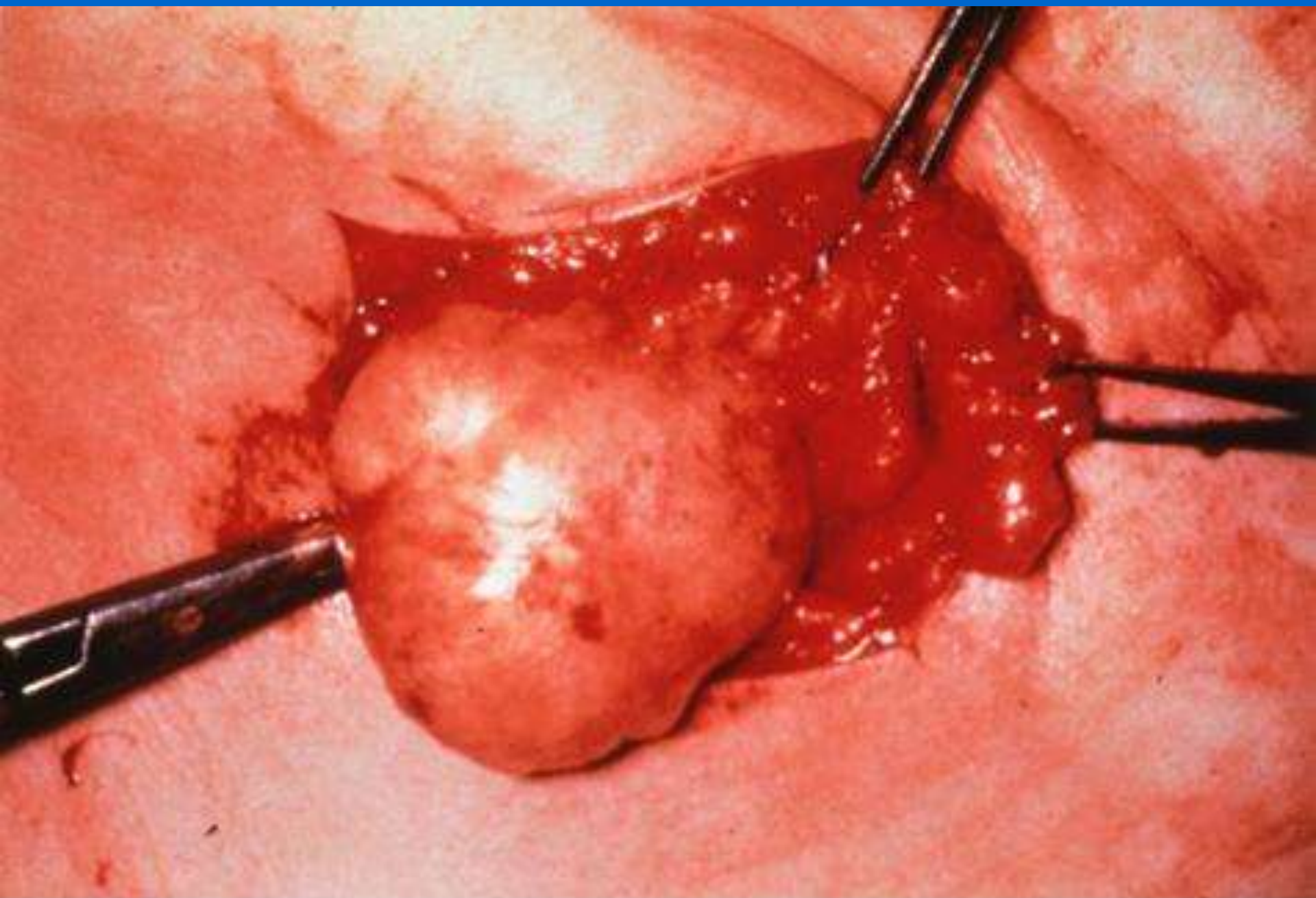
# Fibrocisti~na displazija

## Terapijata:

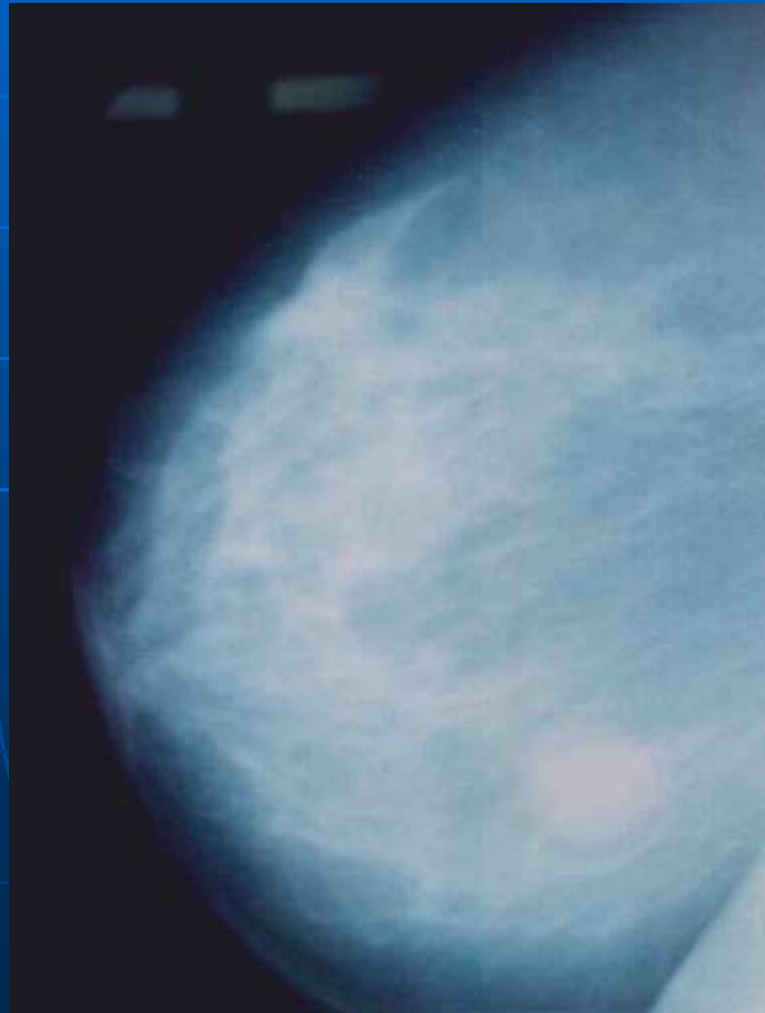
simptomatska (oblozi i analgetika),  
vitamin E, Danazol (sintetski androgen  
hormon) ili lokalna aplikacija na  
Progestogel

# 3. Fibroadenom

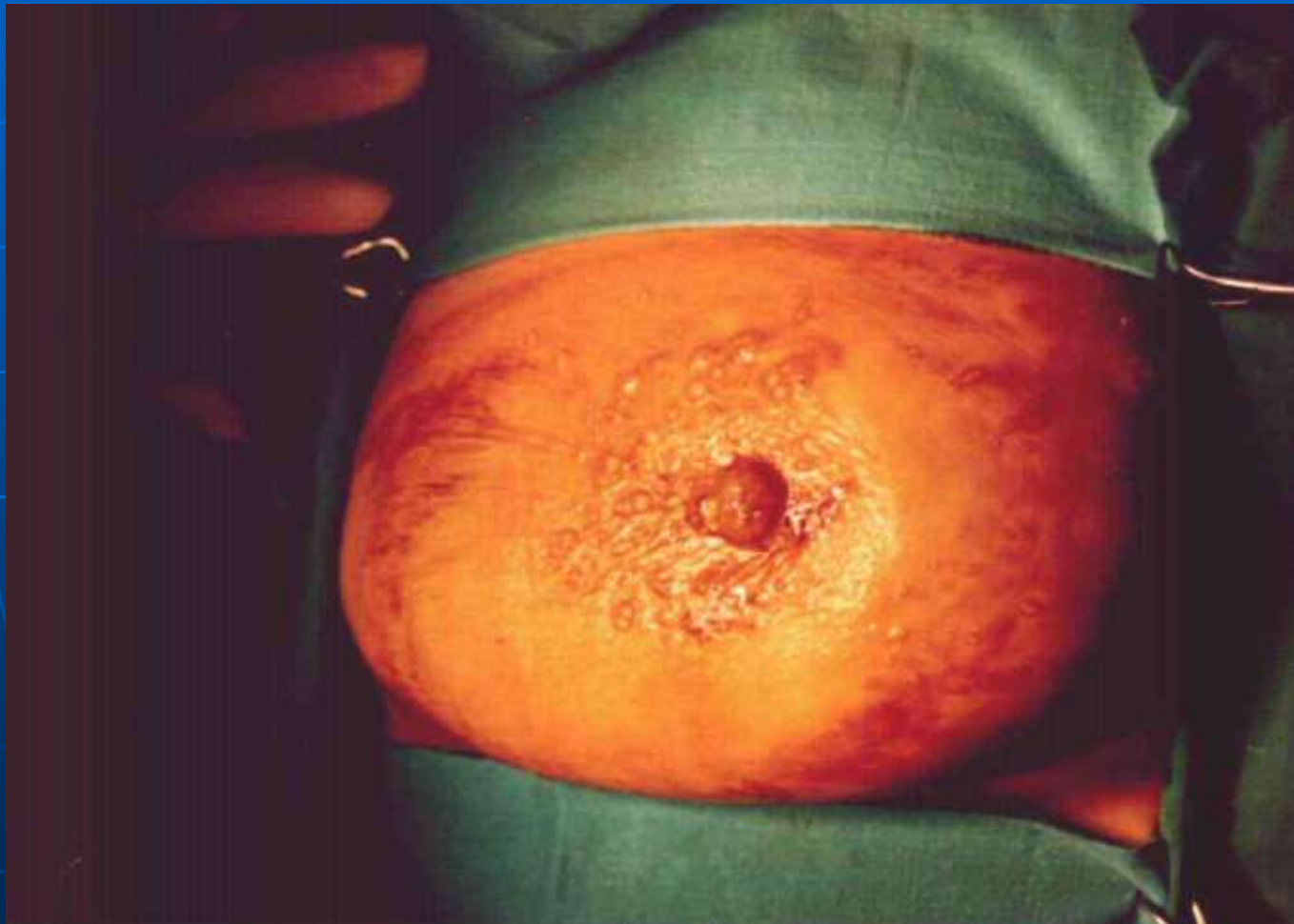
- naj~est benigni tumor
- poedine~na ili multipla pojava na lobuliran dobro ograni~en, ~vrst tumefakt, slobodno pokreten od okolinata, so promer od 1 do 5 cm.
- terapijata - hirur{ka ekcizija.



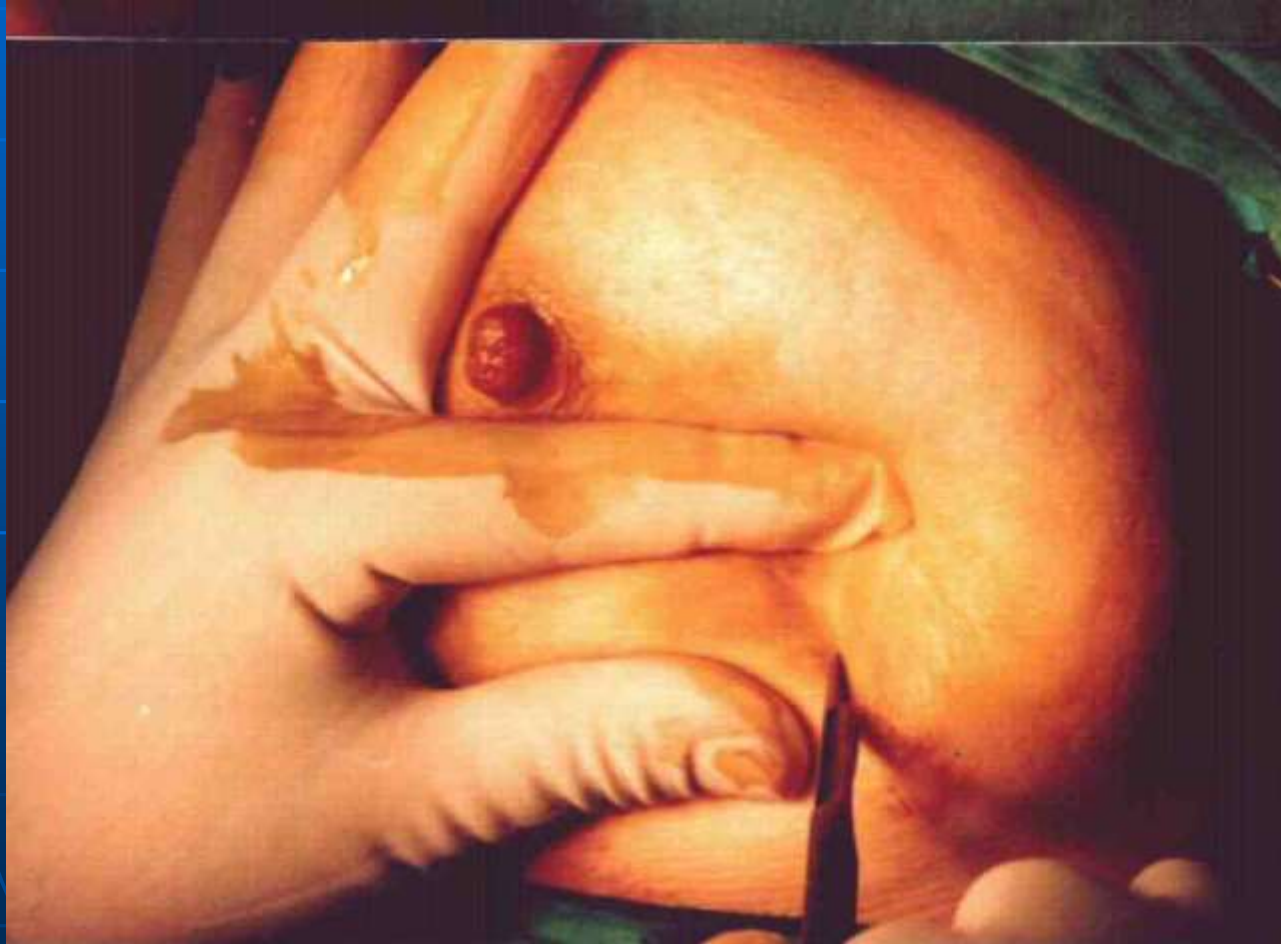
# Ekstirpacija na tumor tumorectomia



# Ekstirpacija na tumor tumorectomia

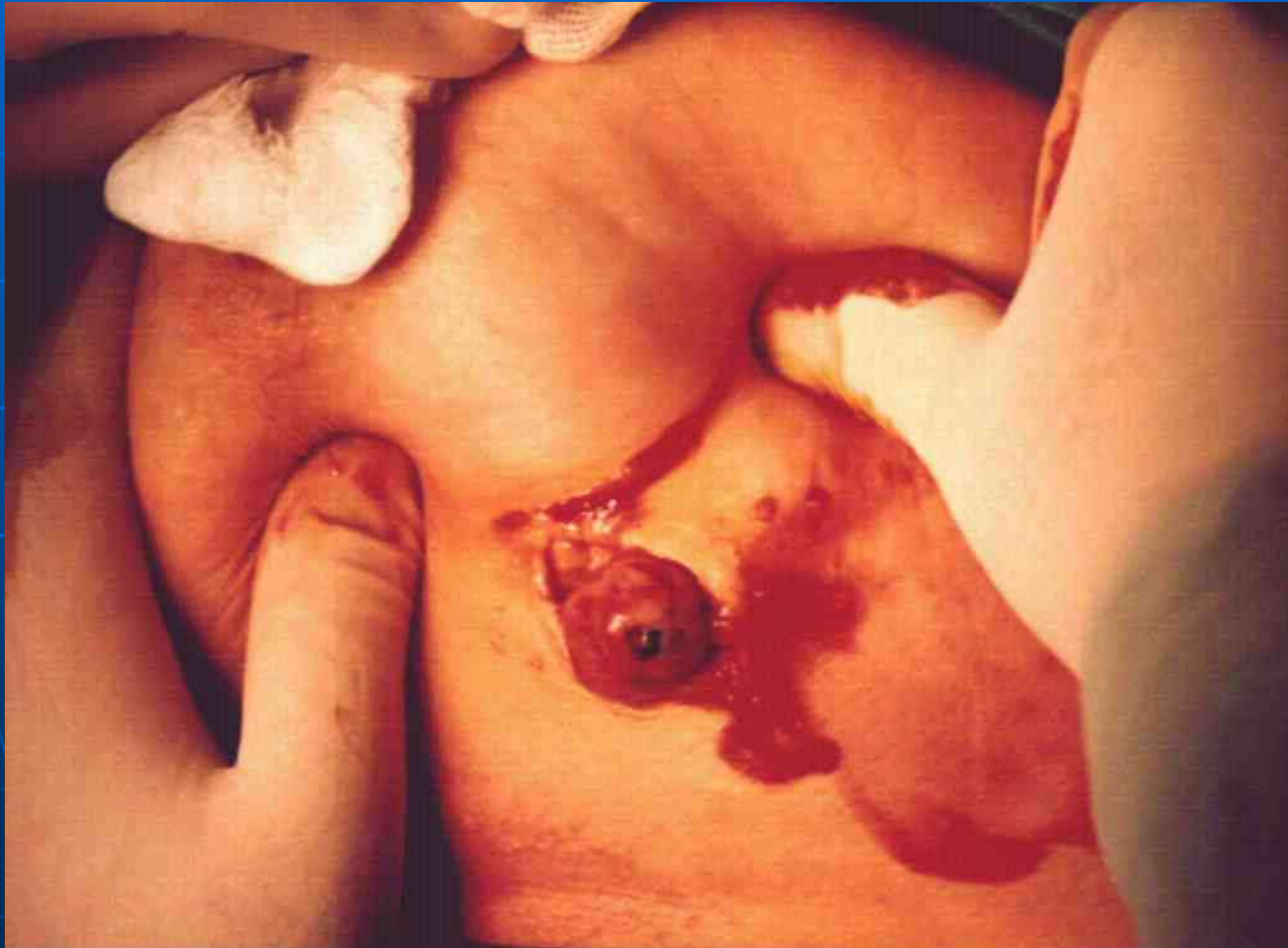

# Ekstirpacija na tumor tumorectomia

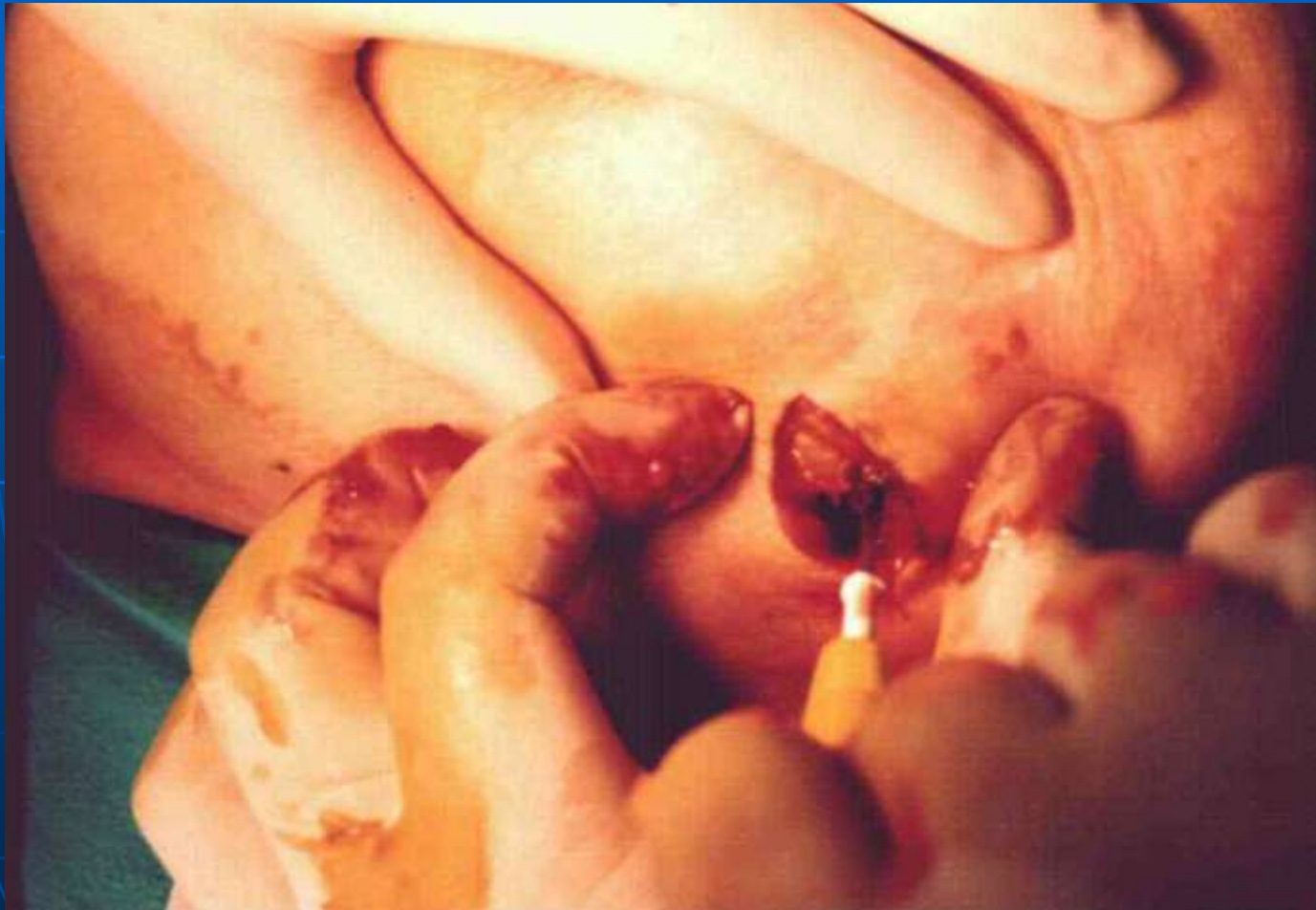



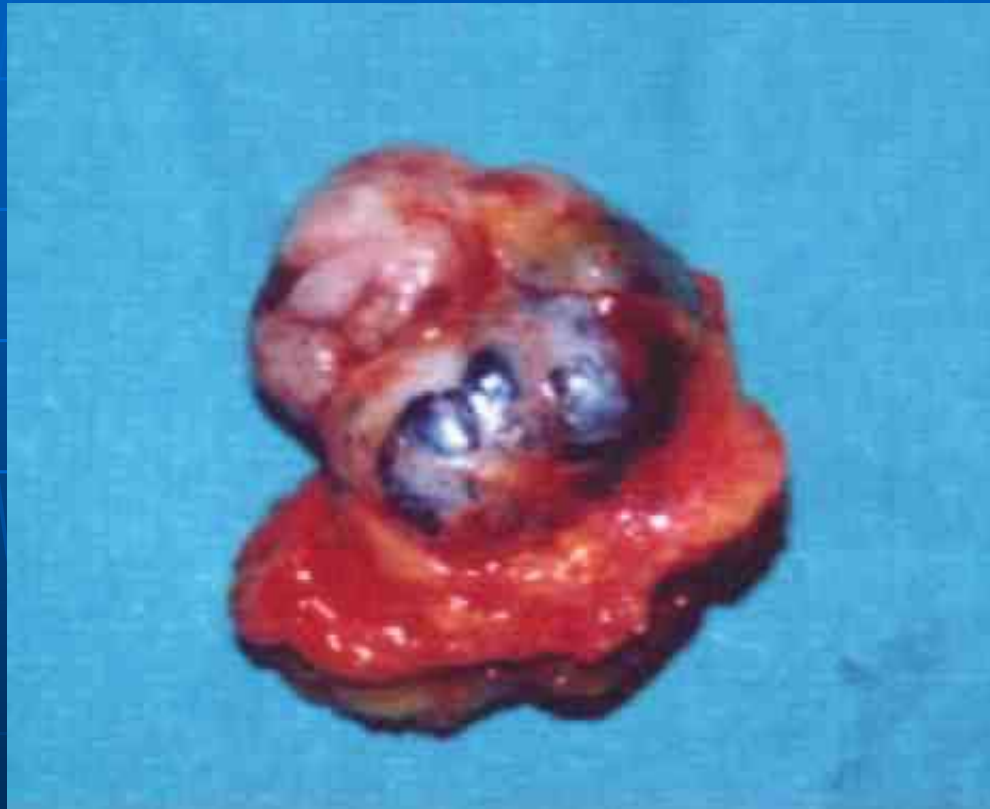
# Ekstirpacija na tumor tumorectomia



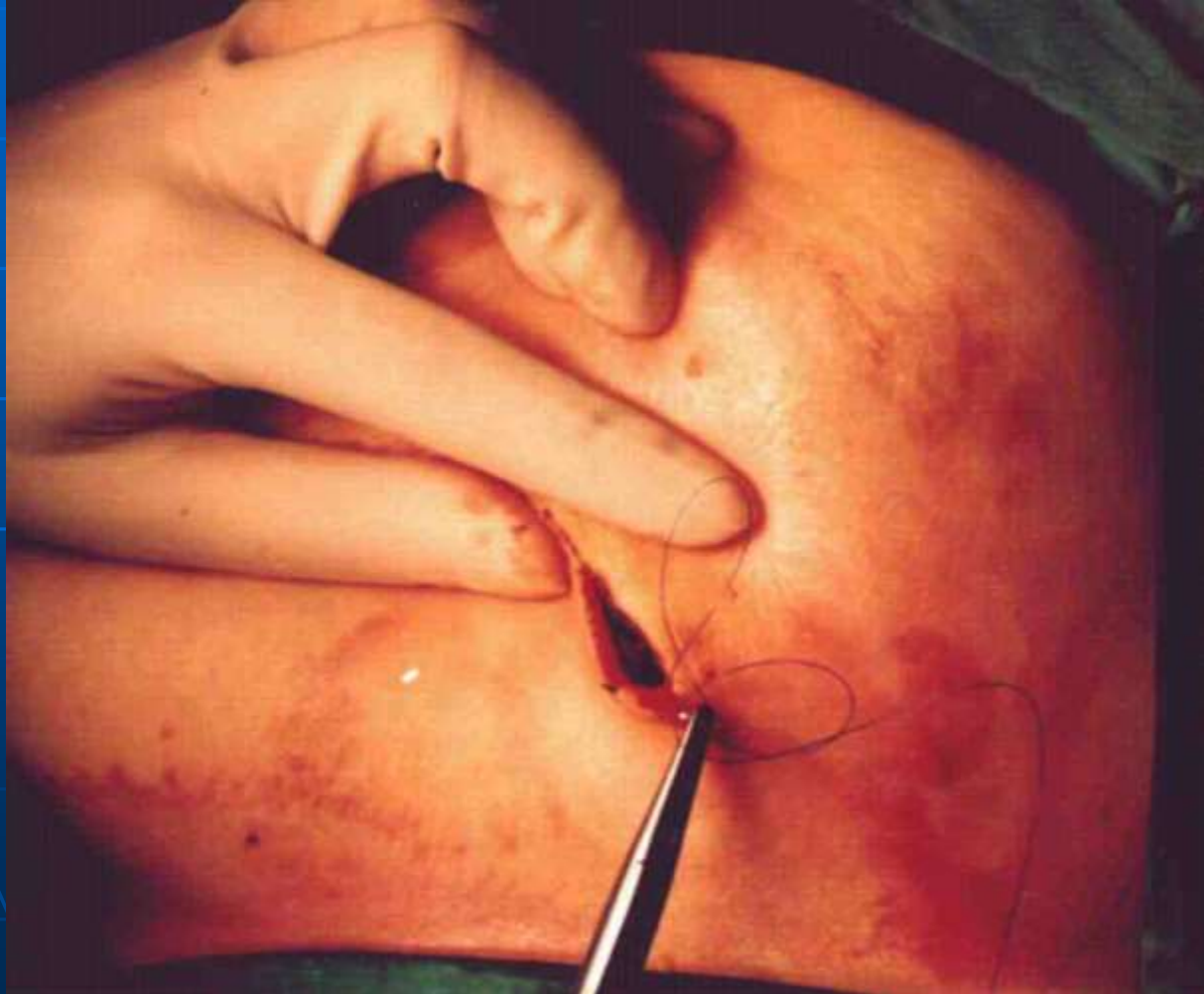
# Ekstirpacija na tumor tumorectomia



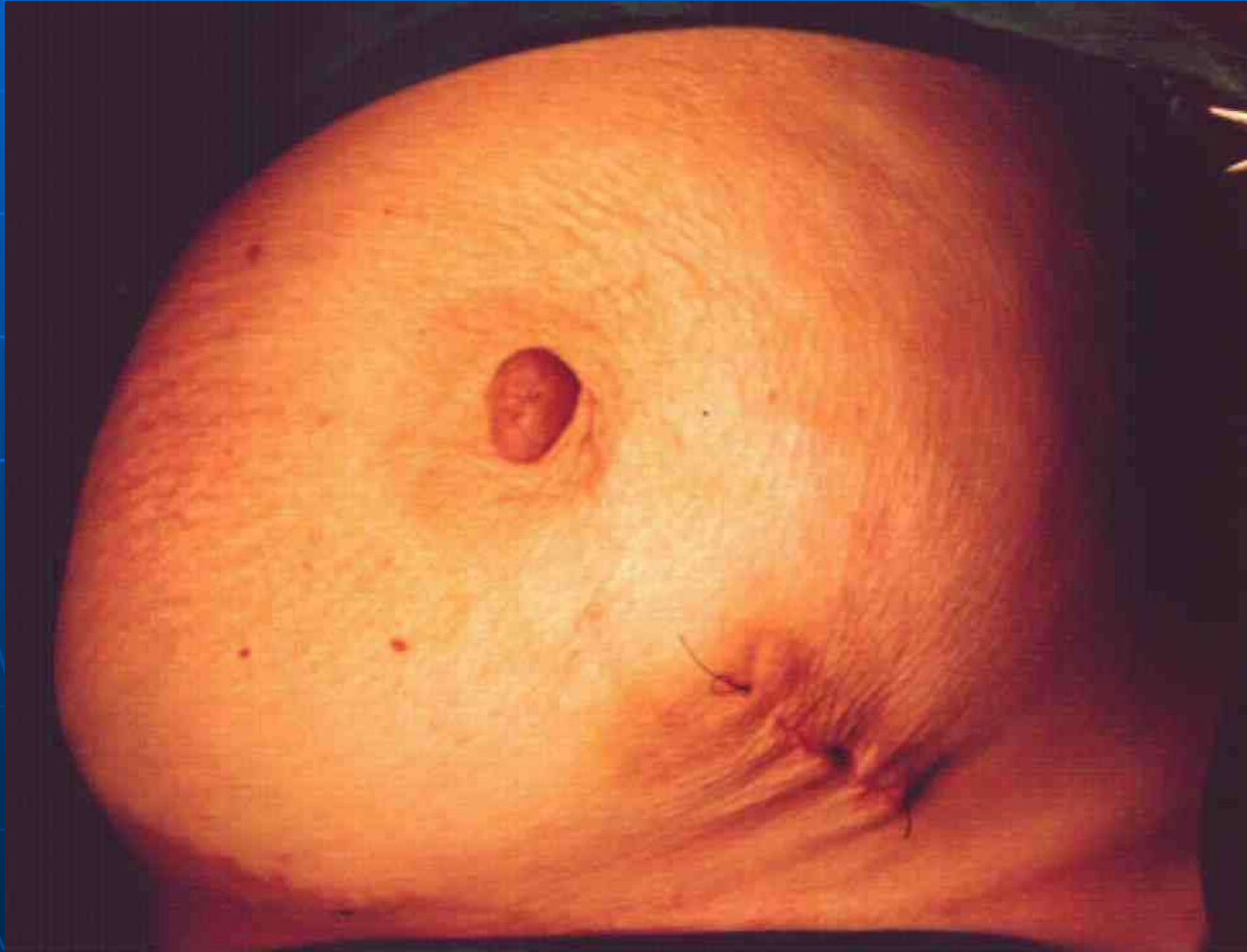# Ekstirpacija na tumor tumorectomia



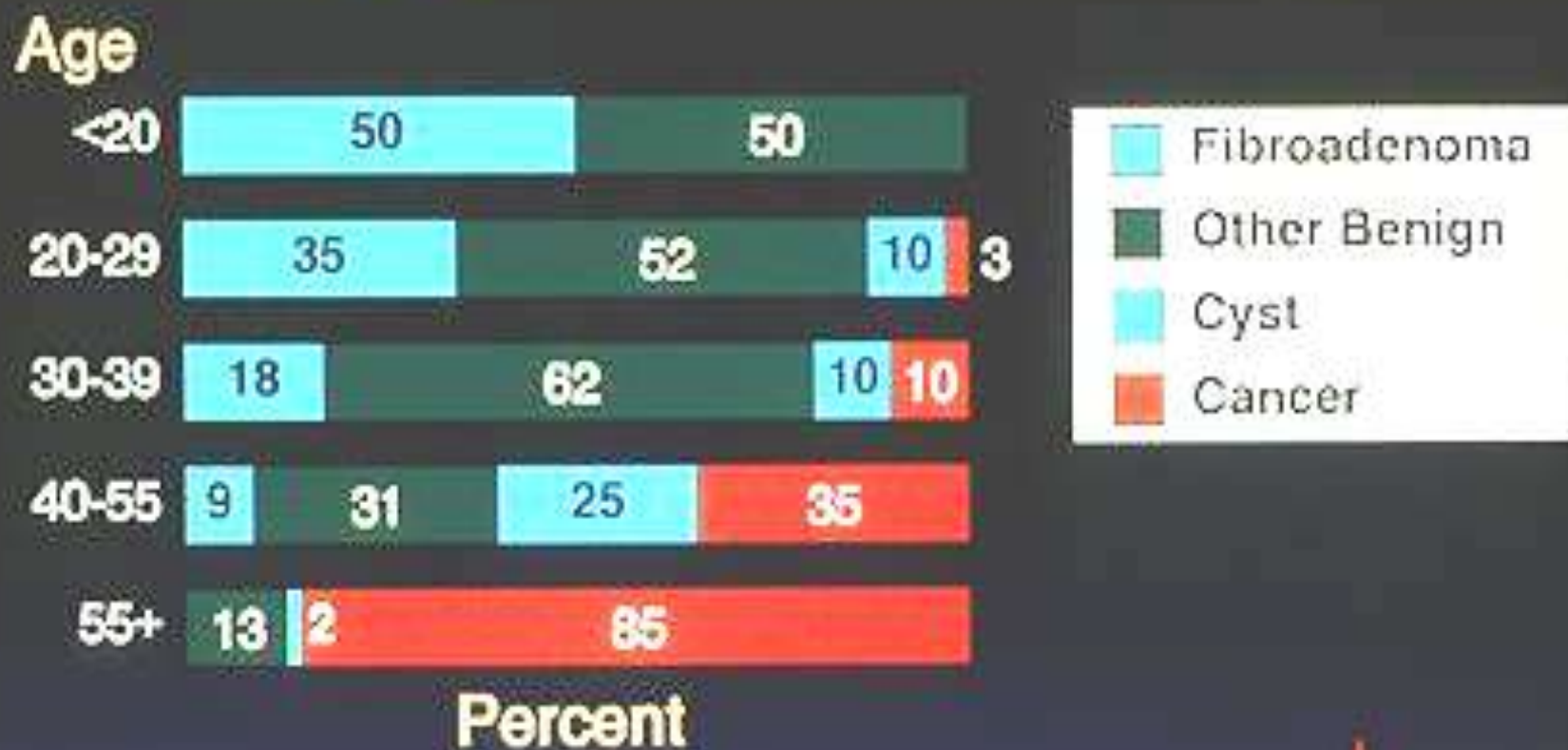# Ekstirpacija na tumor tumorectomia



# Ekstirpacija na tumor tumorectomia



# Etiology of Discrete Breast Lumps\*



\* Estimated fractions based on pooled data from literature review

AMERICAN  
CANCER  
SOCIETY

Florida Division, Inc.

# 4. Karcinom na dojката

- naj~esto maligno zaboluvawe kaj`enata, so zastapenost od 25 do 75 slu~ai na 100 000 `eni
- se manifestira so palpatoeren tumor vo dojkata
- sistemsko zaboluvawe

# Malignom na dojka

- Malignomot na dojkata e naj~esto maligno zaboluvawe kaj `enata (20 do 23%).
- 500 000 vo svetot godi{no se otkrivaat , 135 000 vo Evropa, 750 vo Republika Makedonija.
- Poslednite godini se zgolemuva morbiditetot i mortalitetot, incidencijata godi{no raste 2-3%, a mortalitetot 1-2%.



# Malignom na dojka



129,8/  
35

94,3/  
52,2

106,8/  
43,5

76,4/  
42,7

84,3/  
34,9

60,4/  
27,0

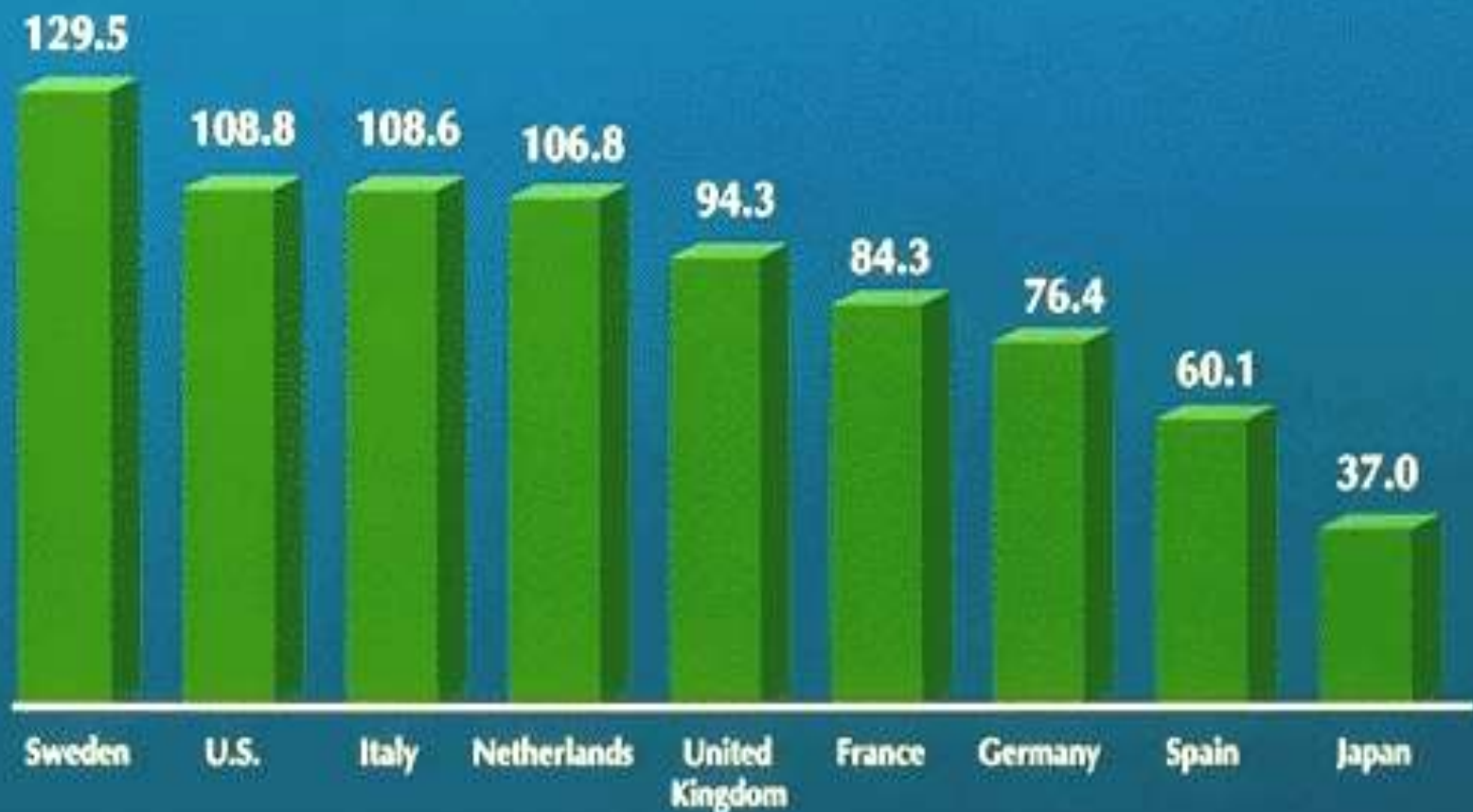108,6/  
6,5

36,95/  
6,19

incidencia/  
na 100000/      mortalitet/  
na 100000

# BREAST CANCER

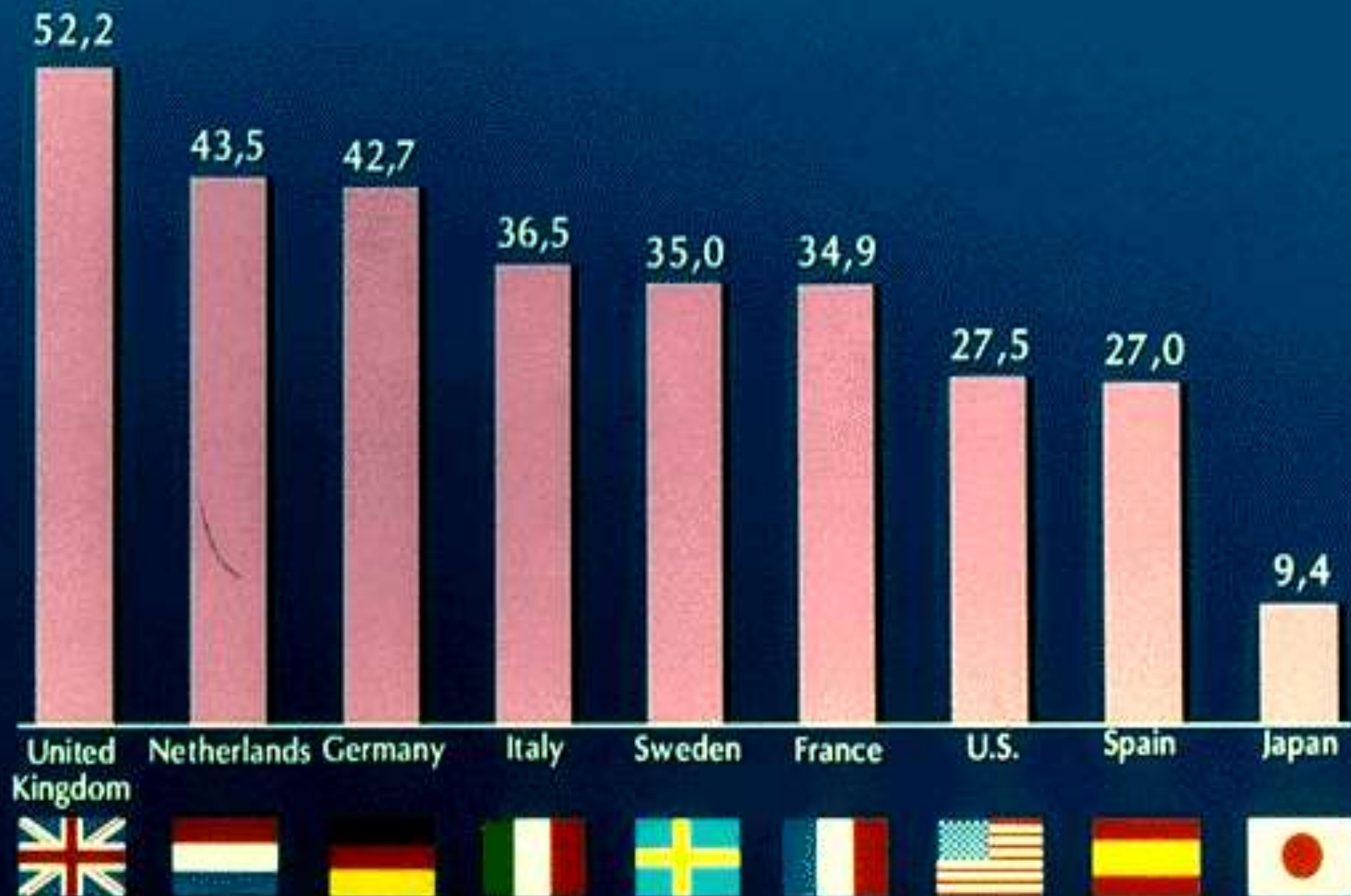INCIDENCE RATE (per 100,000 women)



*Adapted from International Opportunities in Cancer Management-SRI International, 1994.*

# BREAST CANCER

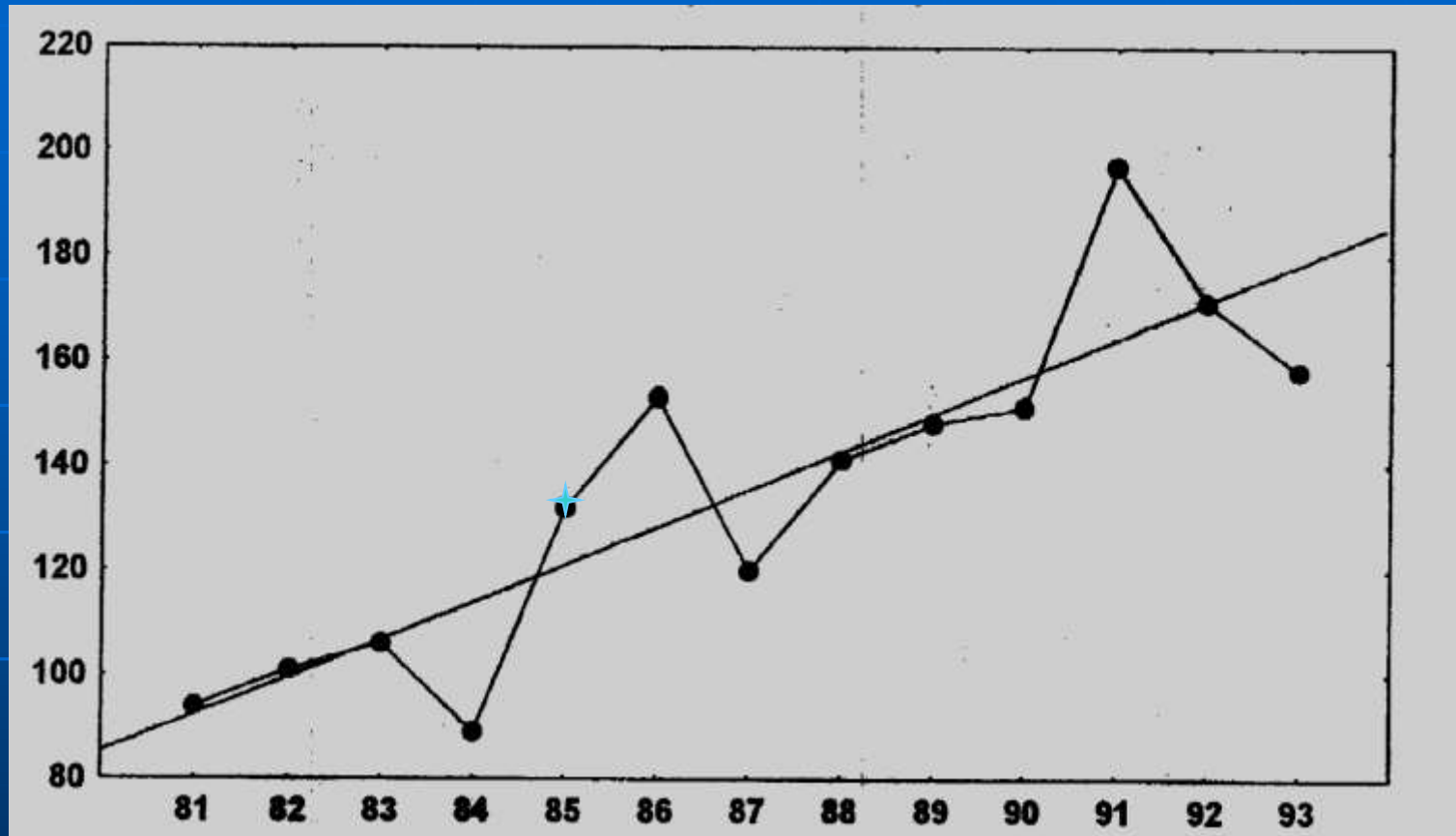
MORTALITY RATE (per 100 000 women)



Adapted from International Opportunities in Cancer Management-SRI International, 1994.

COUNTRY	MORBIDITY /100 000	MORTALITY /100 000
USA	109	34
Yugoslavia	95	21.9
Norway	94	35.4
Island	84	25.7
Swiss	80	49.6
France	80.5	34.9
Italy	80	36.8
Austria	64	41.1
<b>Macedonia</b>	<b>39.5</b>	<b>15.9</b>
Spain	36	21.4
Polska	36	21.4
Germany	26	34.9
Japan	17	9.4

# Breast cancer- Morbidity rate-Macedonia



increasing of morbidity rate (2 to 3% per year)  
increasing of mortality rate (1 to 2% per year)

# **Malignom na dojkata**

**Sekoja 8 - 20`ena ima  
{ansa vo `ivotot da dobie  
malignom na dojkata**

# Malignom na dojka

**Pri~inite** za zaboluvaweto ne se poznati, a se pretpostavuva deka mo`e da se genski, endokrini i pri~ini od sredinata.

**Rizi~ni faktori** se : familijarna istorija za malignom na dojka i genska predispozicija, benigni zaboluvawa na dojkata i predhoden malignom na dojkata.

tumor supresorski geni

↓  
produkti (enzimi za popravka na DNK., faktori za  
keto~na diferencijacija)

**Normalna**  
kletka

**Maligno alterirana**  
kletka

↓  
Kontrolirana  
diferencijacija

nediferenciranost

↓  
Kontrolirana  
delba

↑  
produkti

nekontrolirana

faktori na rast, inhibitori na dif.

delba

↑  
protoonkogeni





# tumor supresorski geni

↓  
produkti (enzimi za popravka na DNK., faktori za klet~na diferencijacija)

**Normalna**  
kletka

**Maligno alterirana**  
kletka

↓  
Kontrolirana  
diferencijacija

←  
produkti  
faktori na rast, inhibitori na dif

→  
nediferenciranost

↓  
Kontrolirana  
delba

↑  
**onkogen**

↓  
nekontrolirana

↓  
delba

→  
mutacija

↑  
protoonkogeni

↓  
malignom

↑  
karcinogen

tumor supresorski geni karcinogeni

mutacija

produkti (enzimi za popravka na DNK., faktori za kletona diferencijacija)

inaktivatori

**Normalna kletka**

**Maligno alterirana kletka**

Kontrolirana diferencijacija

produkti faktori na rast, inhibitori na dif

nediferenciranost

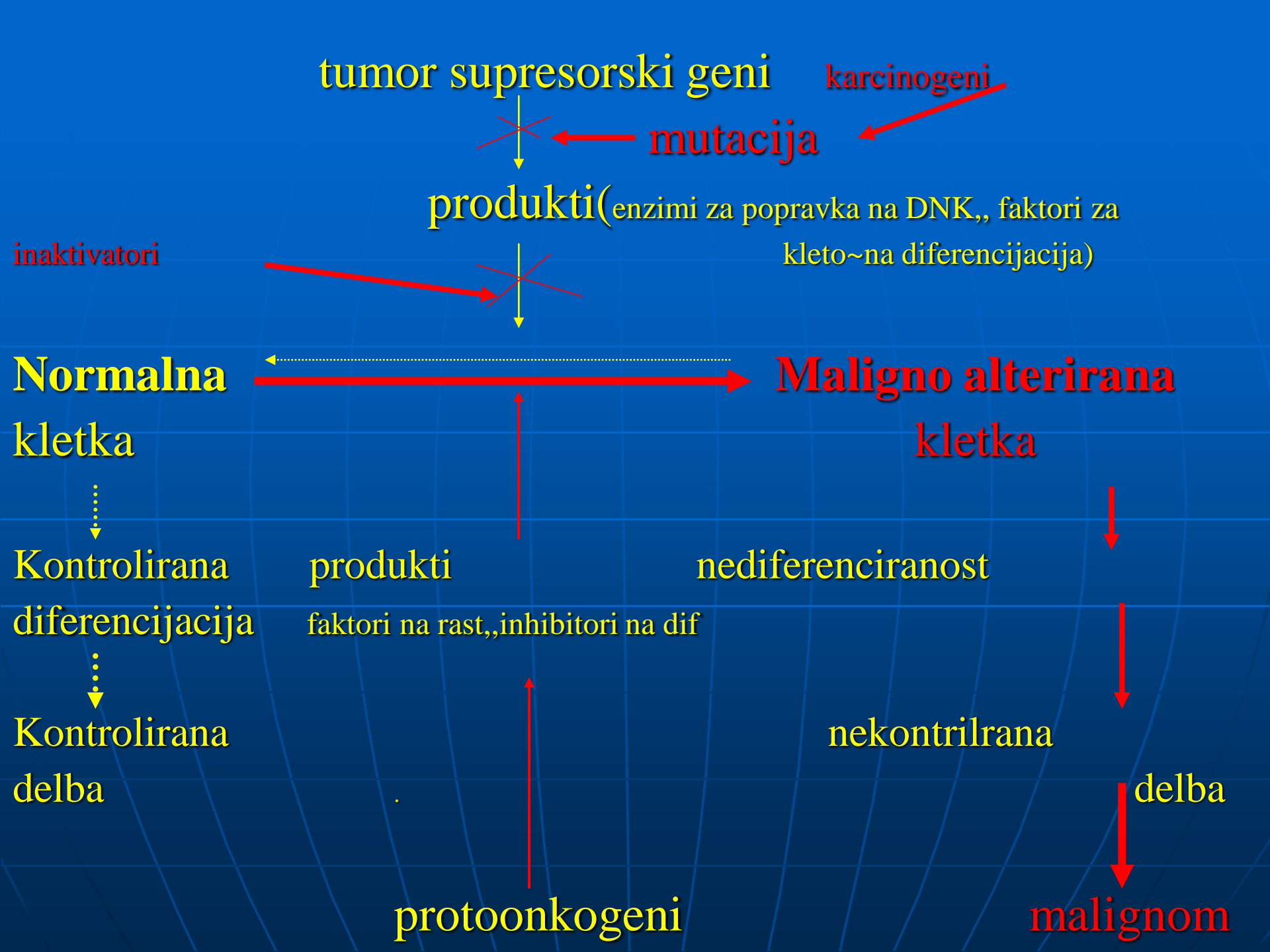
Kontrolirana delba

nekontrolirana

delba

protoonkogeni

malignom



# MALIGNOM NA DOJKATA

hiperekspresija, delecija, mutacija,  
translokacija, amplifikacija

## \* protoonkogeni:

**c Ha ras**

**c myc**

**EGF receptor**

**c erb b (HER-1)**

**c erb b2 (HER-2)**

**bcl 1, 2**

## \*\*tumor supresorski geni

**maspin gen**

**BRCA 1, 2, ....**

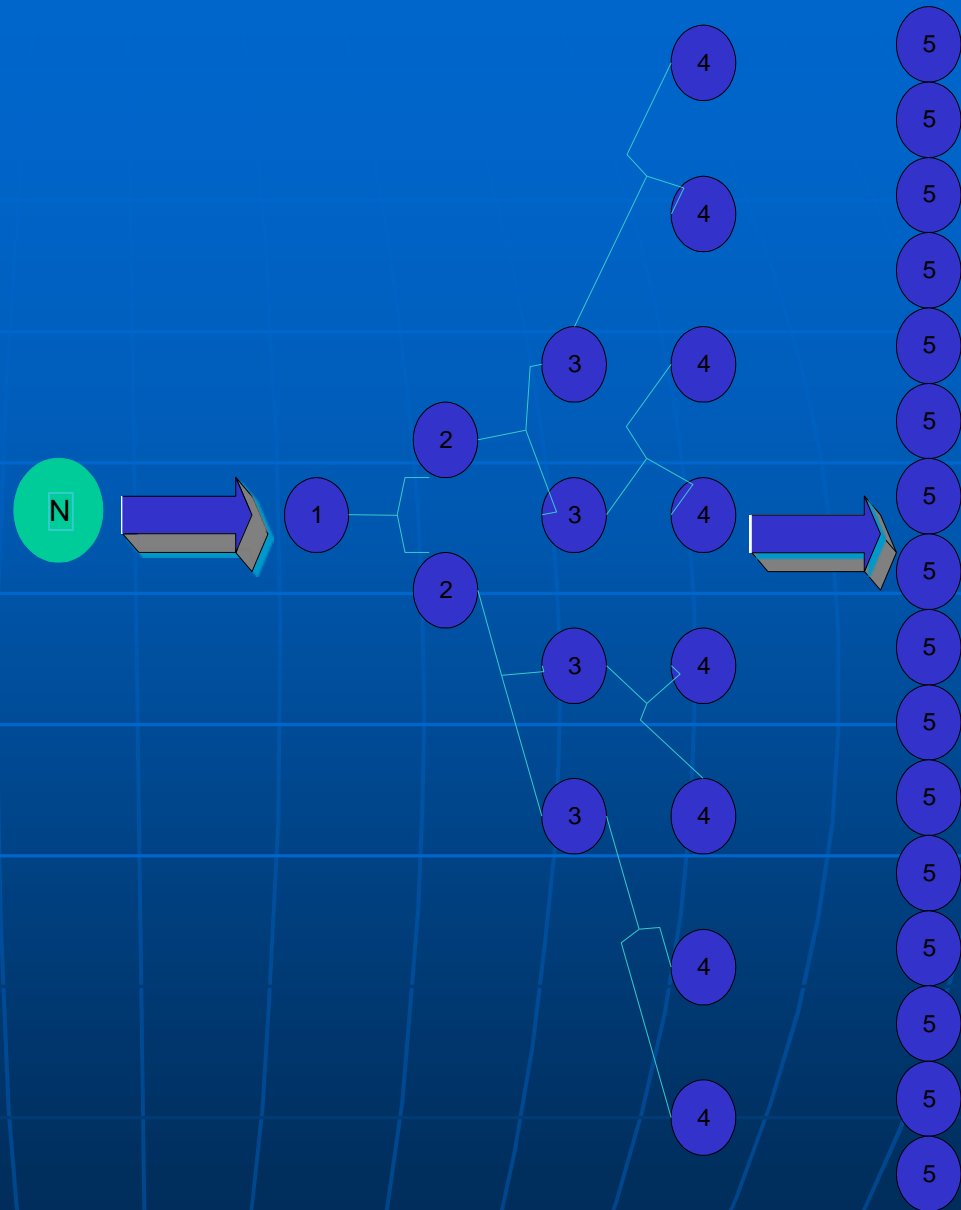
**p53**

**Rb**

- **BRCA-1** e lociran na **17q** hromozom, . Skoro **2/3** od pacientite so nositelstvo na mutacija na ovoj gen se asocirani so pojava na malignom na dojka do **50** godi{na starost. Spored brojni ispituvawa rizikot da nositelite na mutacija na **BRCA-1** dobijati malignom na dojka vo tek na `ivotot e **50-80%**, da dobijati malignom na drugata dojka e **15-45%** i da dobijati malignom na ovarium e **15-45%**.

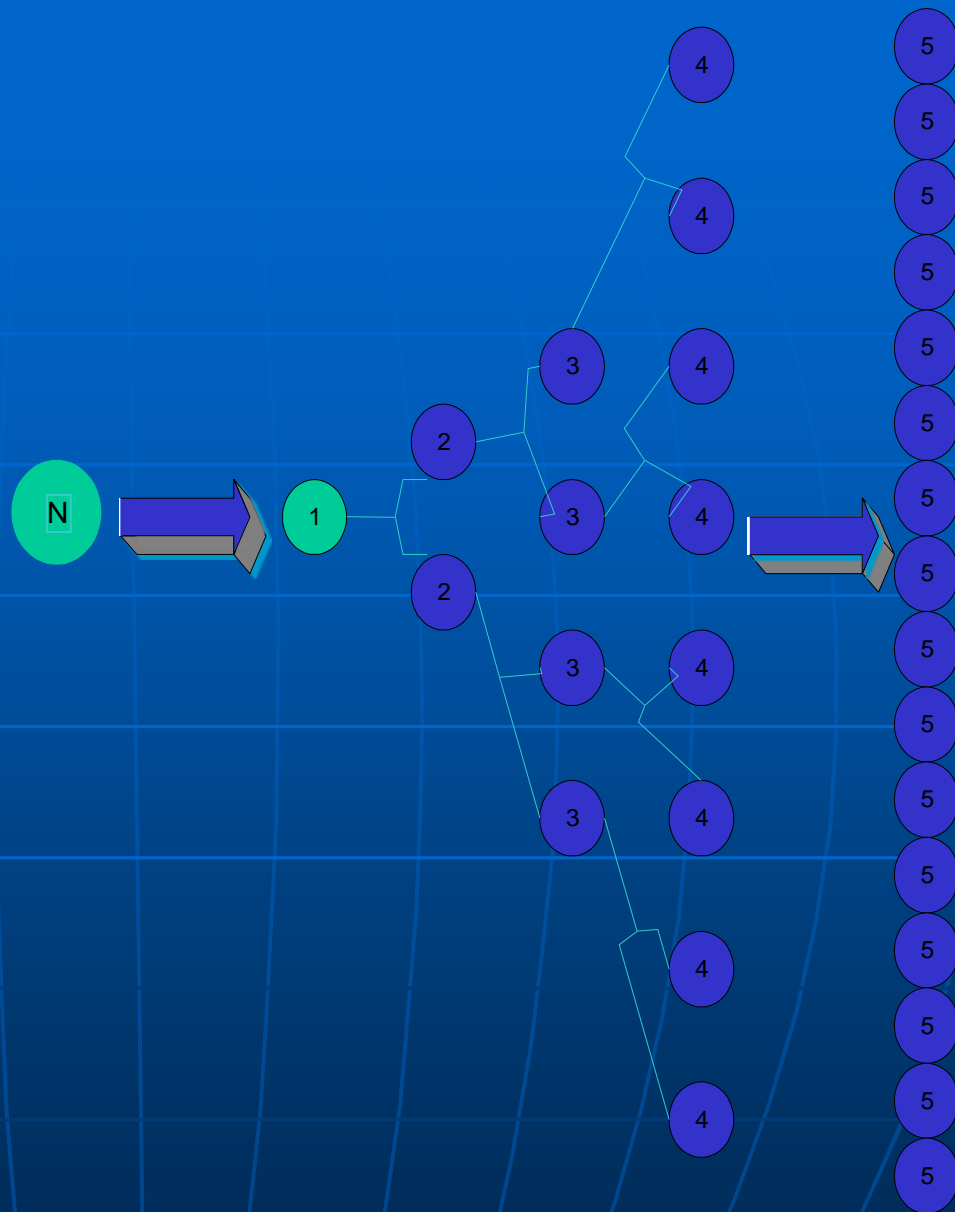
**Anaplazija na  
normalna kletka,**

**sozdavawe klon  
na maligni kletki  
i negov razvoj vo  
maligni tumor**



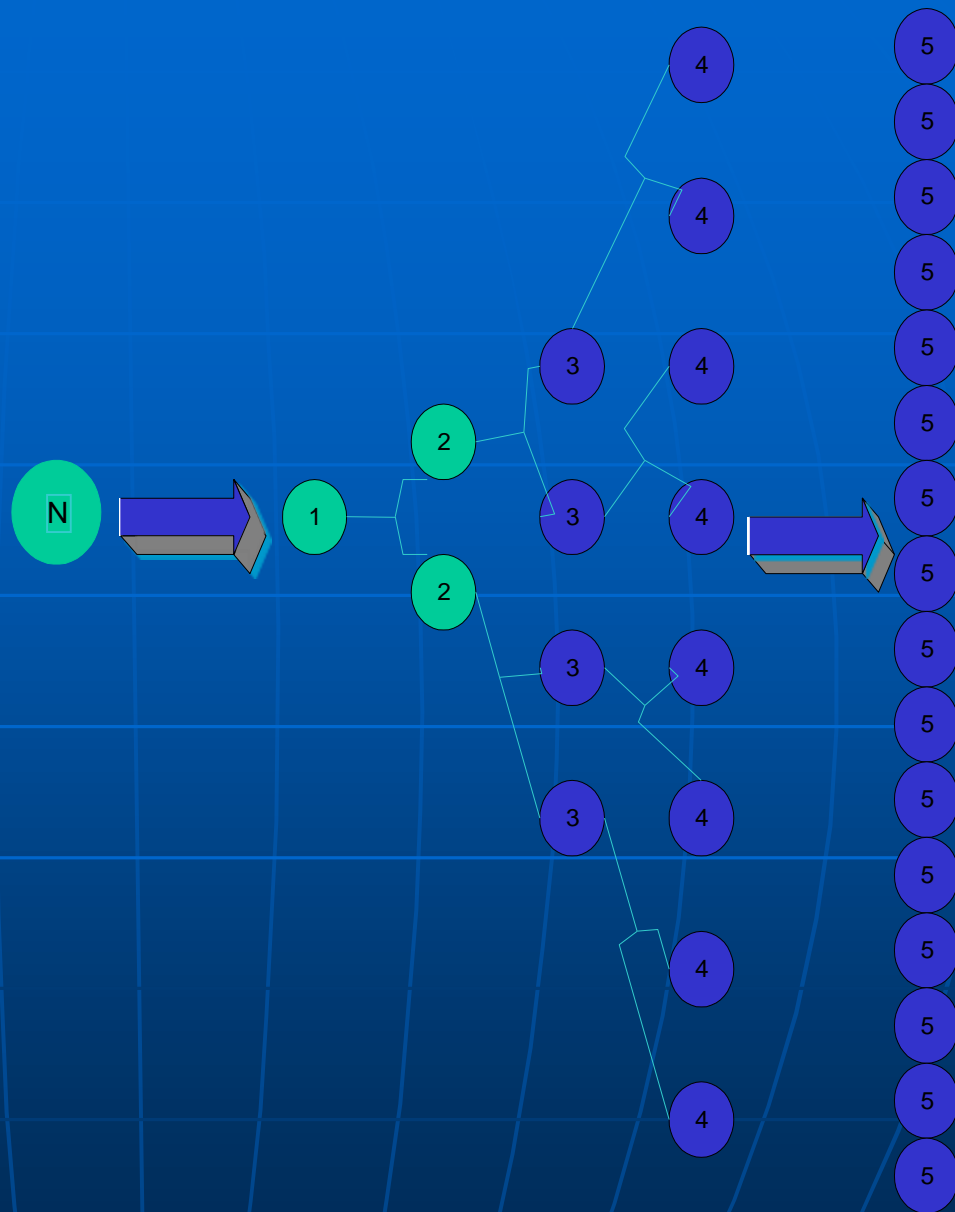
**Anaplazija na  
normalna kletka,**

**sozdavawe klon  
na maligni kletki  
i negov razvoj vo  
maligni tumor**



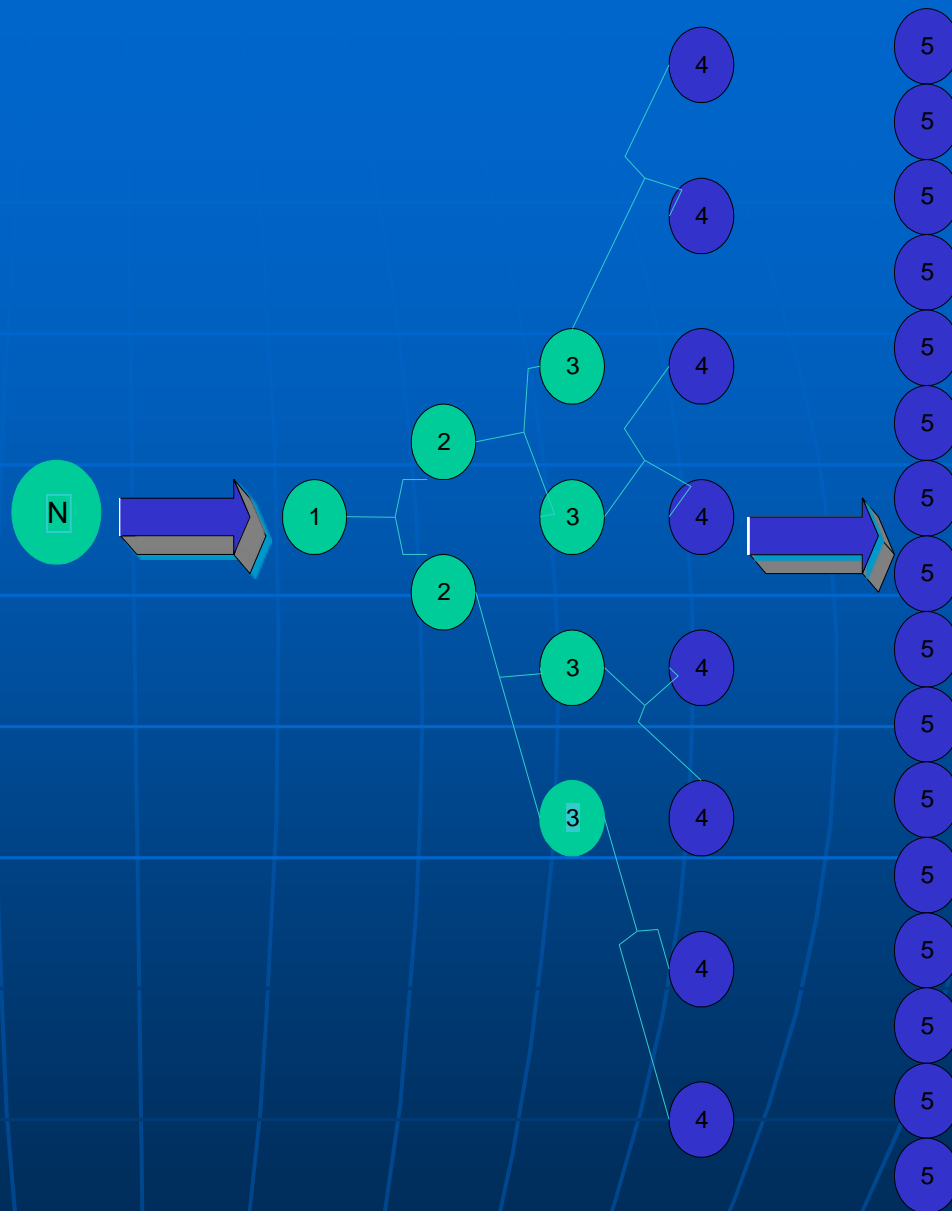
**Anaplazija na  
normalna kletka,**

**sozdavawe klon  
na maligni kletki  
i negov razvoj vo  
maligni tumor**



**Anaplazija na  
normalna kletka,**

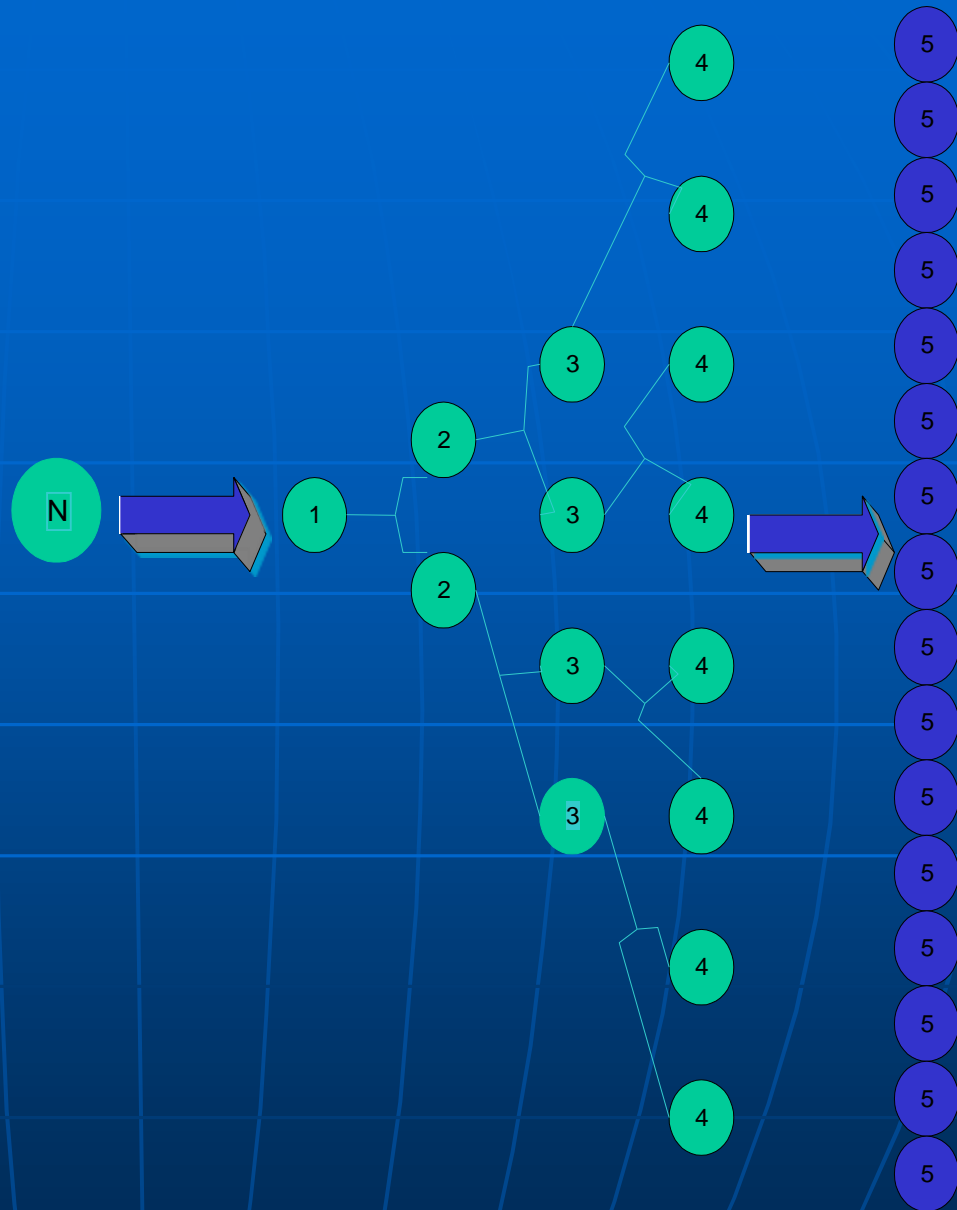
**sozdavawe klon  
na maligni kletki  
i negov razvoj vo  
maligni tumor**





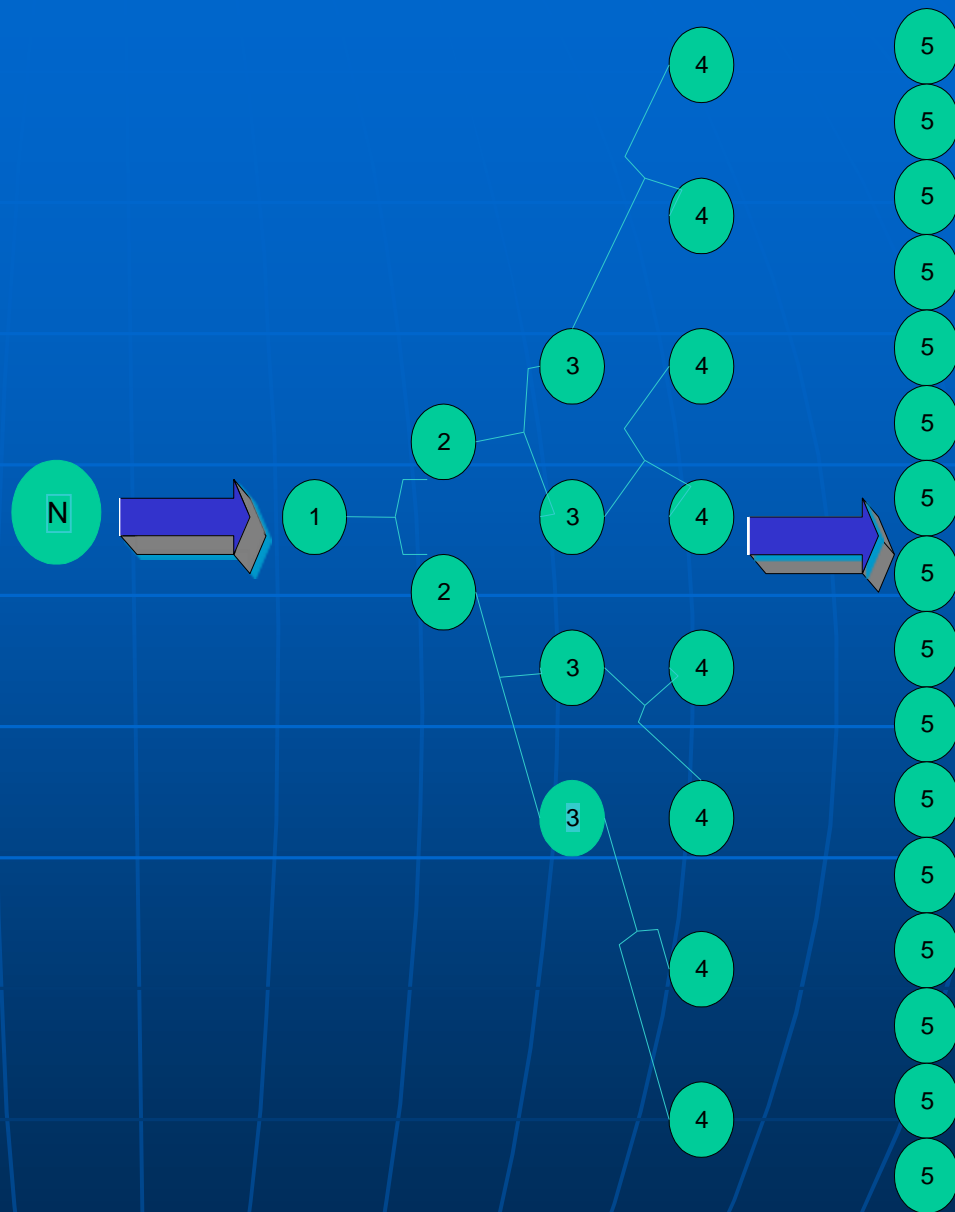
**Anaplazija na  
normalna kletka,**

**sozdavawe klon  
na maligni kletki  
i negov razvoj vo  
maligni tumor**

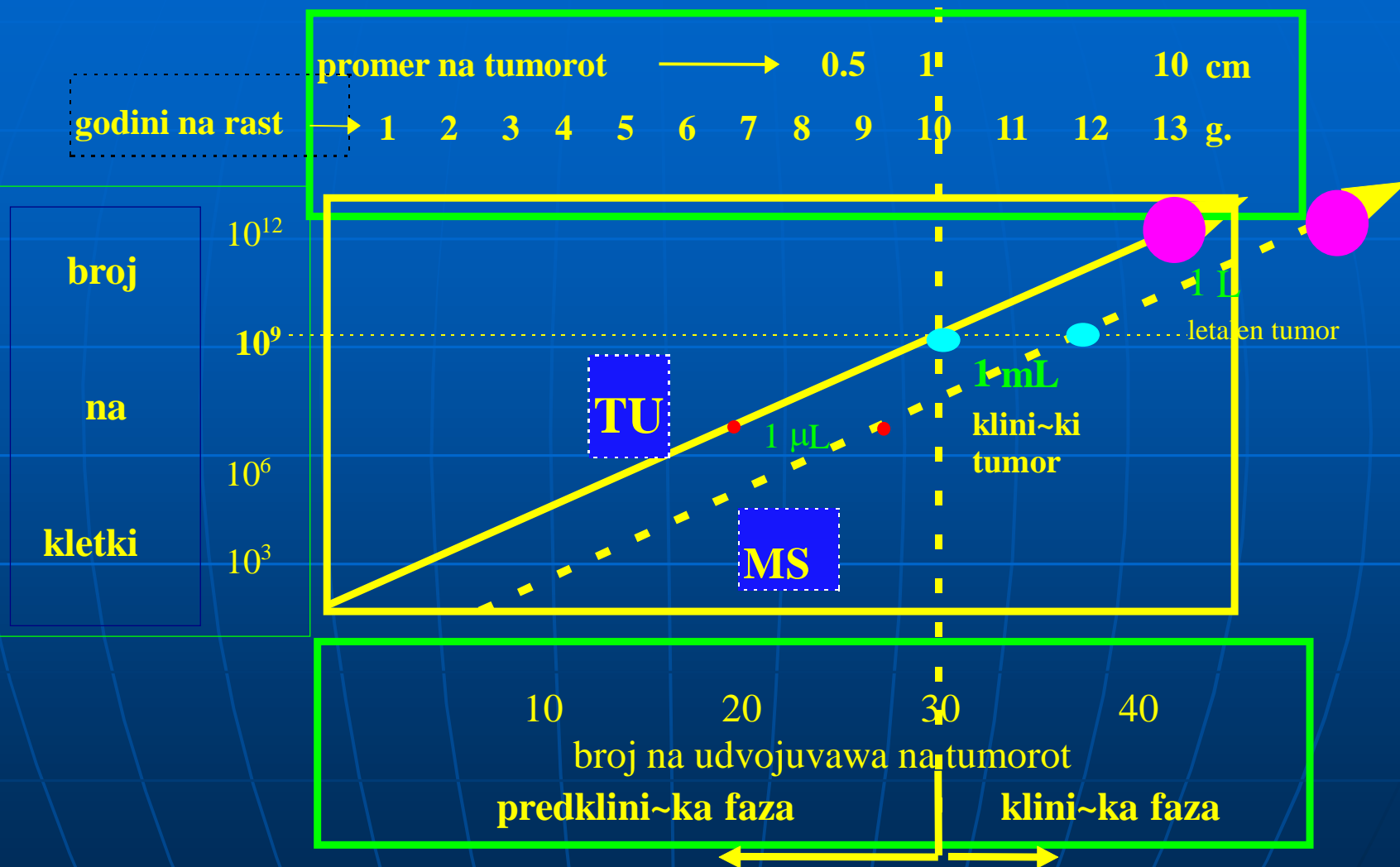


**Anaplazija na  
normalna kletka,**

**sozdavawe klon  
na maligni kletki  
i negov razvoj vo  
maligni tumor**



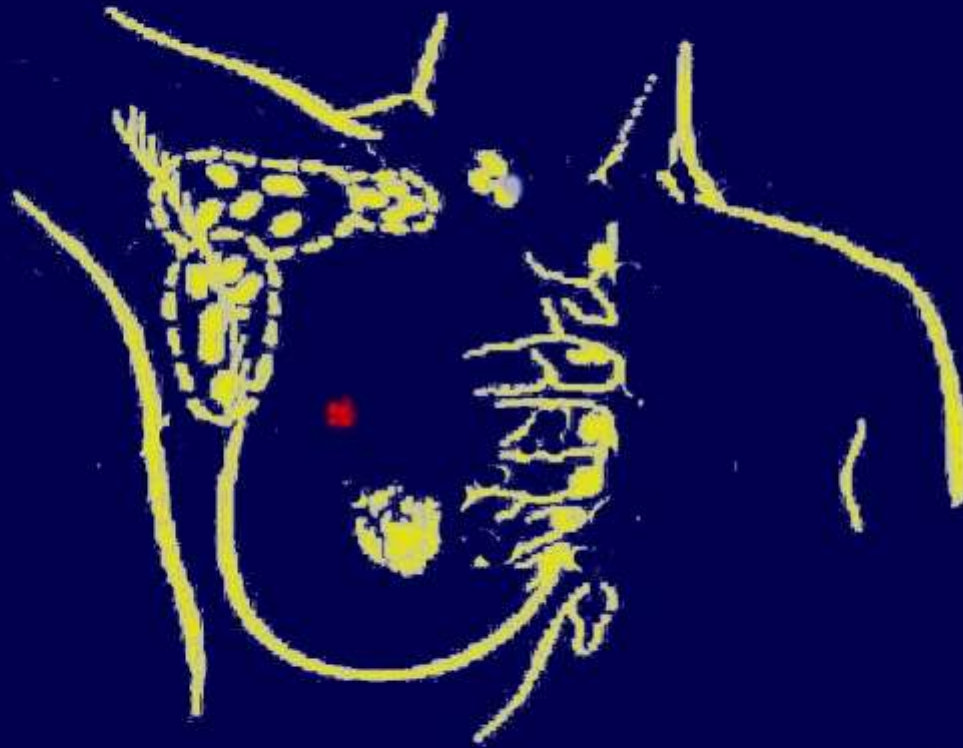# Biologija na malignomot na dojkata



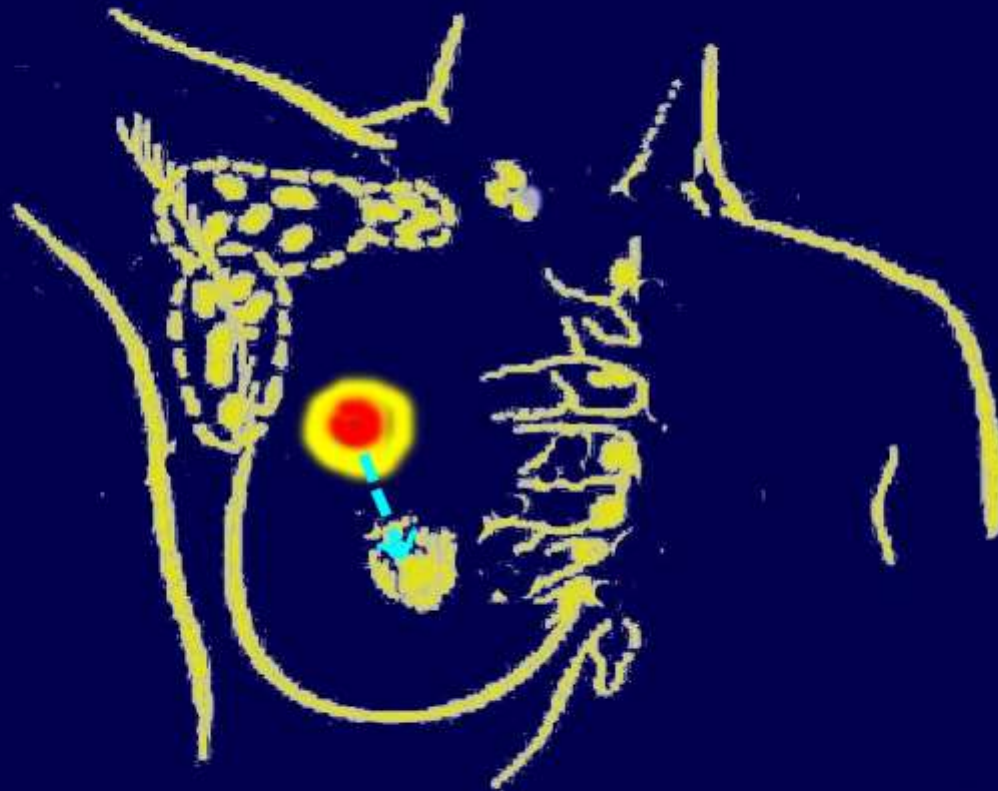
# [IREWE (METASTAZIRAWE) NA MALIGNOMOT NA DOJKATA

- **Lokalno**
  - vo tkivoto
  - intraduktalno
  - limfogeno
- **Regionalno vo regionalni limfni jazli**
- **Dale~no (metastazirawe)**
  - hematogeno
  - limfogeno

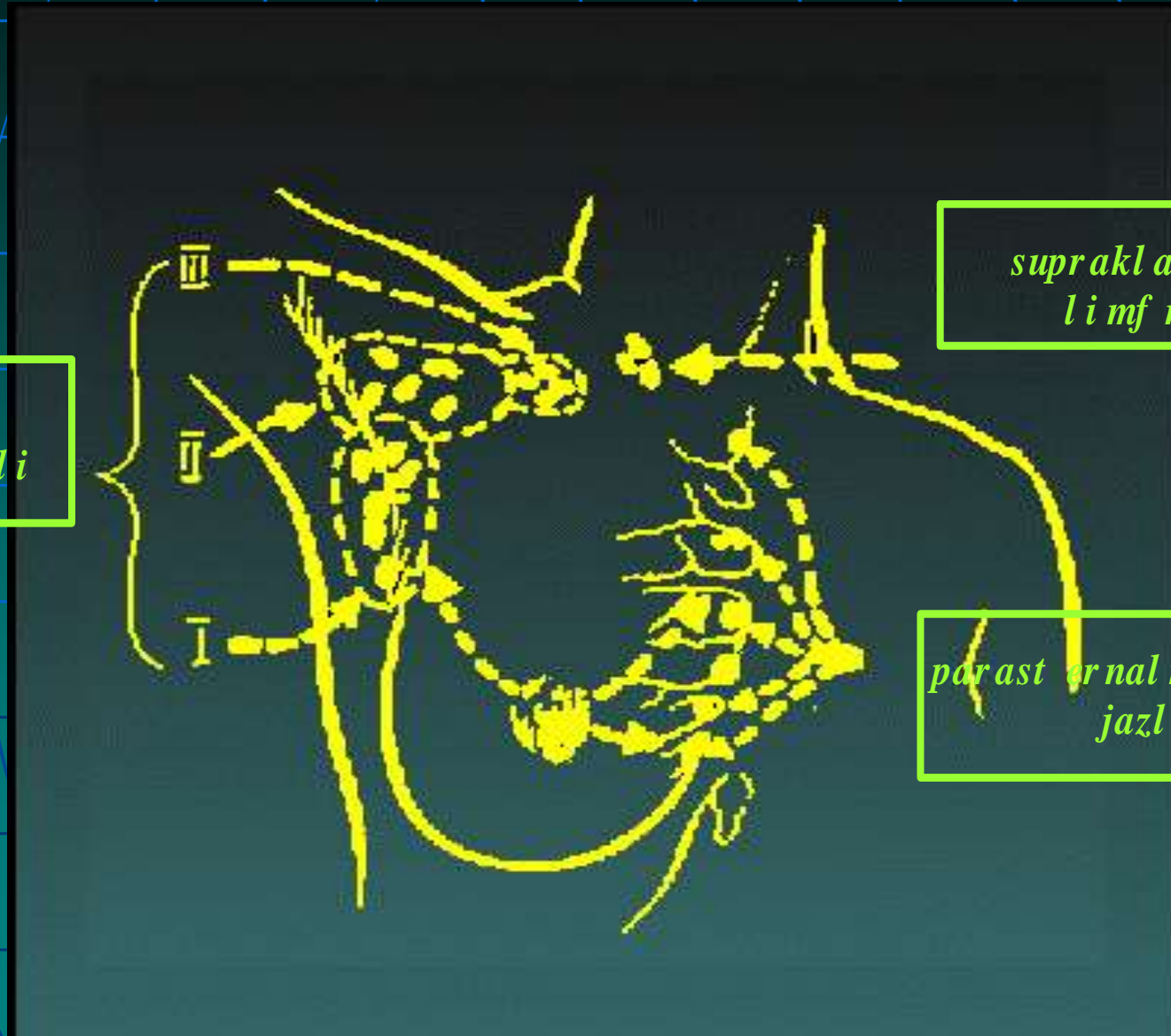
# Lokalno {irewe



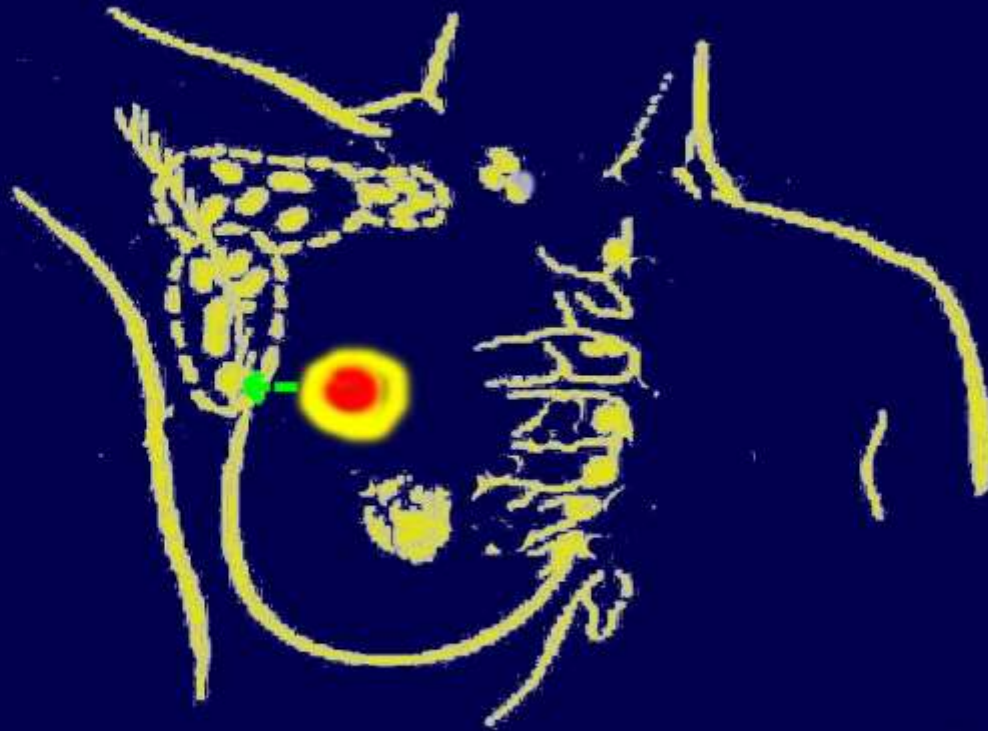
# Lokalno {irewe- intraduktalno



# Regionalno {irewe

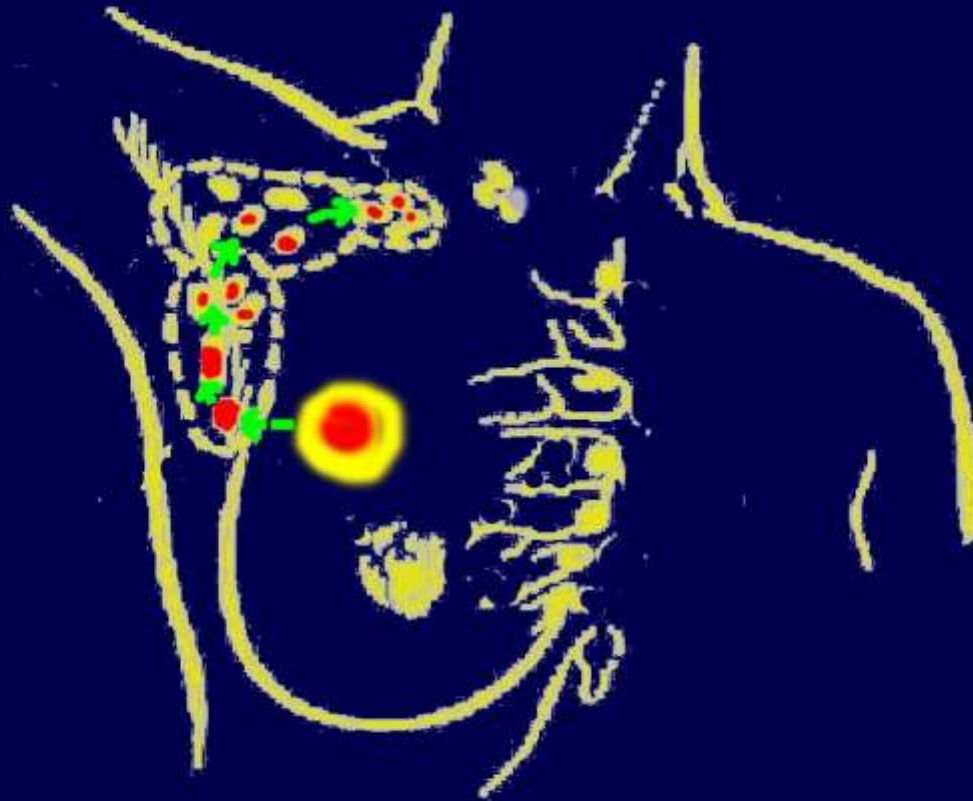


# Regionalno {irewe- “Sentinel Lynd”-”Stra`ar”

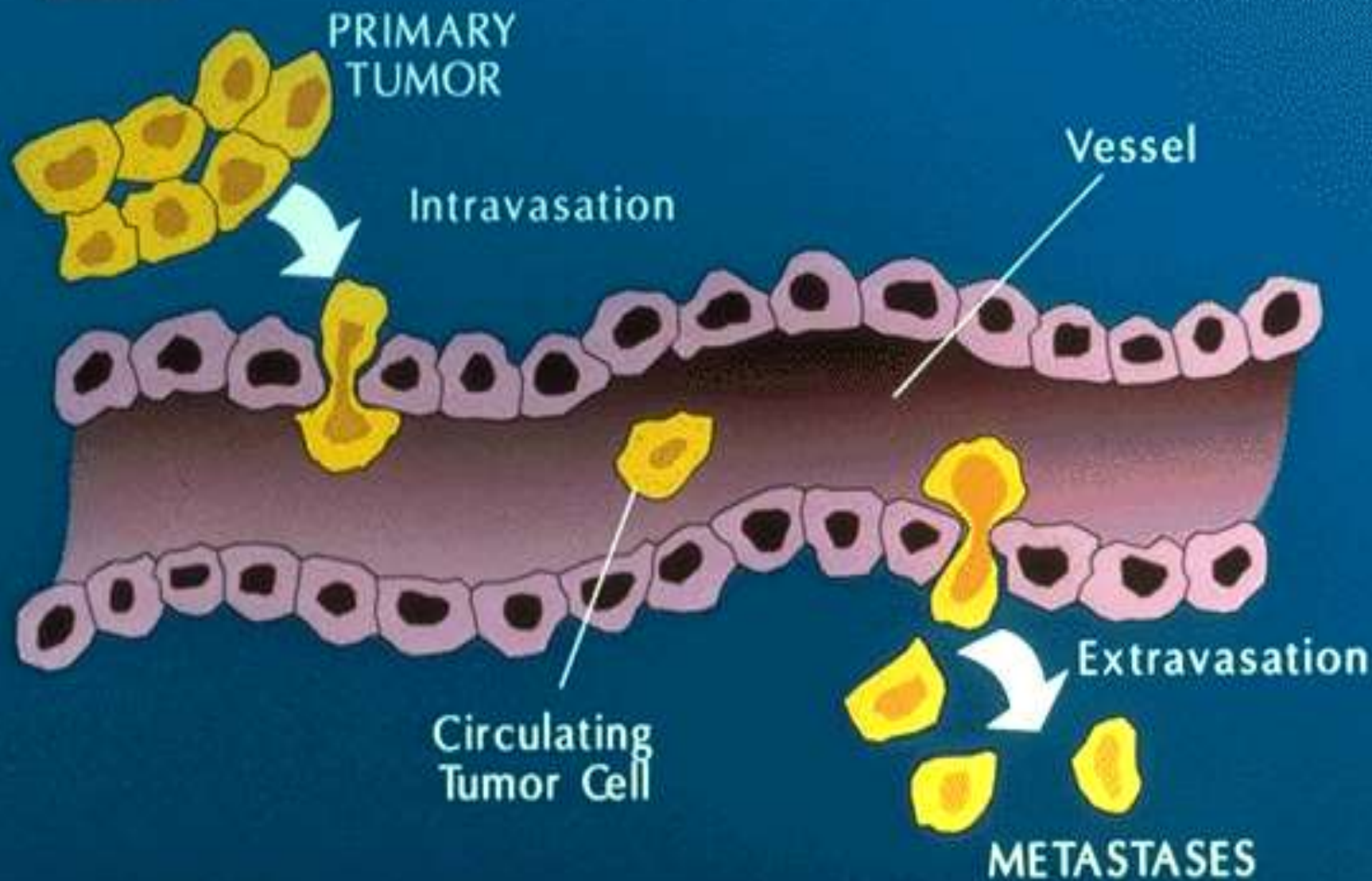




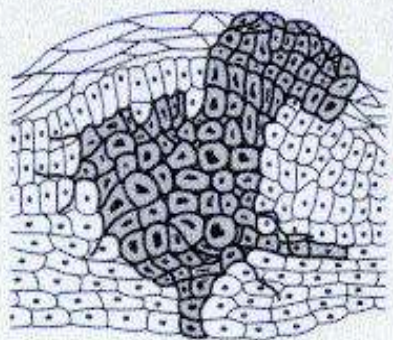
# Regionalno širewe- postapno širewe po katovi vo aksilata



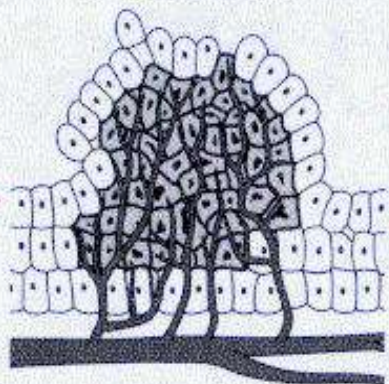
# INVASION AND METASTASIS



Primary tumor



Angiogenesis

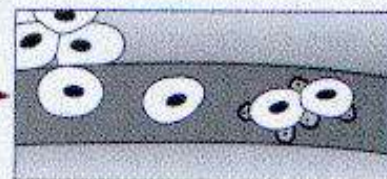


Invasion

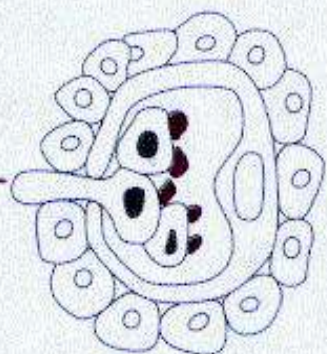


Lymphatics  
Venules  
Capillaries

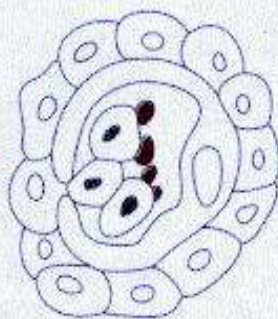
Embolism



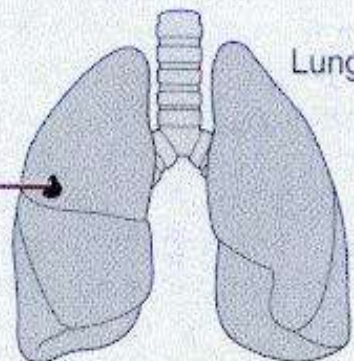
Interaction with platelets,  
lymphocytes, and other  
blood components



Extravasation

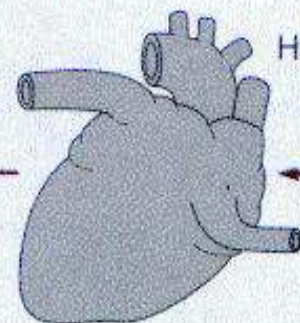


Adherence to vessel wall



Arrest in organs

Lung



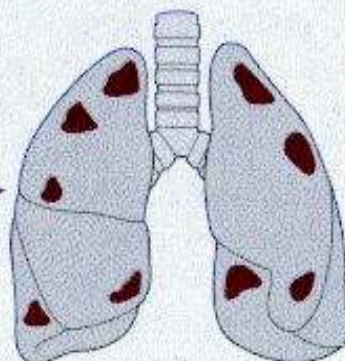
Transport

Heart

Establishment of a  
microenvironment

Proliferation

Metastases



# Prognoza na zaboluvaweto

- stadium na zaboluvaweto vo koe se nao|a
- adekvatna terapija

# BREAST CANCER/LOCAL MANIFESTATIONS


## SIGNS AND SYMPTOMS AT PRESENTATION

- Palpable mass
- Thickening
- Pain

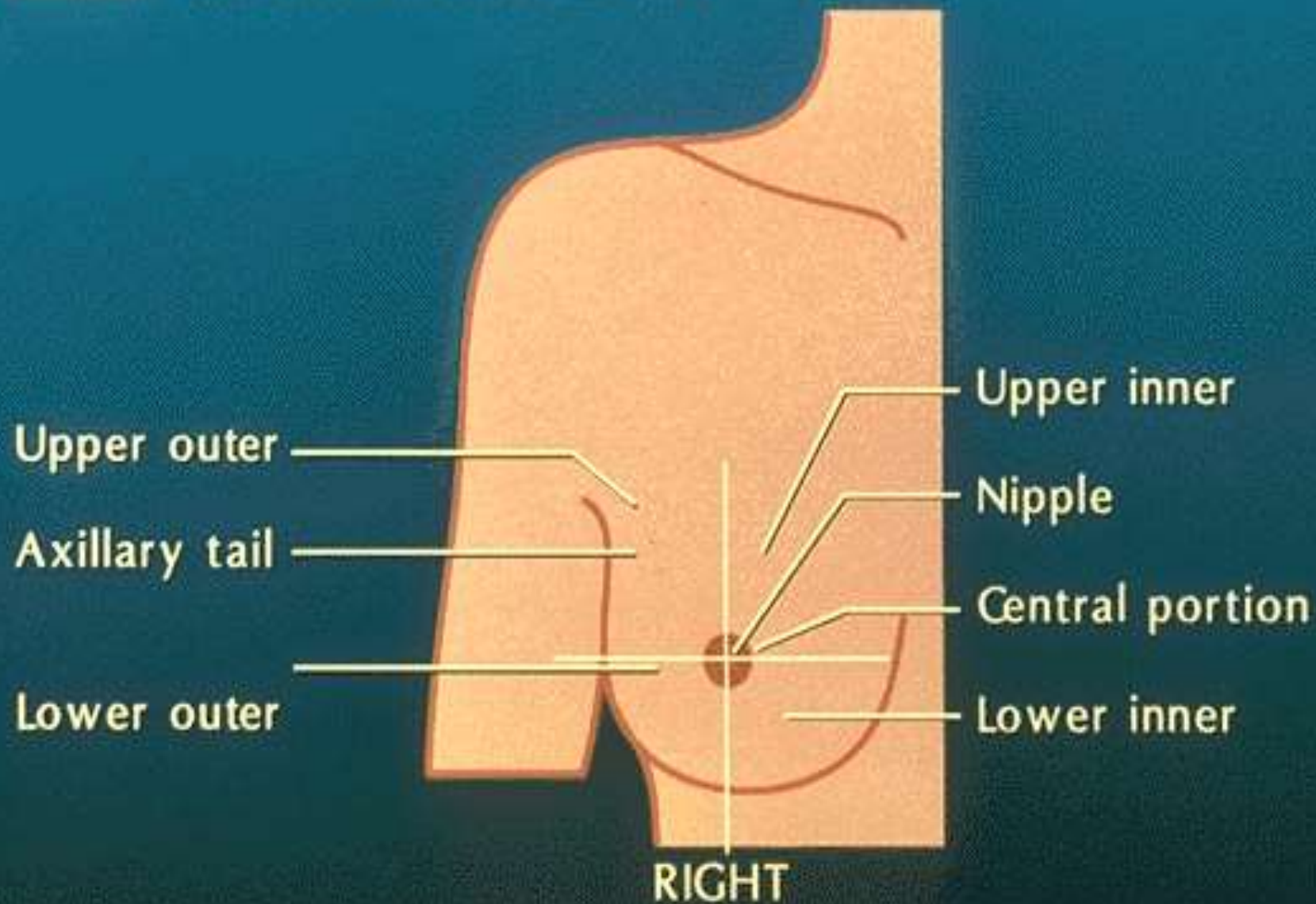
- Mass or pain in the axilla

- Nipple discharge
- Nipple retraction

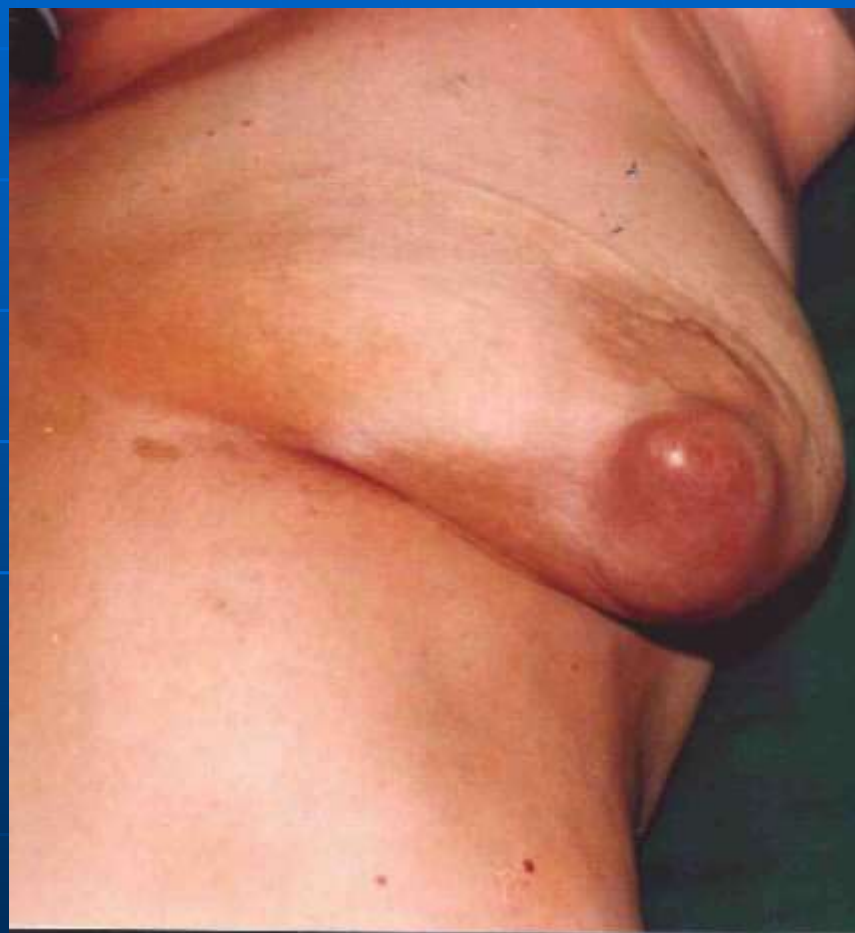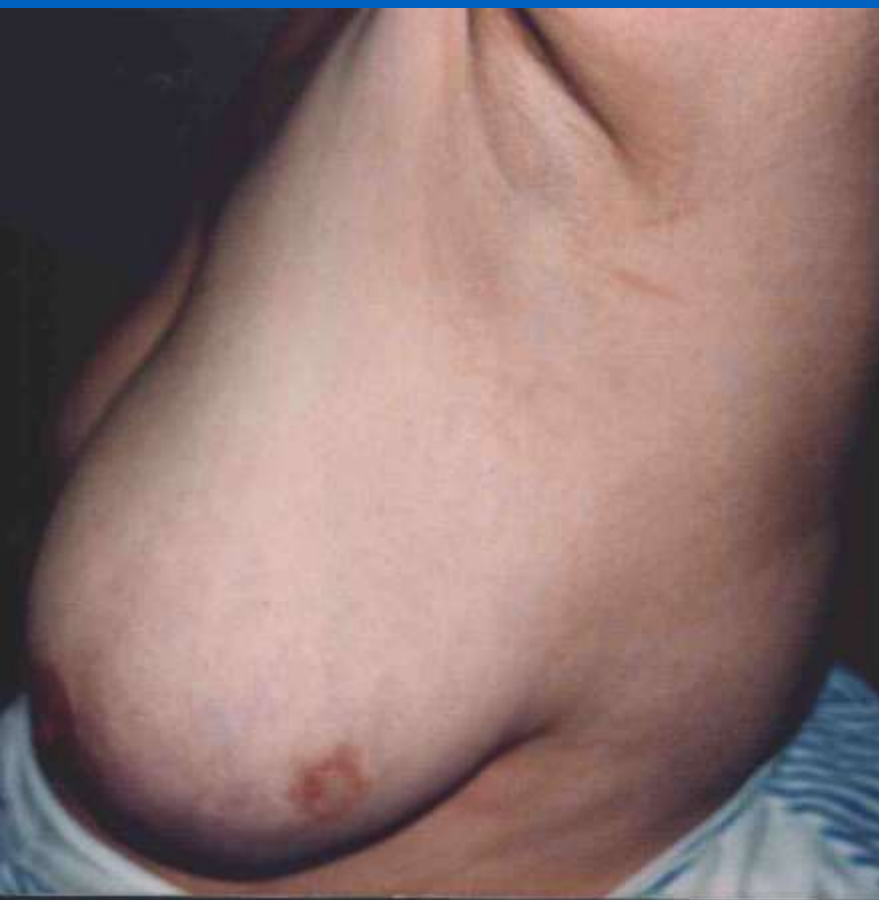- Edema or erythema of the skin



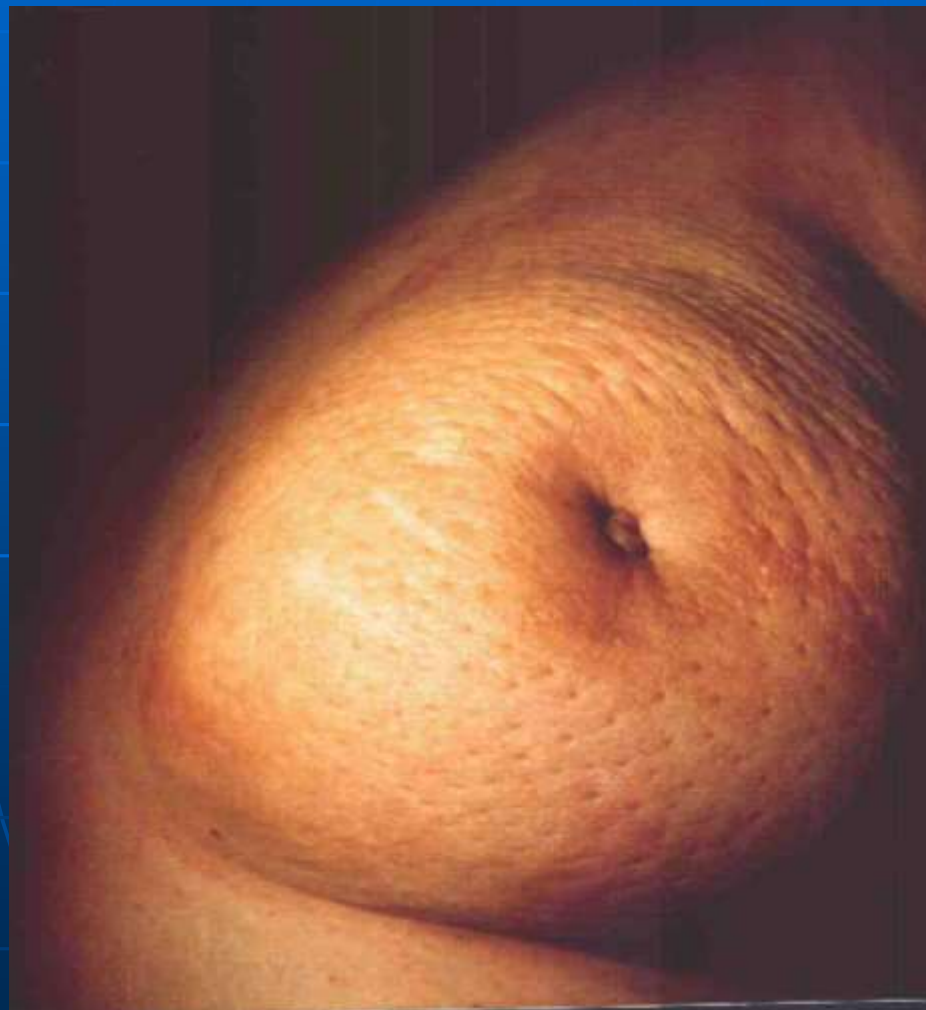# BREAST CANCER ANATOMICAL SITE



# Malignom na dojka

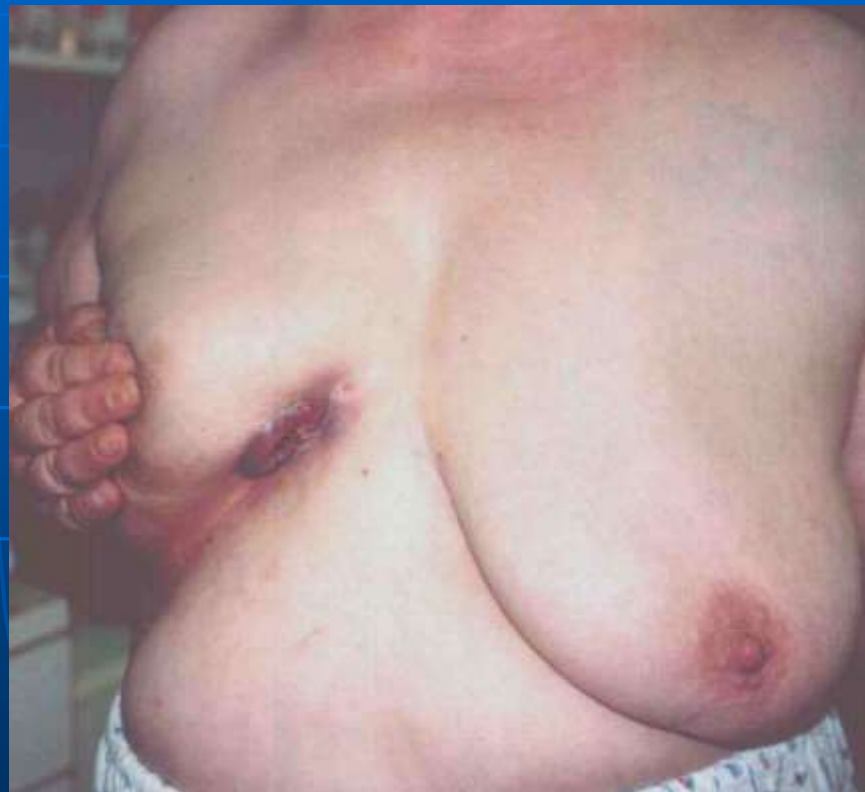

# Malignom na dojka



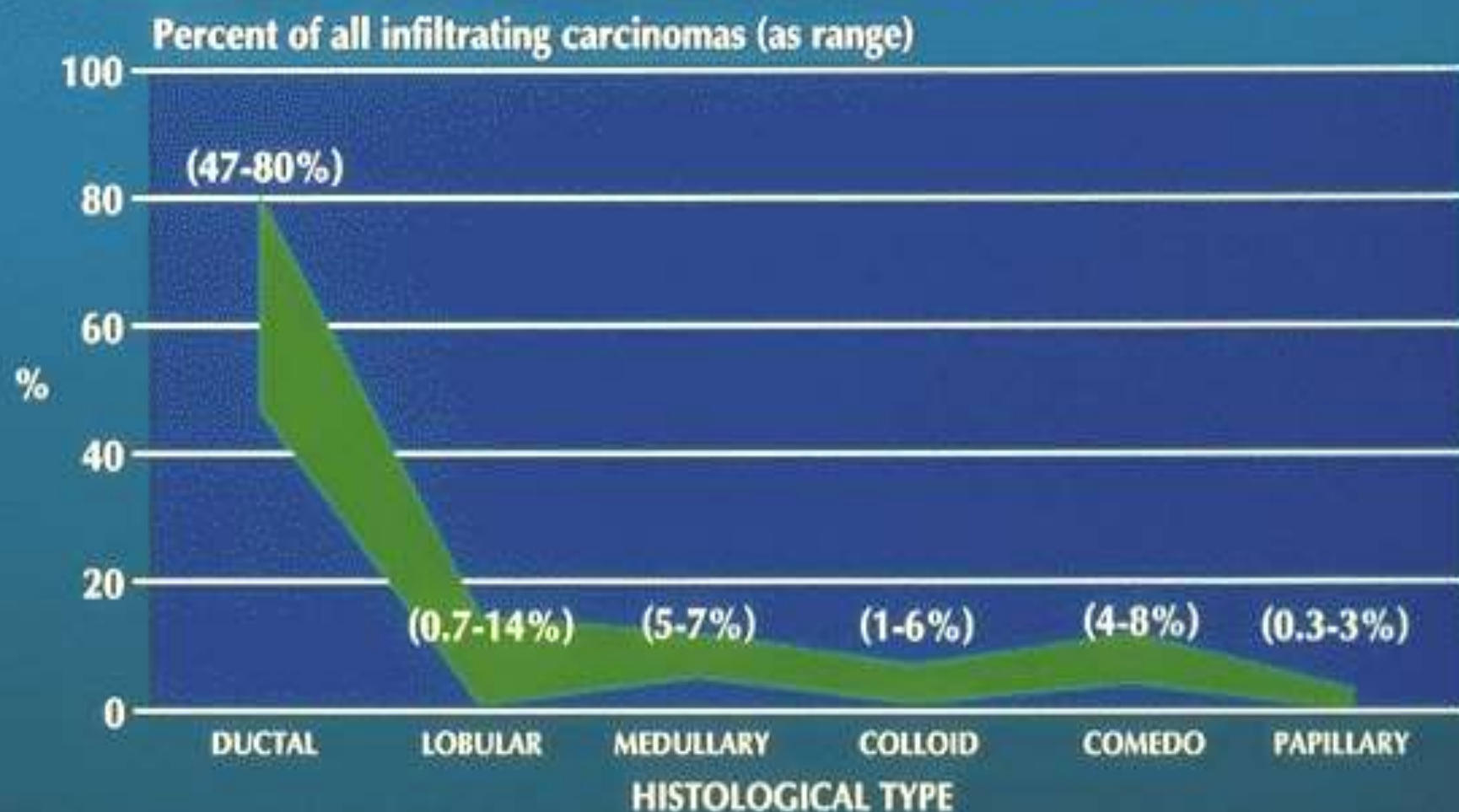


# Malignom na dojka



# BREAST CANCER

## INCIDENCE OF MAJOR HISTOLOGICAL TYPES



SOURCES: Adapted from Perez-Mesa CM. Gross and Microscopic Pathology (Chapter 12). In *Cancer of the Breast*, 4th edition, Donegan WL and Spratt JS, eds. WB Saunders, Philadelphia, 1995; and Donegan DL. Staging and Primary Treatment (Chapter 17). In *Cancer of the Breast*, 4th edition, Donegan WL and Spratt JS, eds. WB Saunders, Philadelphia, 1995.

# TNM

1. Goleminata na tumorot (T)

2. Histološka diferenciranost na tumorot (G)

3. Status na zafatenost na `lezdite (N)

4. Prisastvo na sistemski metastazi (M)

# TNM

## 1. Goleminata na tumorot (T)



**Tis** - tumor vo in situ forma

**T1** - tumor so golemina do 20 milimetri

**T2** - tumor so golemina od 21 do 50 milimetri.

**T3** - tumor so golemina pogolema od 50 milimetri

**T4** - tumor koj gi infiltrira okolnite strukturi.

## 4. Prisastvo na sistemski metastazi (M)

# TNM

1. Goleminata na tumorot (T)

2. Histološka diferenciranost na tumorot (G)

3. Status na zafatenost na limfno žlezdo (N)

G1- dobro diferencirani tumori

G2- sredno diferencirani tumori

4 G3- lošo diferencirani i

G4- anaplstični tumori.

**N0** - nema zafateni limfni jazli so metastaski depozit.

**N1** - zafateni se limfnite jazli vo istostranata aksilarna jama

**N2** - zafateni se limfnite jazli, vo ipsilateralната aksilarnata jama koja e fiksirana za okolnite strukturi.

**N3** - zafateni se parasternalnite ipsilateralni limfni jazli so metastaski depozit.

### 3. Status na zafatenost na limfnite (N)

### 4. Prisastvo na sistemski metastazi (M)

# TNM

**M0 - ne e doka`ano prisustvo na sistemski metastazi vo teloto.**

**M1 - doka`ano e prisustvo na sitemski metastazi vo teloto, pri {to vo zavisnost koj organi se zafateni se dodava oznaka na soodvetniot organ.**

**4. Prisastvo na sistemski|metastazi (M)**



# BREAST CANCER

## TNM STAGE GROUPING

Stage 0	Ti.s.	N0	M0
Stage I	T1	N0	M0
Stage II A	T0, T1	N1	M0
	T2	N0	M0
Stage II B	T2	N1	M0
	T3	N0	M0
Stage III A	T0, T1, T2	N2	M0
	T3	N1, N2	M0
Stage III B	Any T	N3	M0
	T4	Any N	M0
Stage IV	Any T	Any N	M1




# BREAST CANCER STAGE I DISEASE

T1 N0 M0

(T1)

T  $\leq$  2 cm



T1a : T  $\leq$  0.5 cm

T1b : 0.5 cm < T  $\leq$  1 cm

T1c : 1 cm < T  $\leq$  2 cm

N0 = no regional lymph node metastasis

# BREAST CANCER

## STAGE II A DISEASE

T0  
T1 } N1 M0

T2 N0 M0

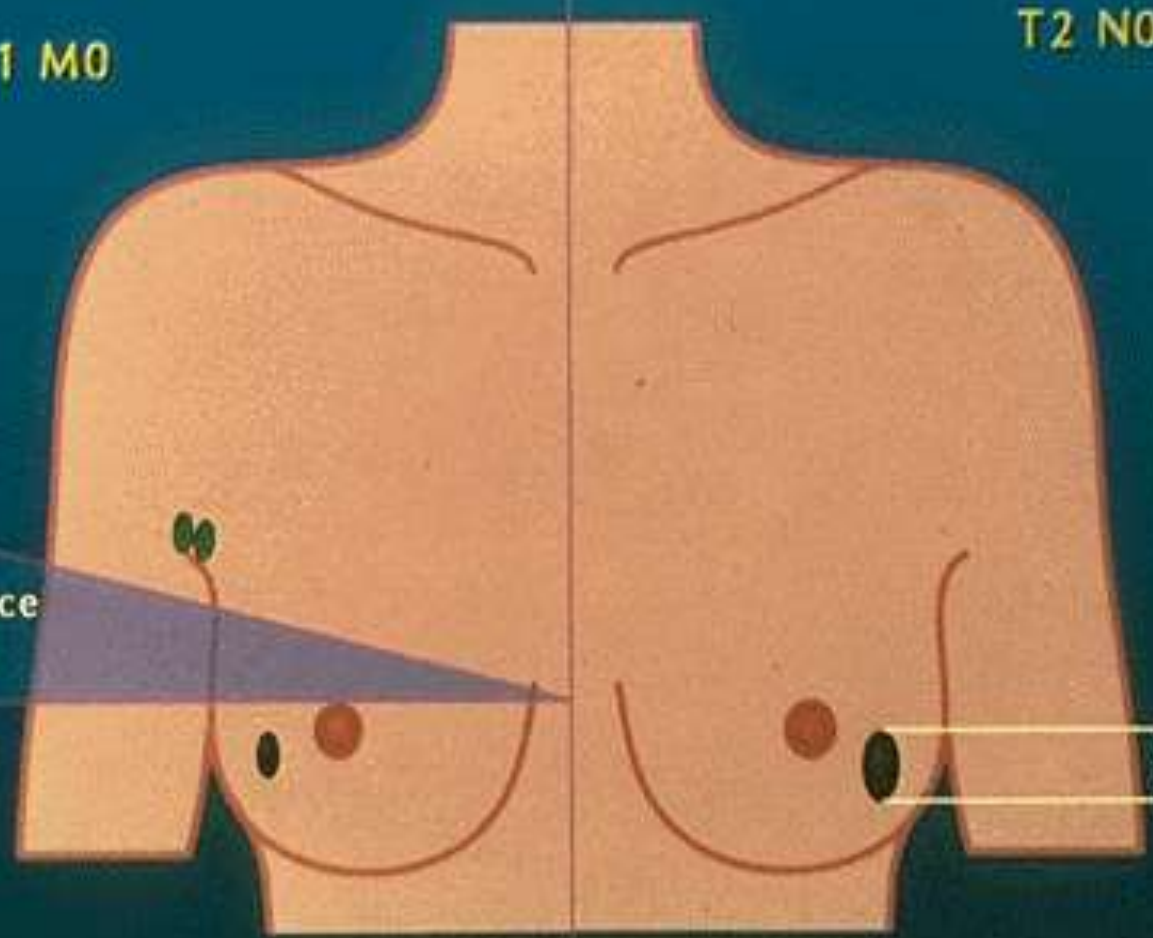
T0 No evidence of tumor

T1  $T \leq 2$  cm

T2

$2 \text{ cm} < T \leq 5 \text{ cm}$

N1 = metastasis to movable ipsilateral axillary lymph node(s)

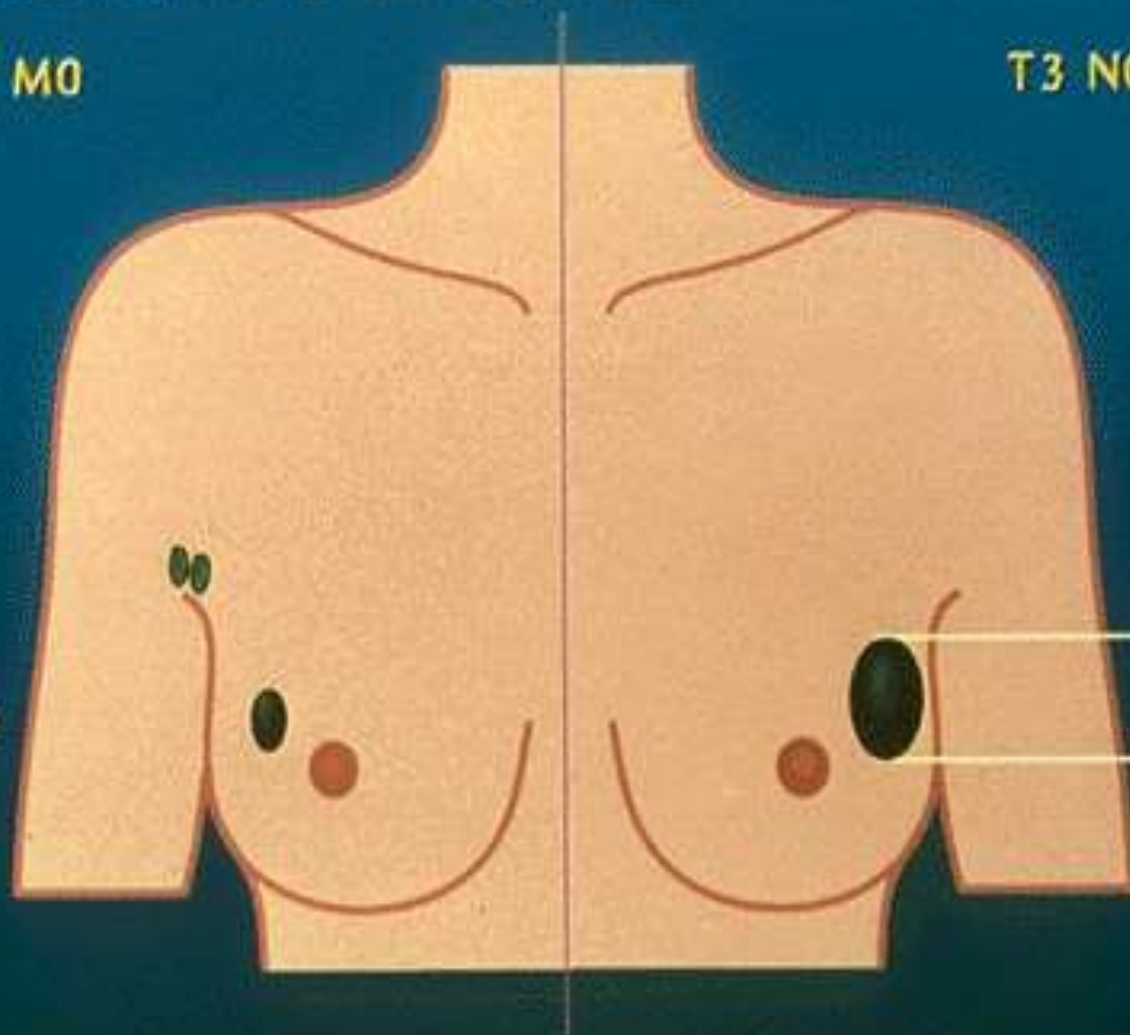


# BREAST CANCER STAGE II B DISEASE

T2 N1 M0

T3 N0 M0

(T2)  
 $2 \text{ cm} < T \leq 5 \text{ cm}$



(T3)  
 $T > 5 \text{ cm}$

N1 = metastasis to movable ipsilateral axillary lymph node(s)  
(p) N1a, N1b

# BREAST CANCER

## STAGE III A DISEASE

T3 N1 M0

T0  
T1  
T2  
T3 } N2 M0

T0

No evidence of primary tumor

T1

$T \leq 2$  cm

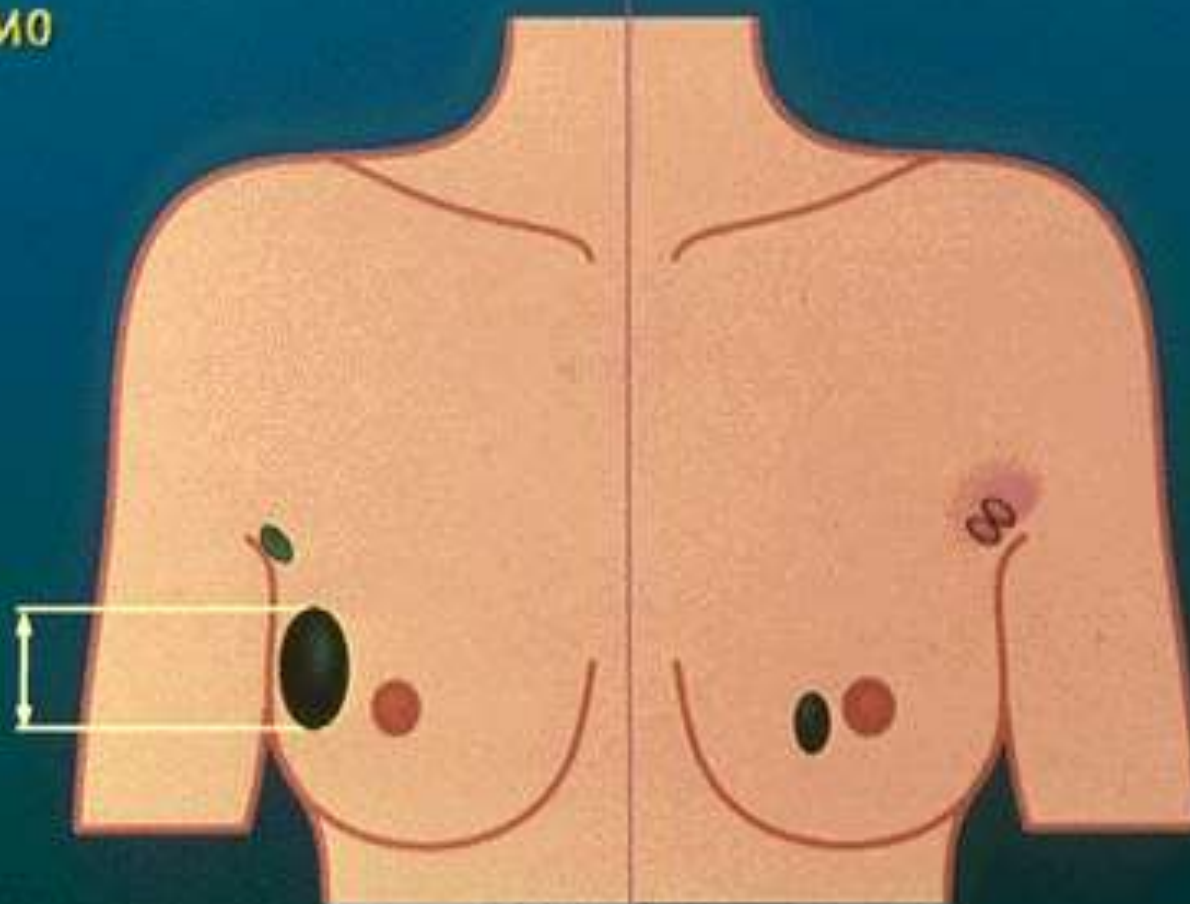
T2

$2 \text{ cm} < T \leq 5 \text{ cm}$

T3

$T > 5 \text{ cm}$

T3  
 $T > 5 \text{ cm}$



Metastasis to ipsilateral axillary lymph node(s)

N1 = movable

N2 = fixed to one another or to other structures

# BREAST CANCER STAGE III B DISEASE

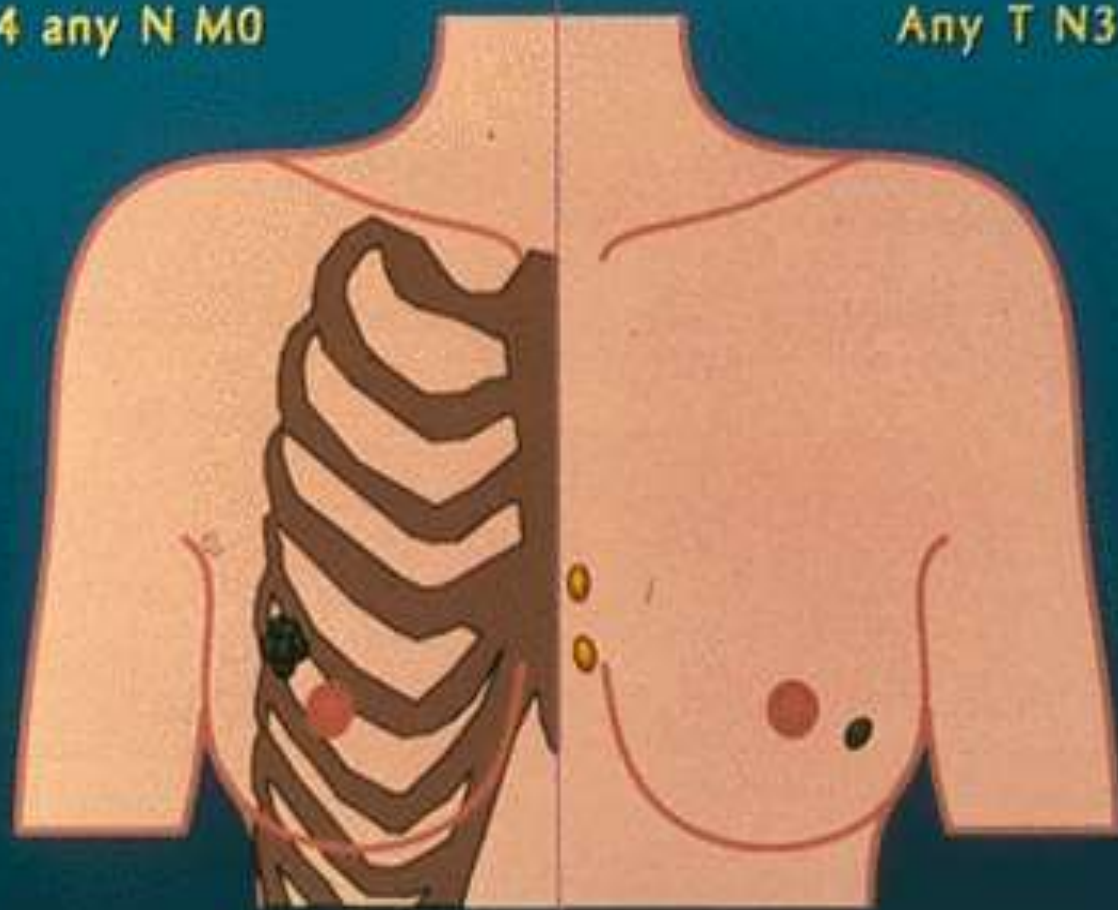
T4 any N M0

Any T N3 M0

T4

Tumor of any size  
with direct extension  
to chest wall or skin

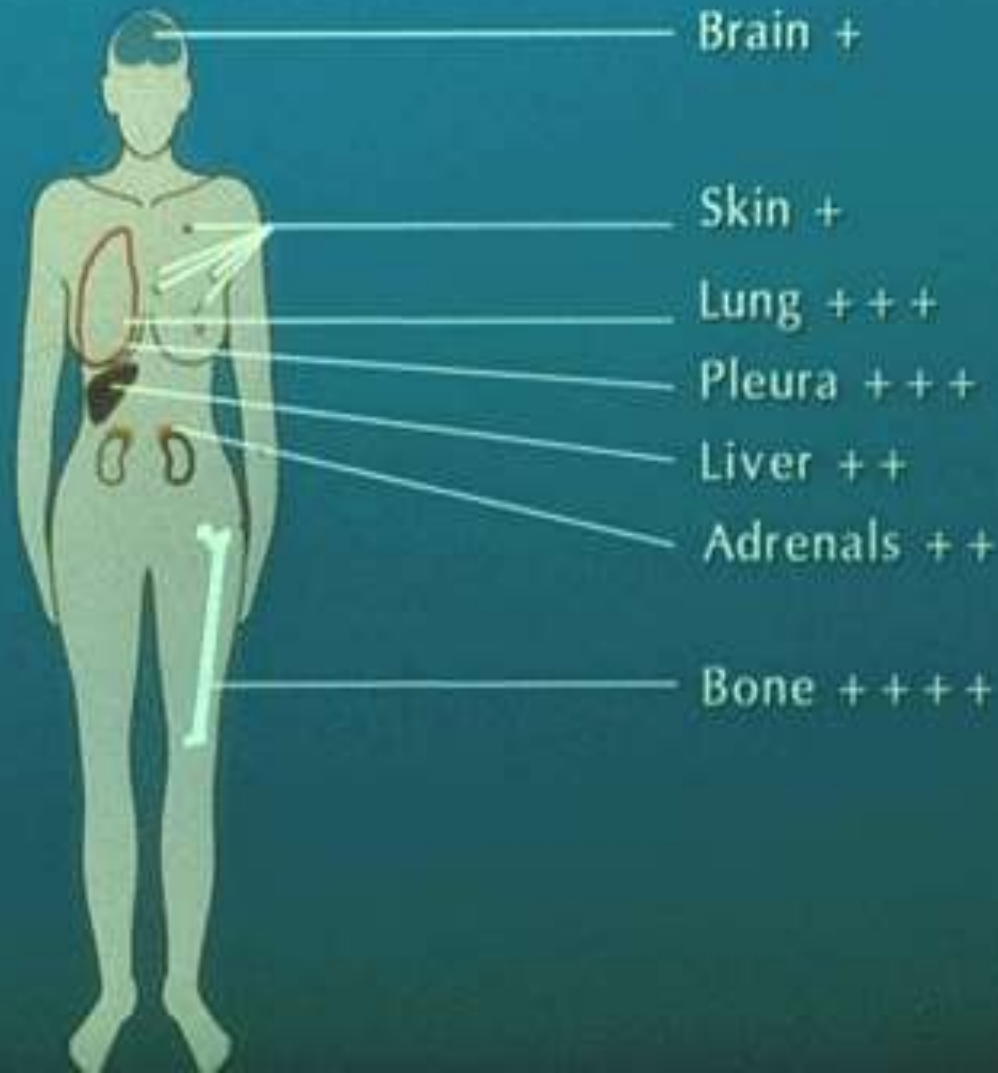
T4 d = inflammatory  
carcinoma



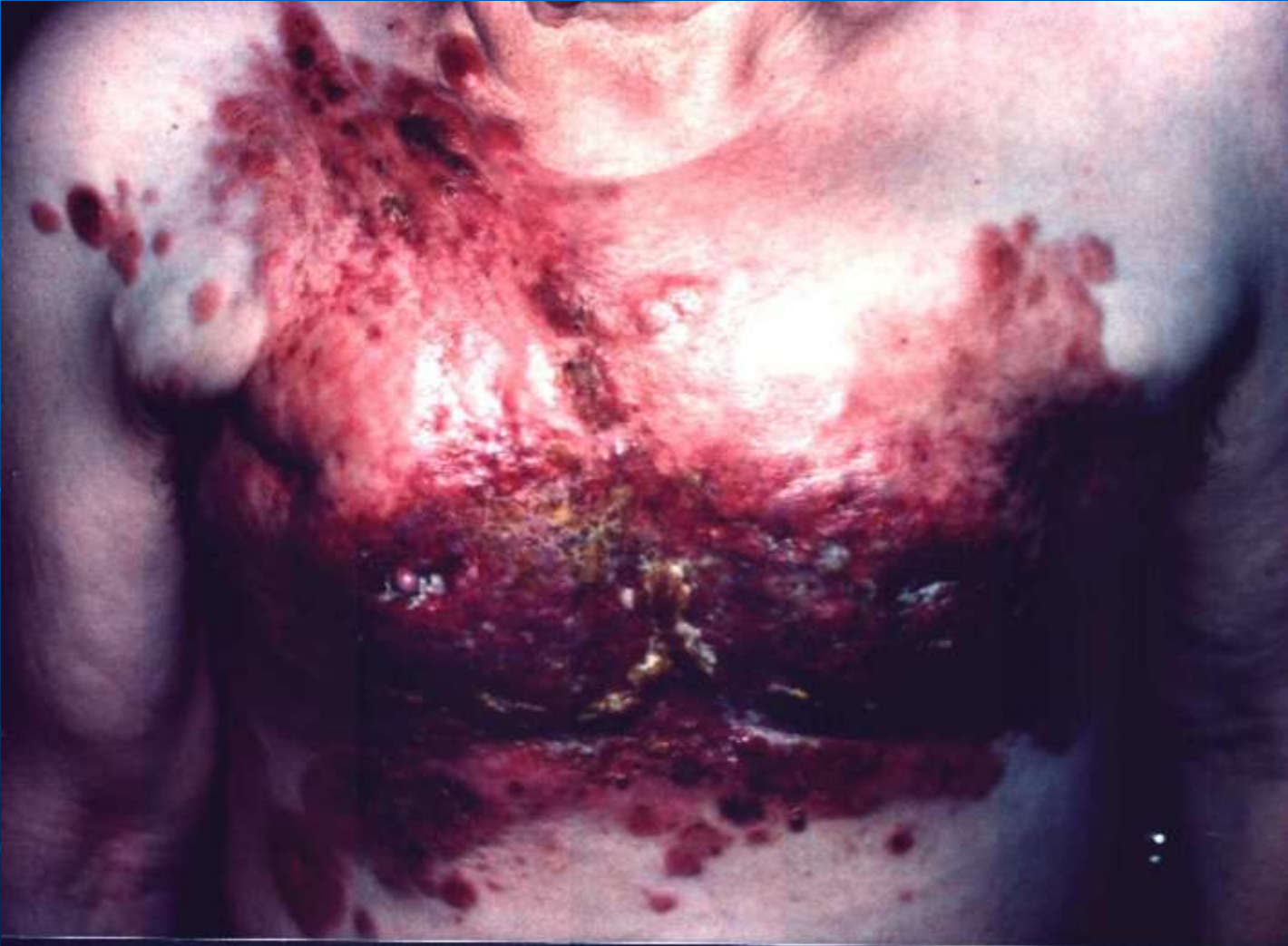● N3 = metastasis to ipsilateral internal mammary lymph node(s)

# BREAST CANCER DISTAL SPREAD

## STAGE IV



Vo koj klini~ki stadium se nao|a  
pacientkata??



# PRIMARY BREAST CANCER

## GOOD PROGNOSTIC FACTORS

Patient's age :	older than 50 years
Axillary nodes :	not involved
Size of tumor :	small (< 1 cm)
Local extension of tumor :	absent
Histologic examination :	well differentiated tumor (grade I)
Cytologic study :	little atypia of nuclei (grade I)
Estrogen Progesterone ] receptors :	positive (ER + and PR +)
Oncogene amplification :	absent



# PRIMARY BREAST CANCER

## POOR PROGNOSTIC FACTORS

Patient's age:	< 40 years
Axillary nodes:	involved
Size of tumor:	large (> 5 cm)
Local extension of tumor:	present
Histologic examination:	anaplastic tumor (grade III)
Cytologic study:	severe atypia of nuclei (grade III)
Estrogen Progesterone ] receptors:	negative (ER - and PR -)
c-erbB-2 oncogene product:	overexpressed
Cathepsin D protease:	overexpressed

**TERAPIJA NA  
MALIGNOMOT NA  
DOJKATA**

# SAMOPREGLED NA DOJKA

Nad 20 godini starost

- sekoj mesec

# KLINI^KI PREGLED NA DOJKA

Od 20 do 39 godini starost -edna{ na 3 god.

Posle 40 godini starost -edna{ godi{no

# MAMOGRAFIJA- *skrining*

Od 40 do 49 godini starost - na 1 do 2 godini

Posle 50 godini starost - na 1 godina

*Ameri~ka asocijacija za  
borba protiv rakot*

# TERAPIJA NA MALIGNOMOT NA DOJKATA

## Lokoregionalna

- Hirurška terapija
- Zračna terapija

## Sistemska

- Hemioterapija
- Hormonoterapija
- Imunoterapija

# HIRUR[KI TRETMAN NA MALIGNOMOT NA DOJKATA

- Cel - lokoregionalna kontrola.
- Odstrani tumorot i limfnite jazli vo aksila.

## Hirurgija na dojakata

- Mastektomija
- Parcijalna mastektomija
- Kvadarantektomija
- Segmentektomija
- Limpektomija
- Tumorektomija

## Hirurgija na aksilarnata jama

- $\emptyset$
- biopsija
- parcijalna limfadenektomija
- kompletna limfadenektomija

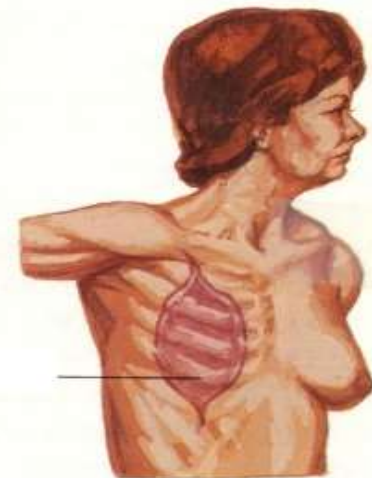
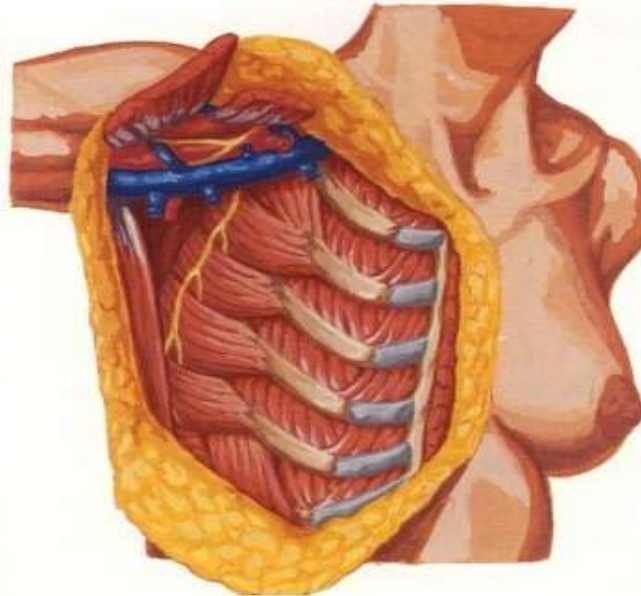
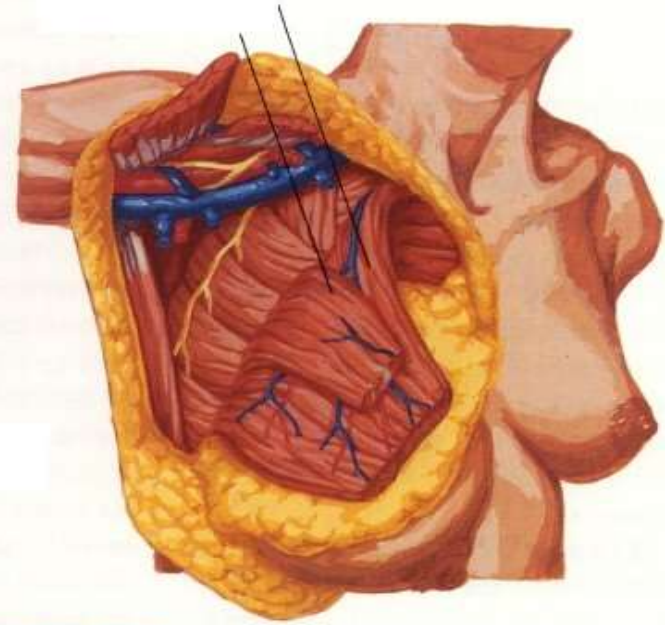
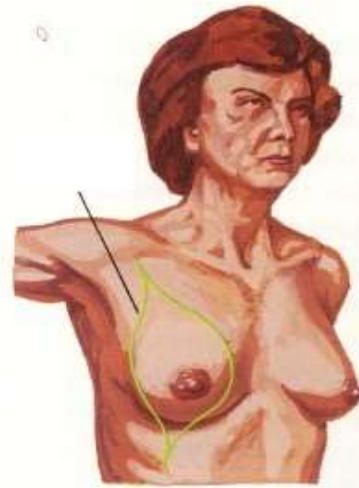# Halsted 1893



# Halsted 1893

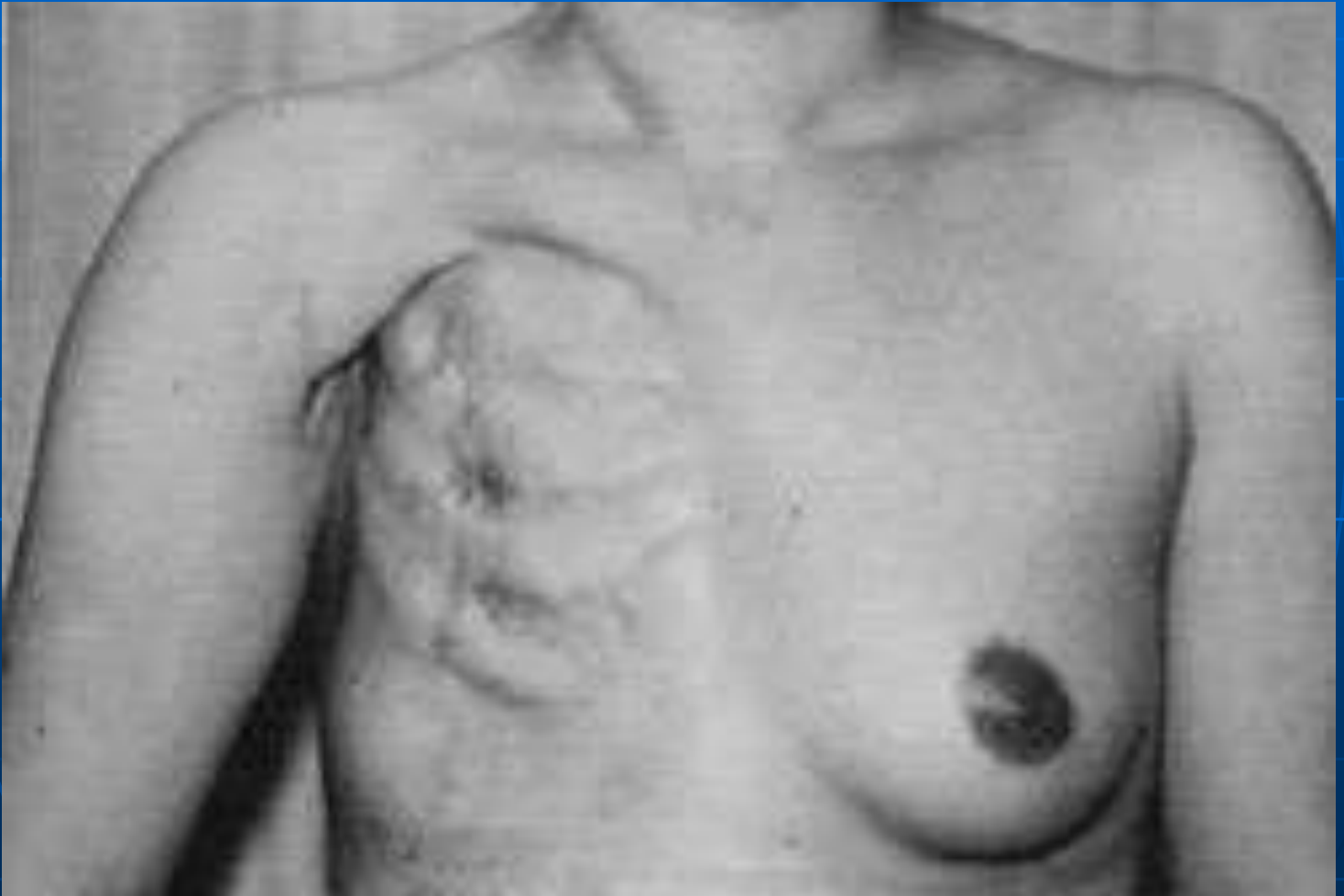- **Odstranuvawe na dojkata**
- **Odstranuvawe na golemiot pektoralen muskul**
- **Odstranuvawe na maliot pektoralen muskul**
- **Odstranuvawe na aksilarnite limfni jazli**

# Hals





# Halsted 1893



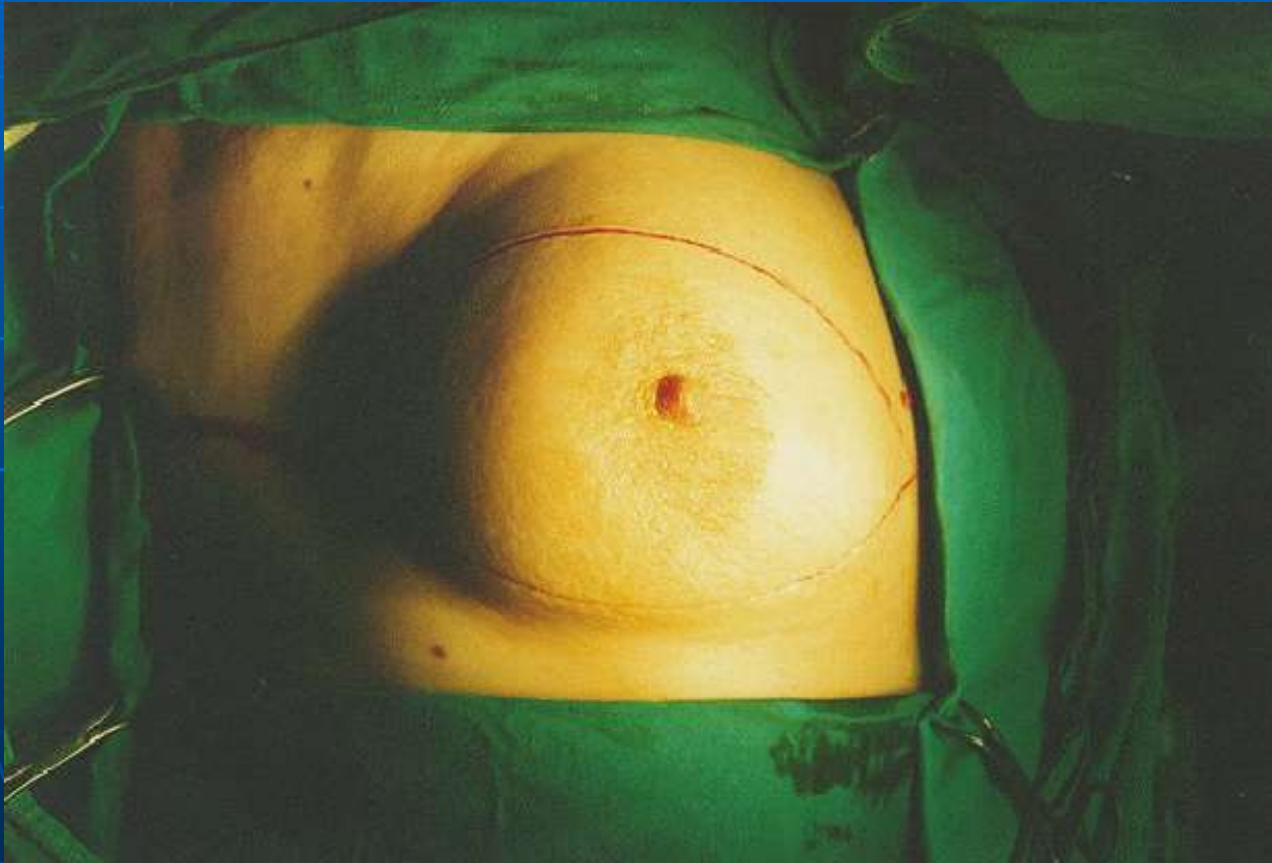# Patey DH. Dyson WH.- 1948

- **Odstranuvawe na dojkata**
- **Odstranuvawe na maliot pektoralen muskul**
- **Odstranuvawe na aksilarnite limfni jazli**

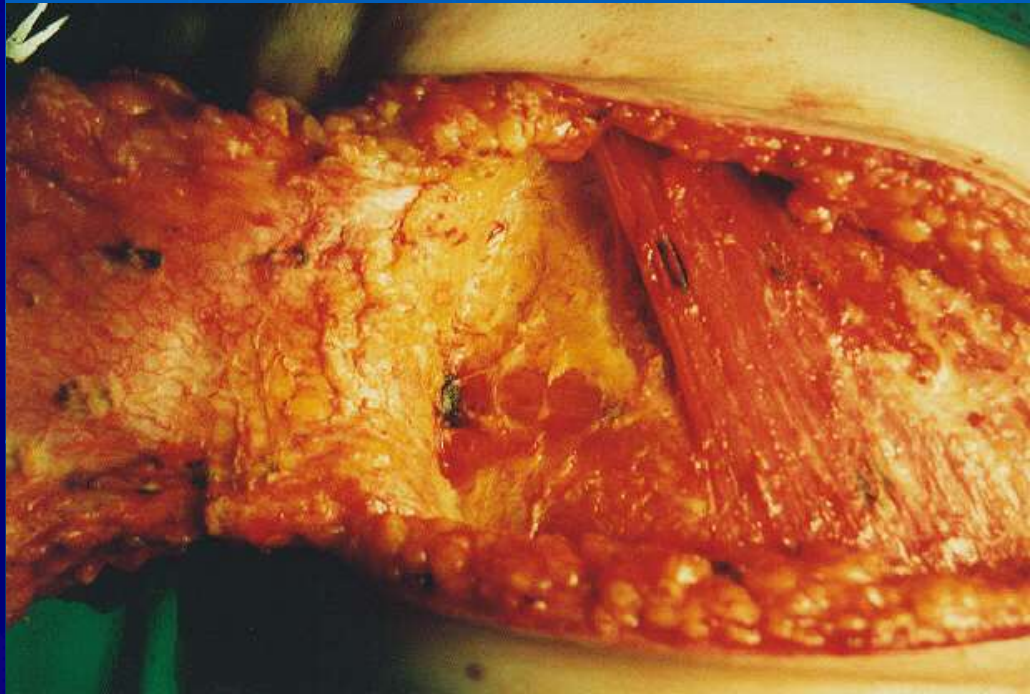
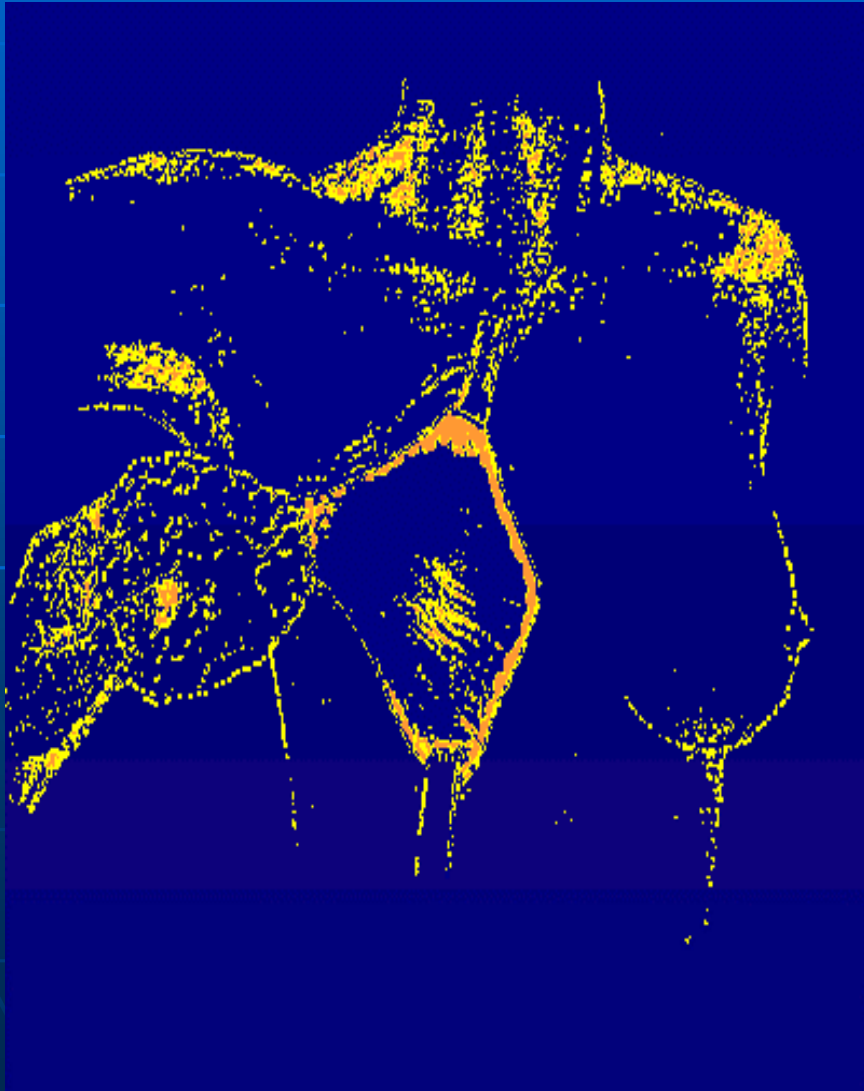
# Madden JL. 1965

- **Odstranuvawe na dojkata**
- **Odstranuvawe na aksilarnite limfni jazli**

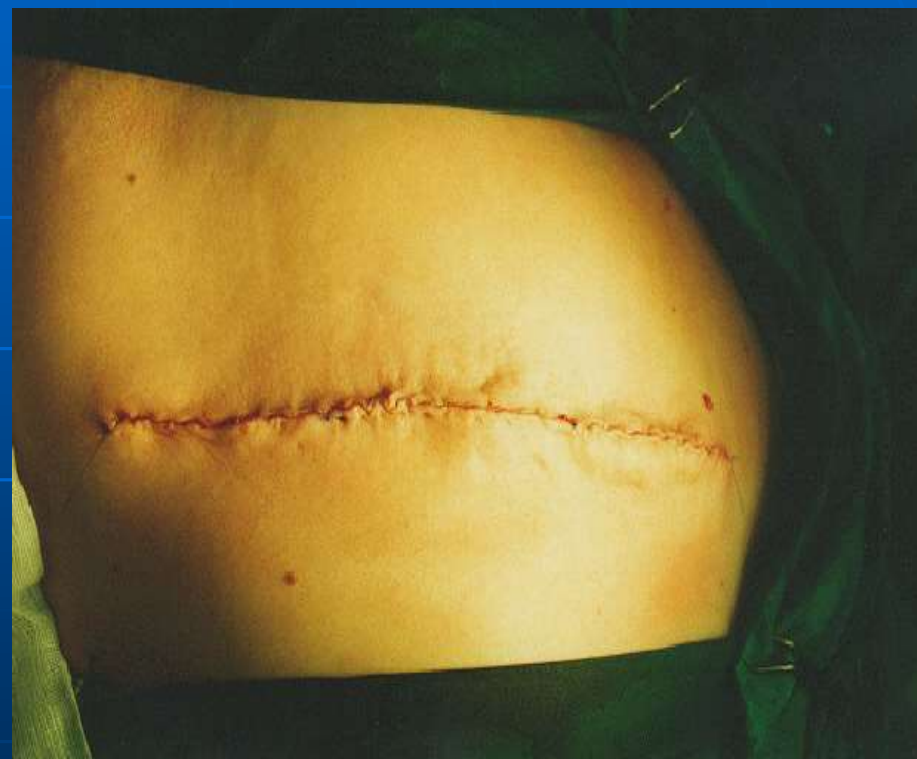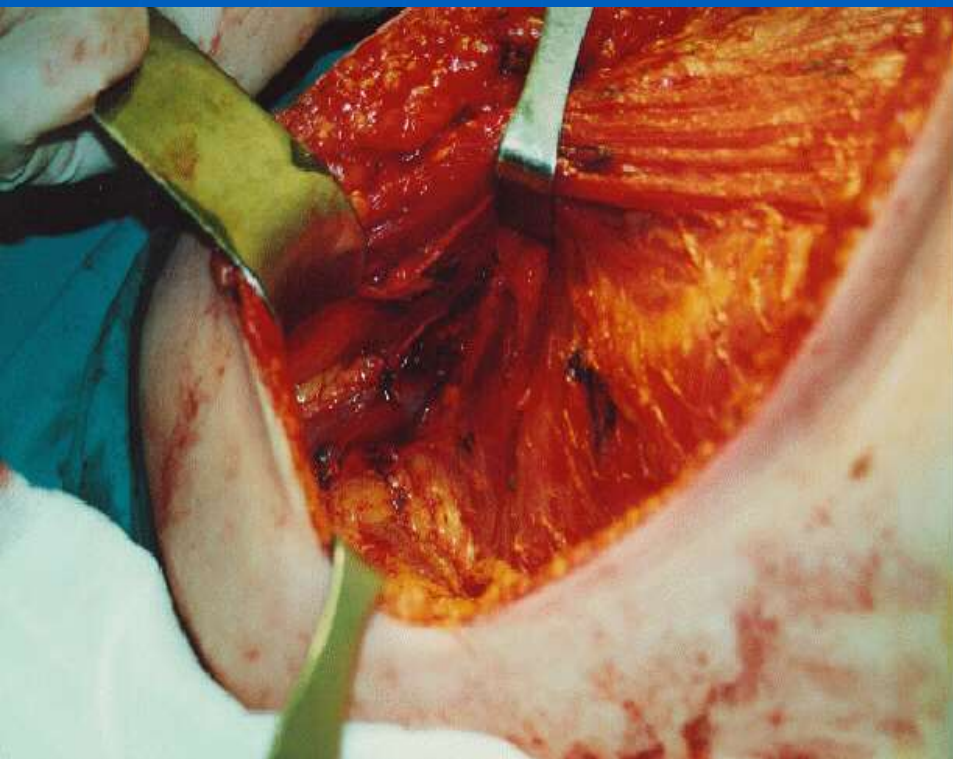
# Modificirana radikalna mastektomija sec. Madden



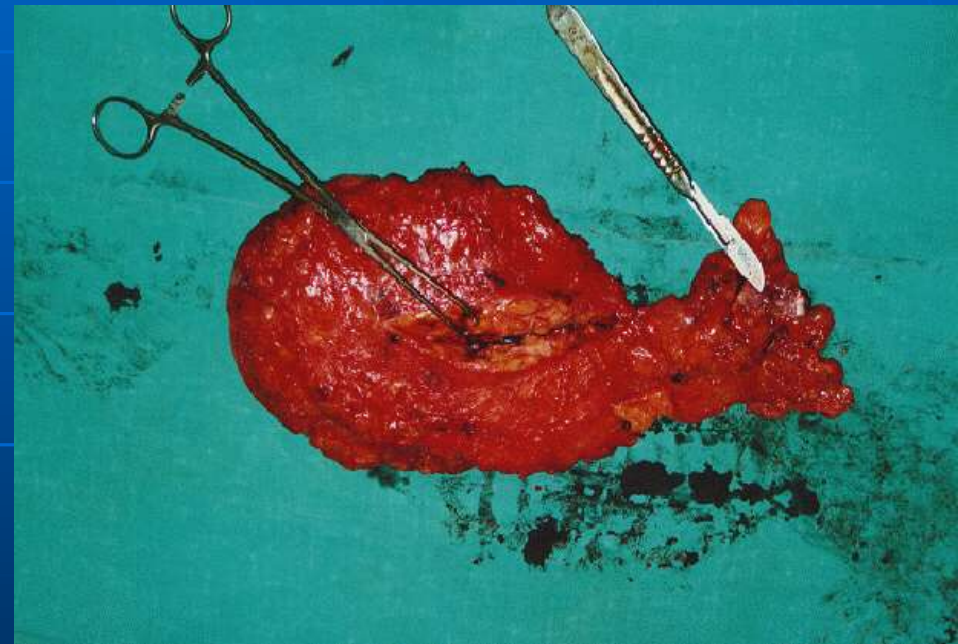
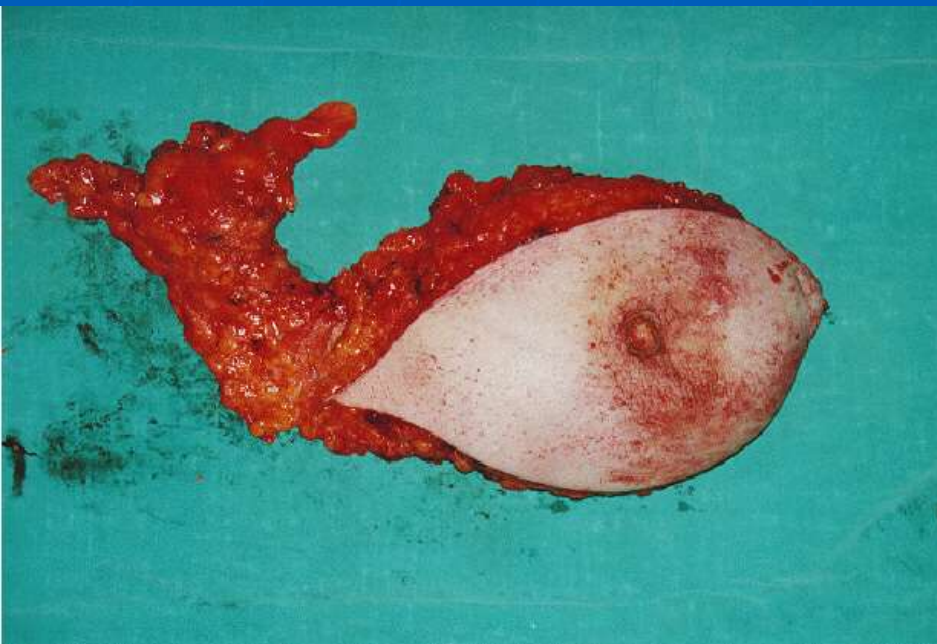
# Modificirana radikalna mastektomija sec. Madden



# Modificirana radikalna mastektomija sec. Madden



# Modificirana radikalna mastektomija sec. Madden







# Fisher B. 1977

Lumpectomy cum axilar  
limphadenectomy

- **Odstranuvawe na tumor vo zdravo**
- **Odstranuvawe na aksilarnite limfni jazli**


# Veronesi U. 1981

Quadrantectomy cum axilar  
limphadenectomy

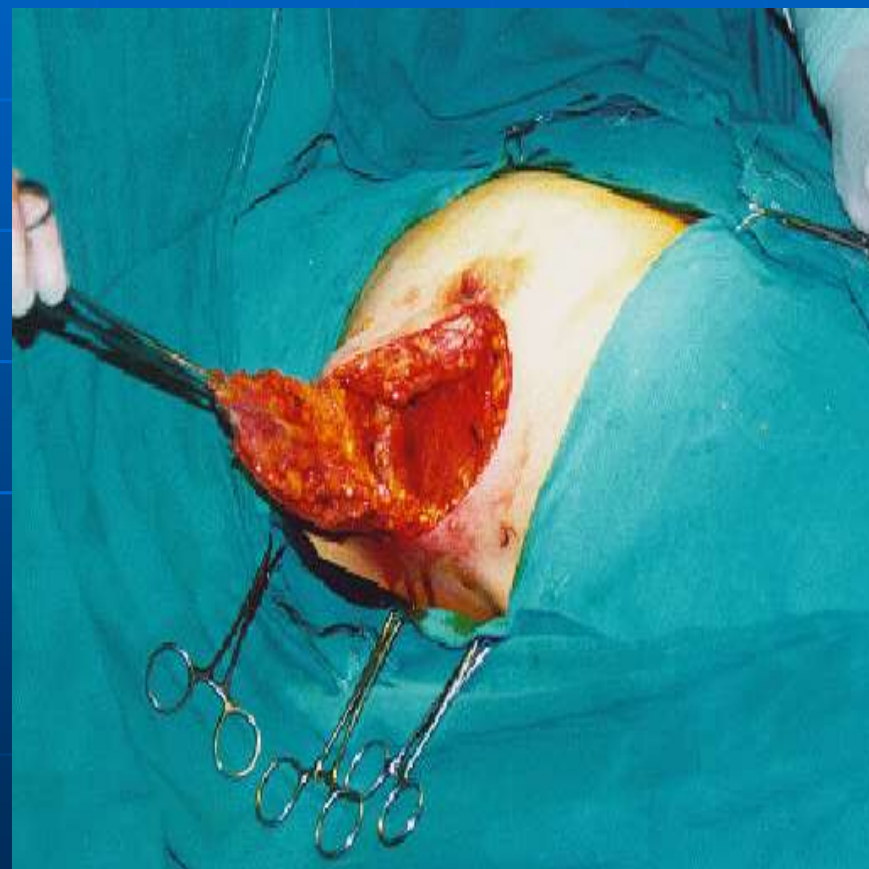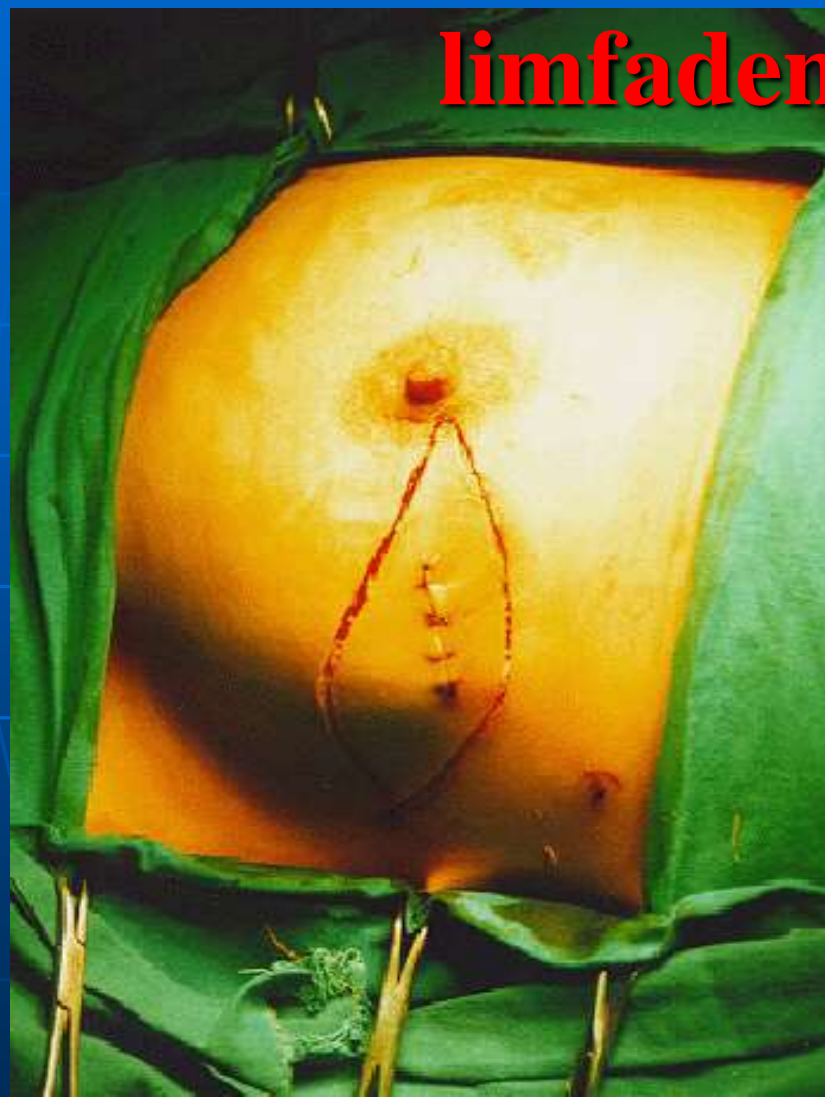- **Odstranuvawe na del od dojka kade e tumor so okolno zdravo tkivo ( 3 cm)**
- **Odstranuvawe na aksilarnite limfni jazli**

# Veronesi U. 1981

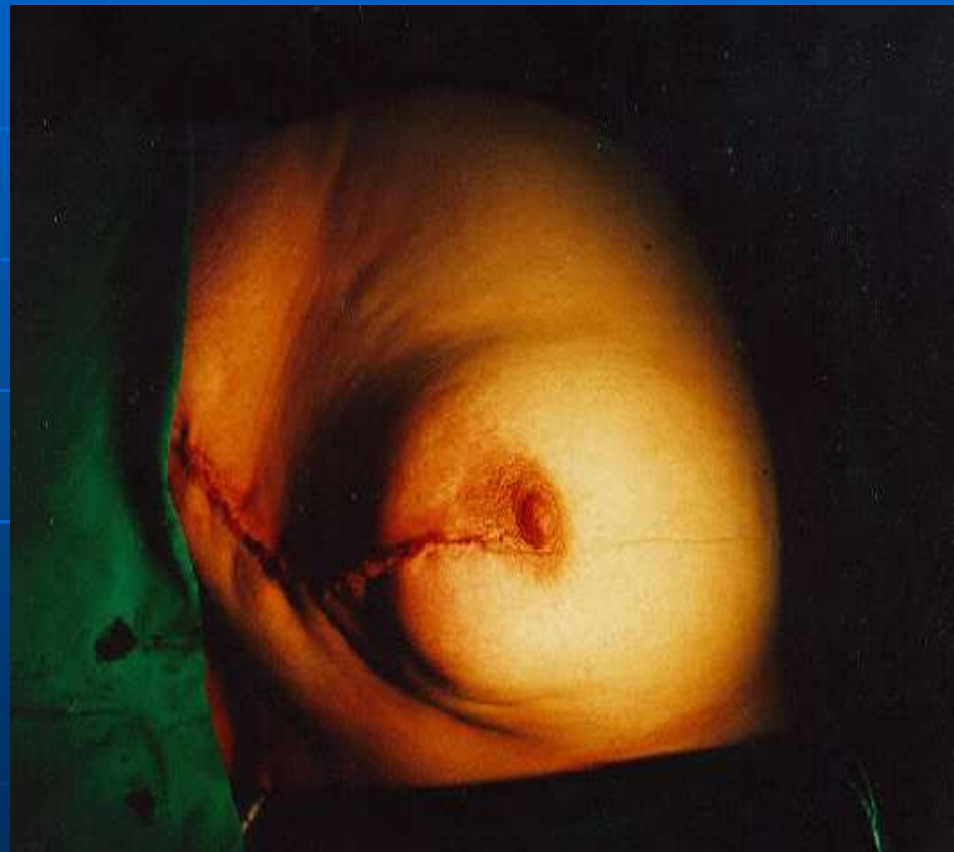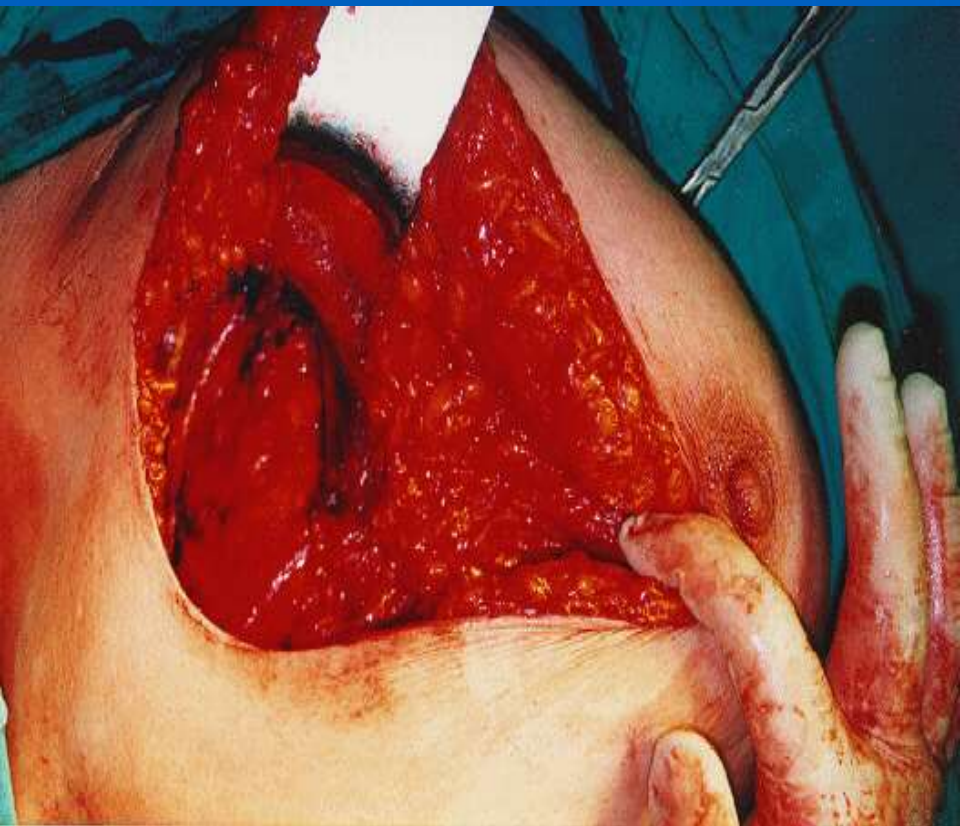
## Quadrantectomy cum axilar limphadenectomy



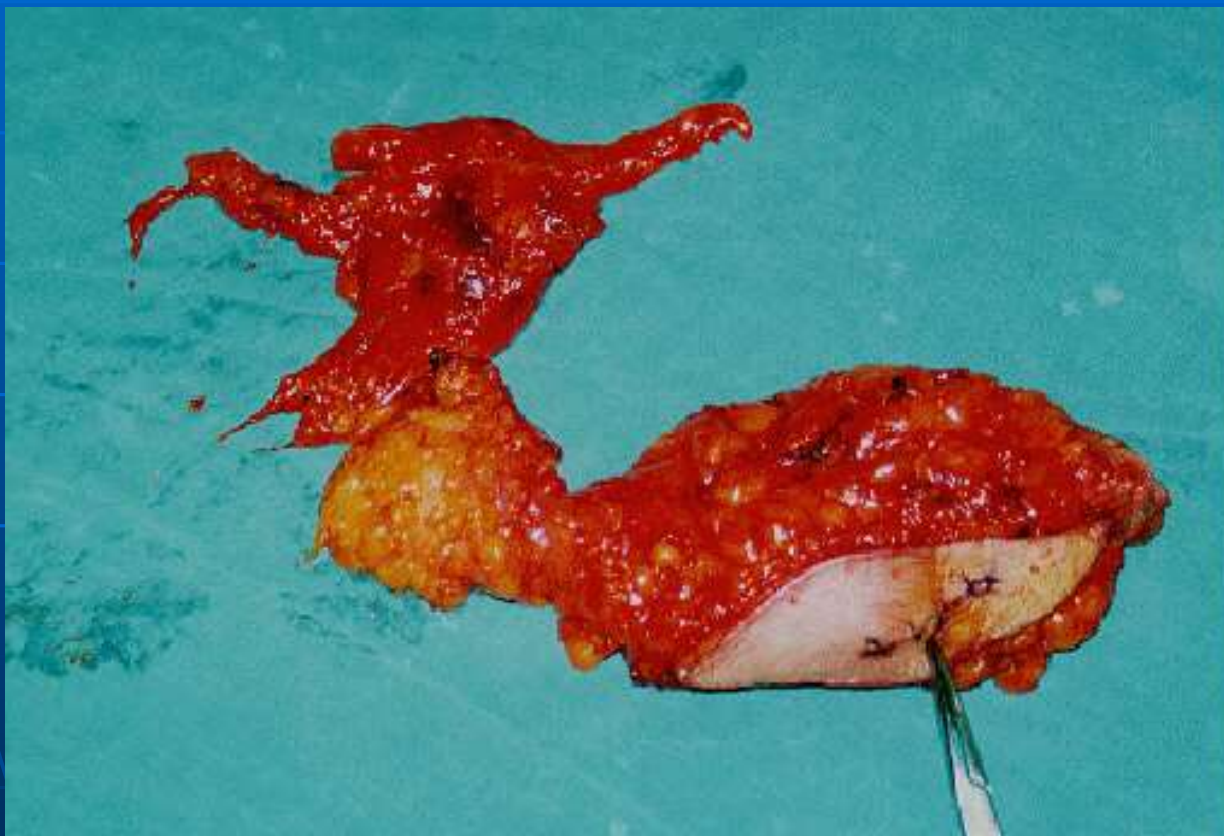
# Kvadarantektomija so aksilarna limfadenektomija



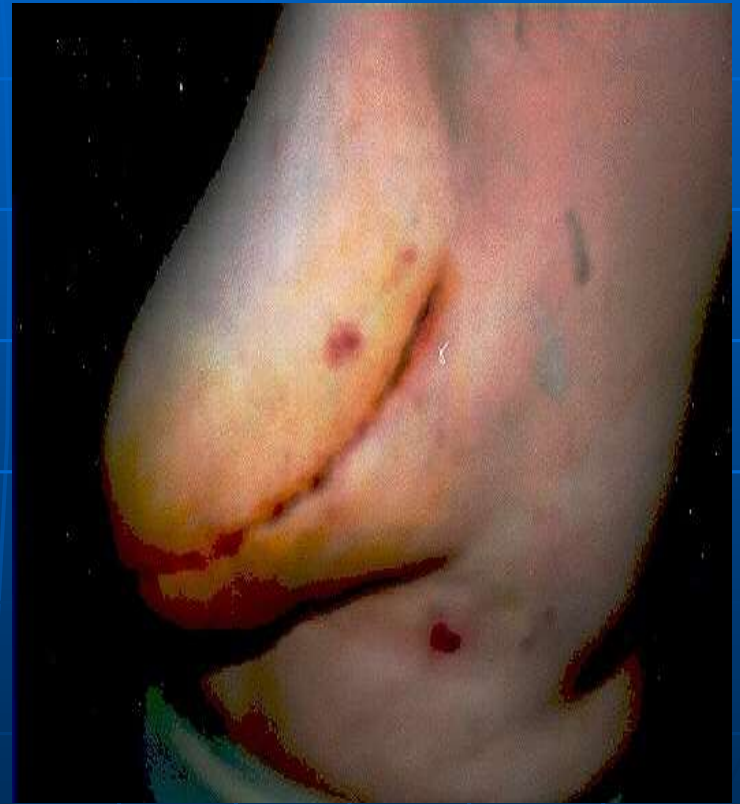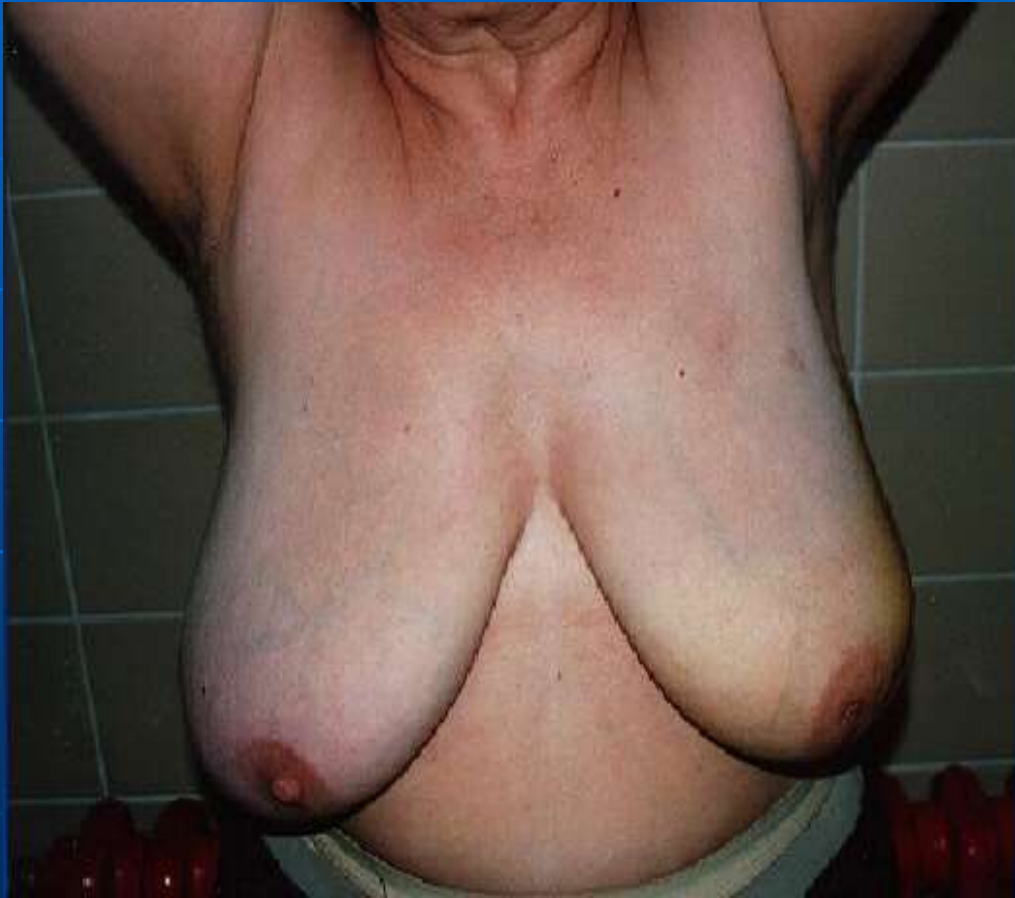# **Kvadarantektomija so aksilarna limfadenektomija**



# **Kvadarantektomija so aksilarna limfadenektomija**



# Kvadrantektomija so aksilarna limfadenektomija







**Ako TU e do 5cm**

**nema kontrai ndi kaci i**

**za kvadrant ekt omi ja**

**( I i II stadi umod**

**kl i ni ~ki TNM)**



**radi kal na mast ekt omi ja**

**+/- rekonst r ukc i ja na dojka**

**Ako TU e > od 5 cm.**

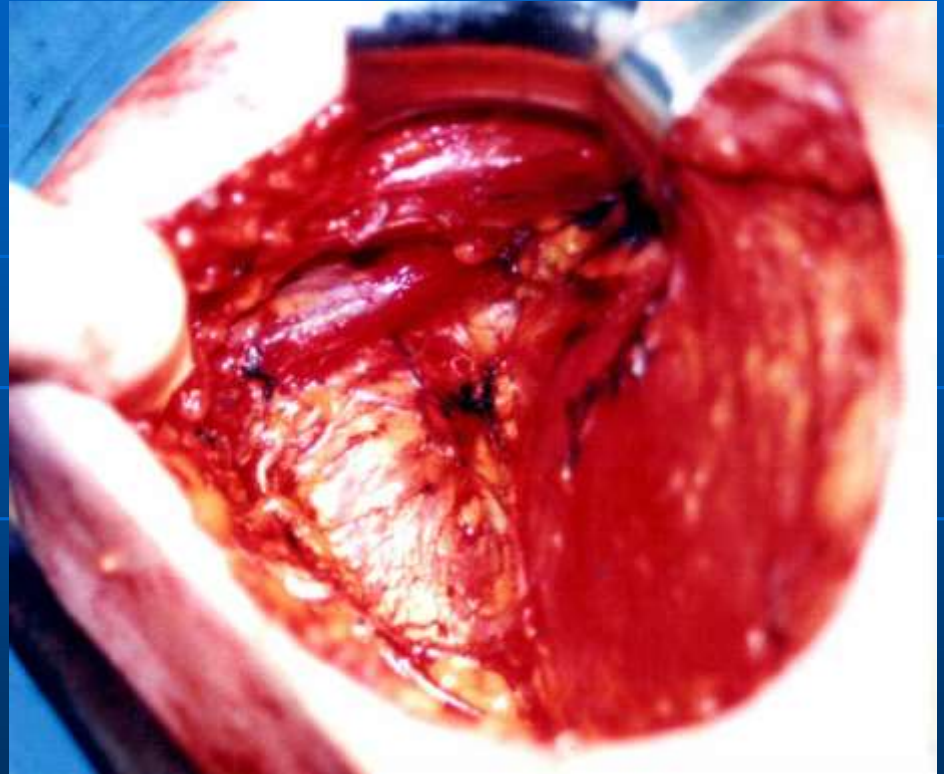
**neoadjuvant na t er api ja**

**(hemi ot er api ja 1-4 ci kl usa)**

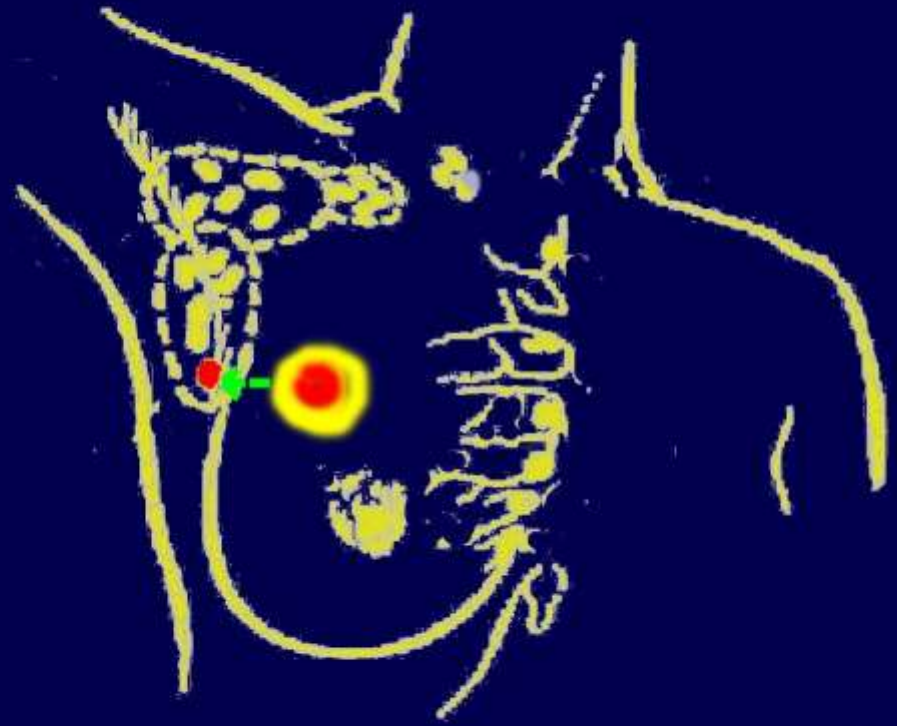
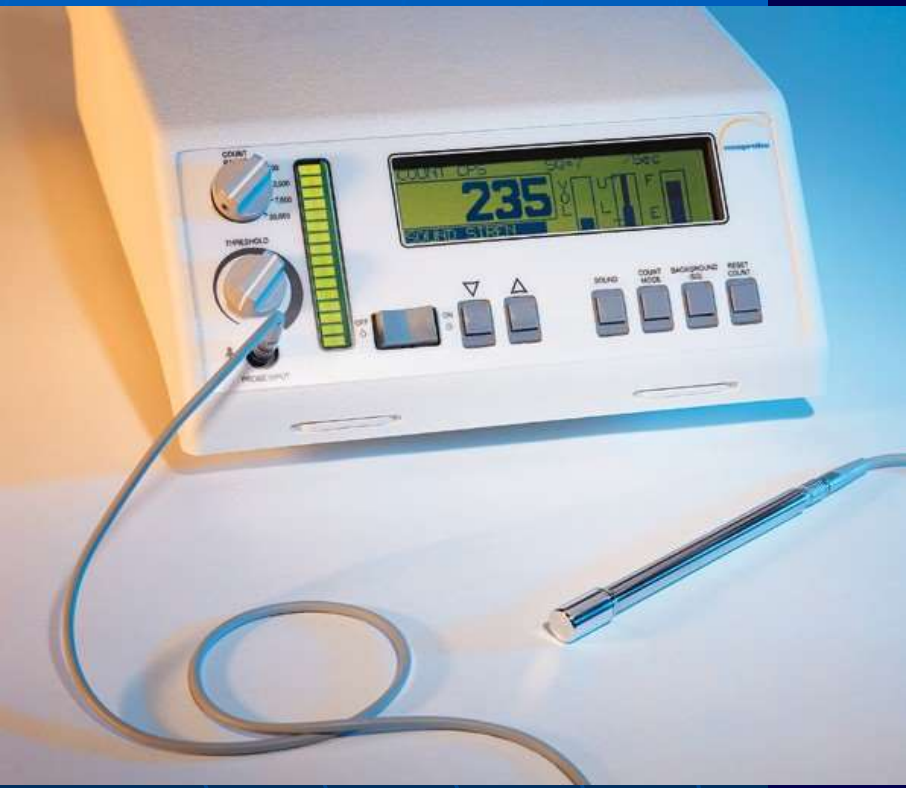
**QUAD - kvadrant ekt omi ja so aksi l ar na l i m f adenekt omi ja .**

# HIRURGIJA NA PAZUVNATA JAMA

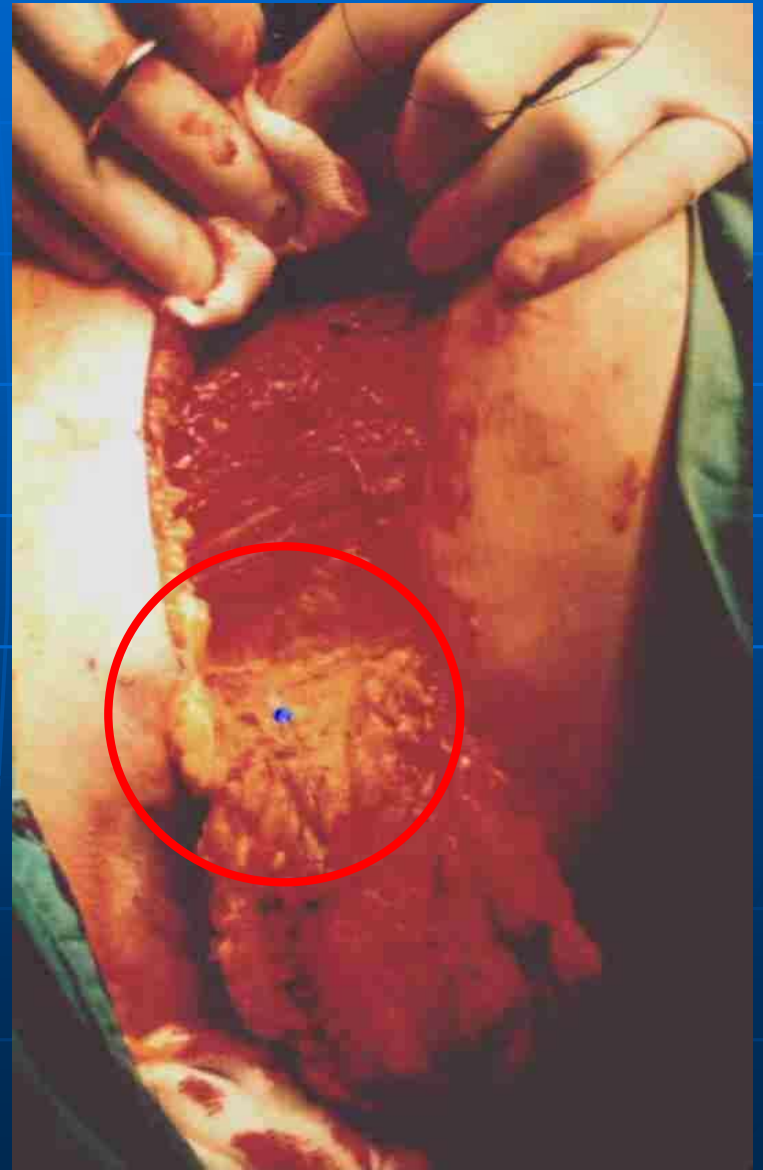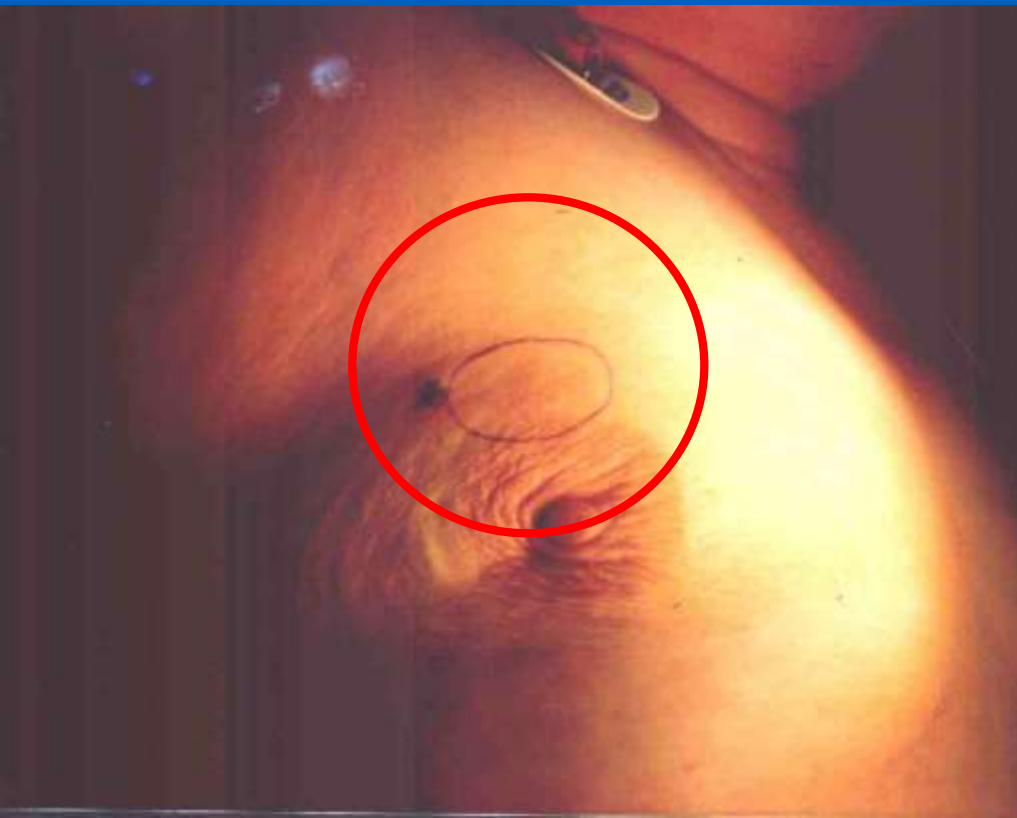# Aksilarna limfadenektomija



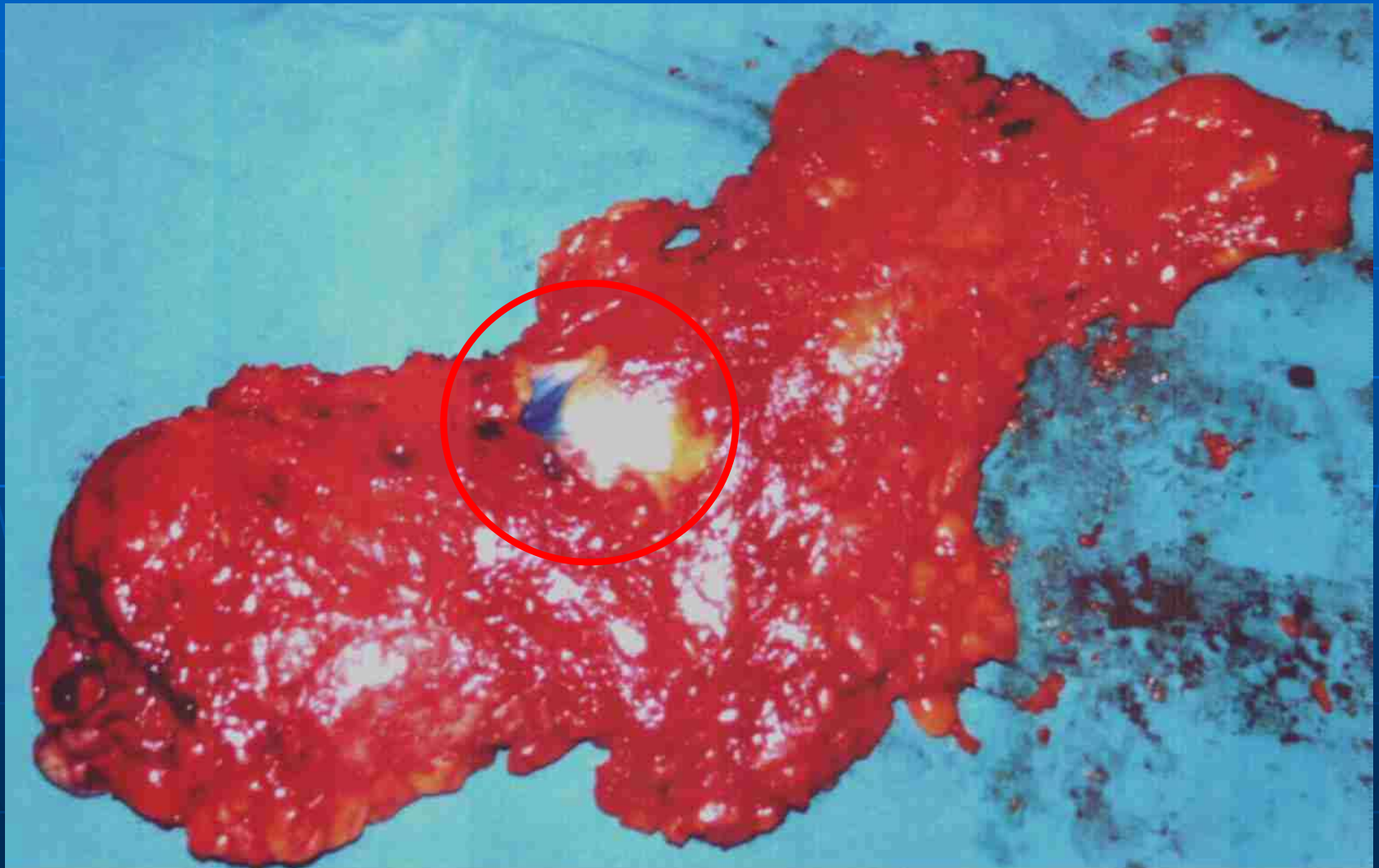
# “Sentinel Lynd”-“Stra`ar”

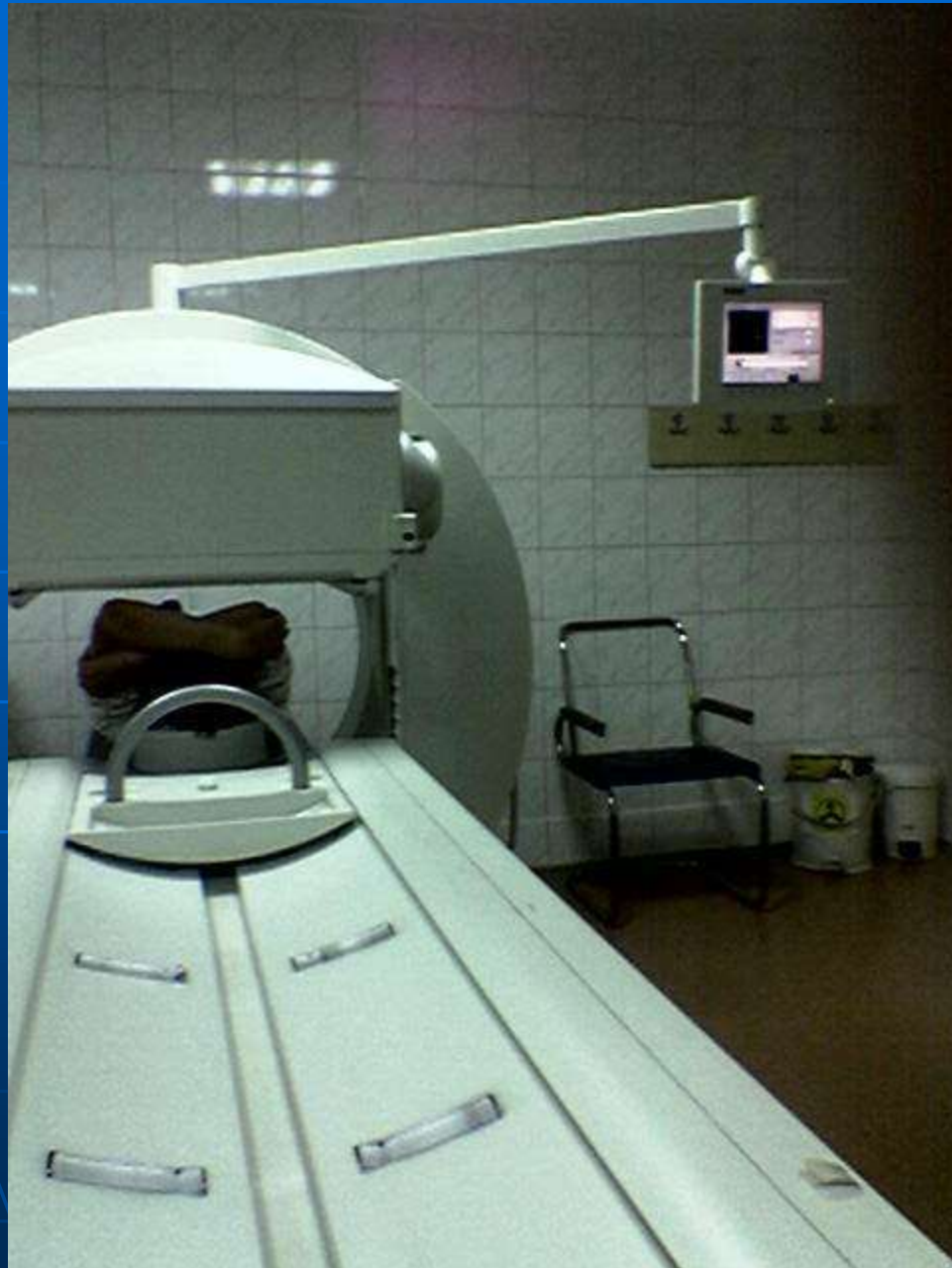

# “Sentinel Lymph Node” - “Sentinel Node”




# “Sentinel Lynd”-“Stra`ar”













120min-AP 229K




120min-oblikvi 225K



120min-lateralno 223K



60min-AP 263K



60min-oblikvi 258K



60min-lateralno 249K




30min-AP 288K



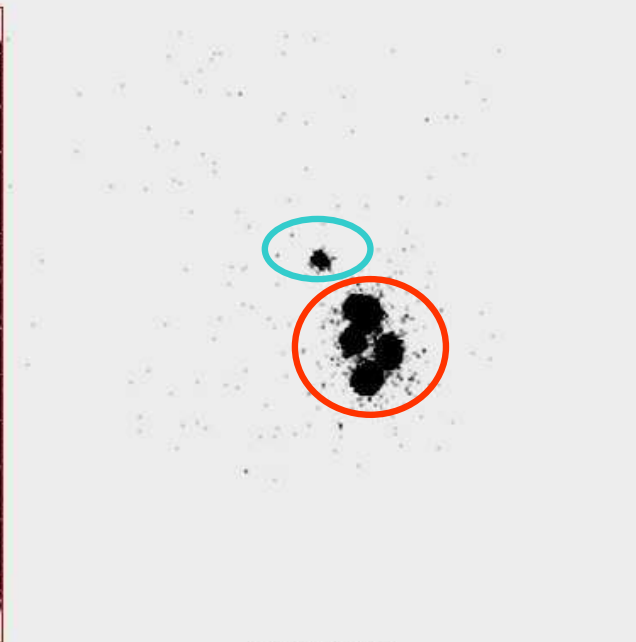
30min-oblikvi 282K




30min-lateralno 274K



17h-lateralno-Co 101K



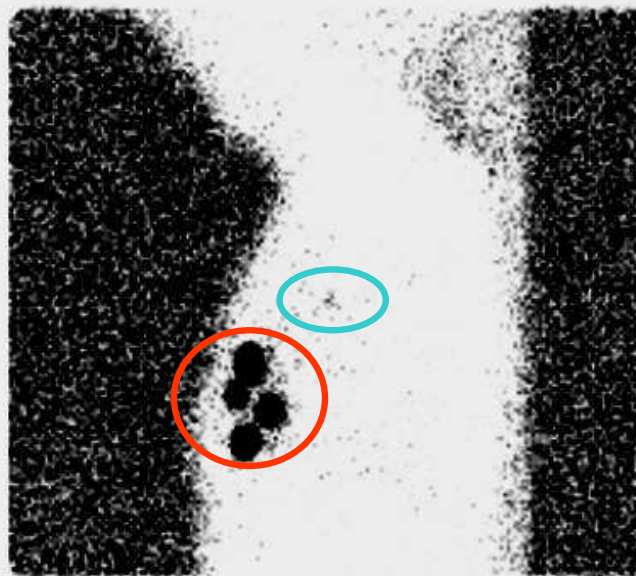
17h-AP 47K



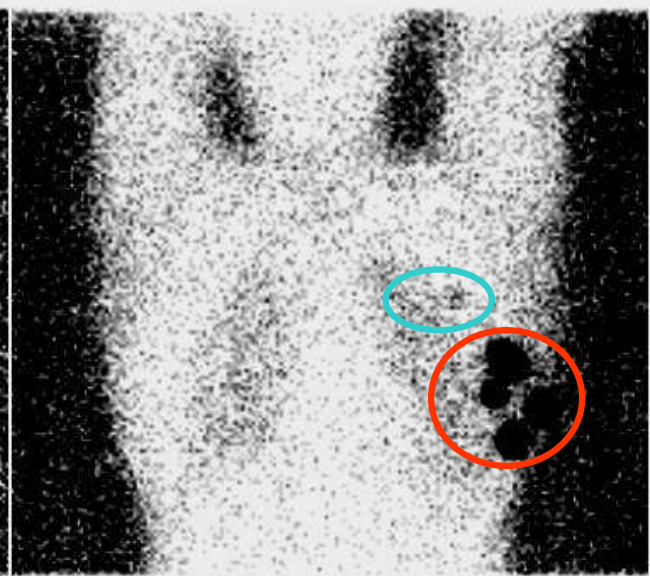
17h-oblikvi 47K



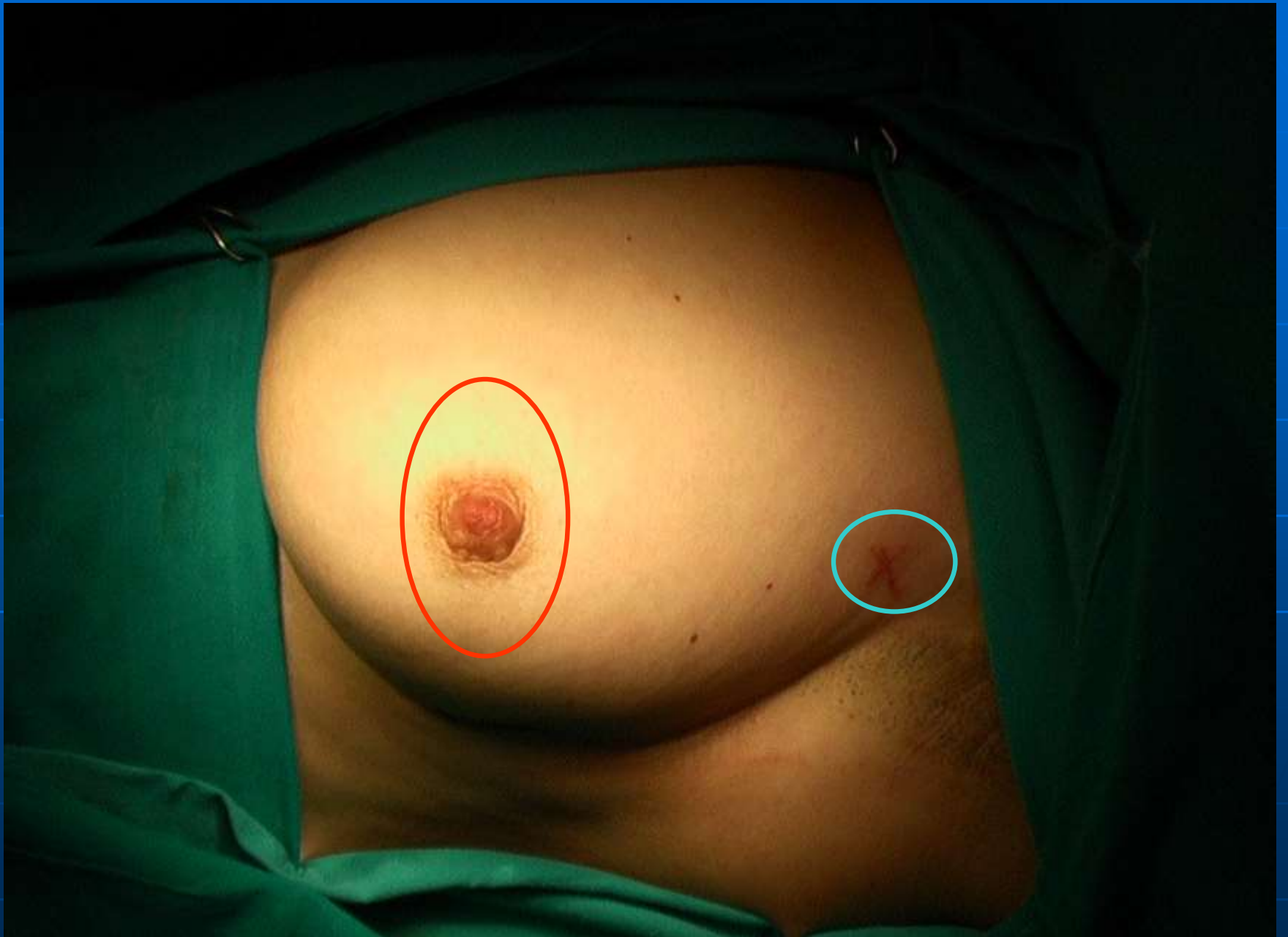
17h-lateralno 47K

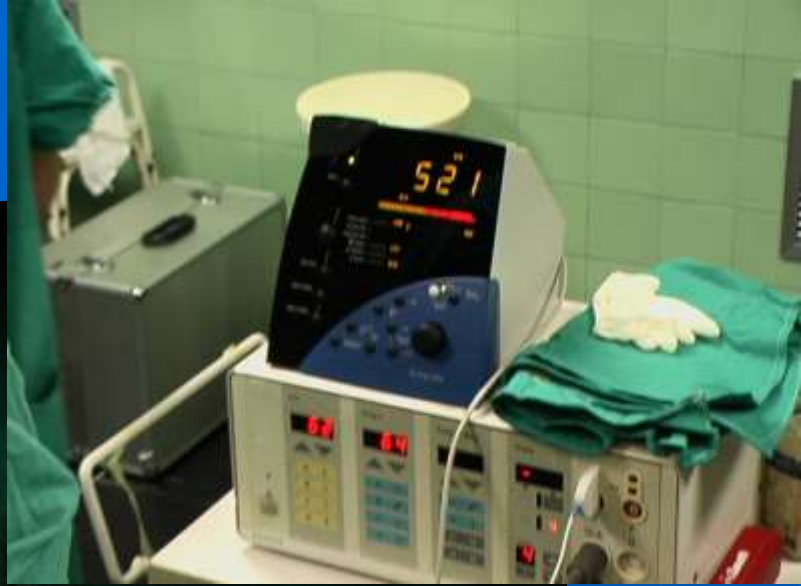
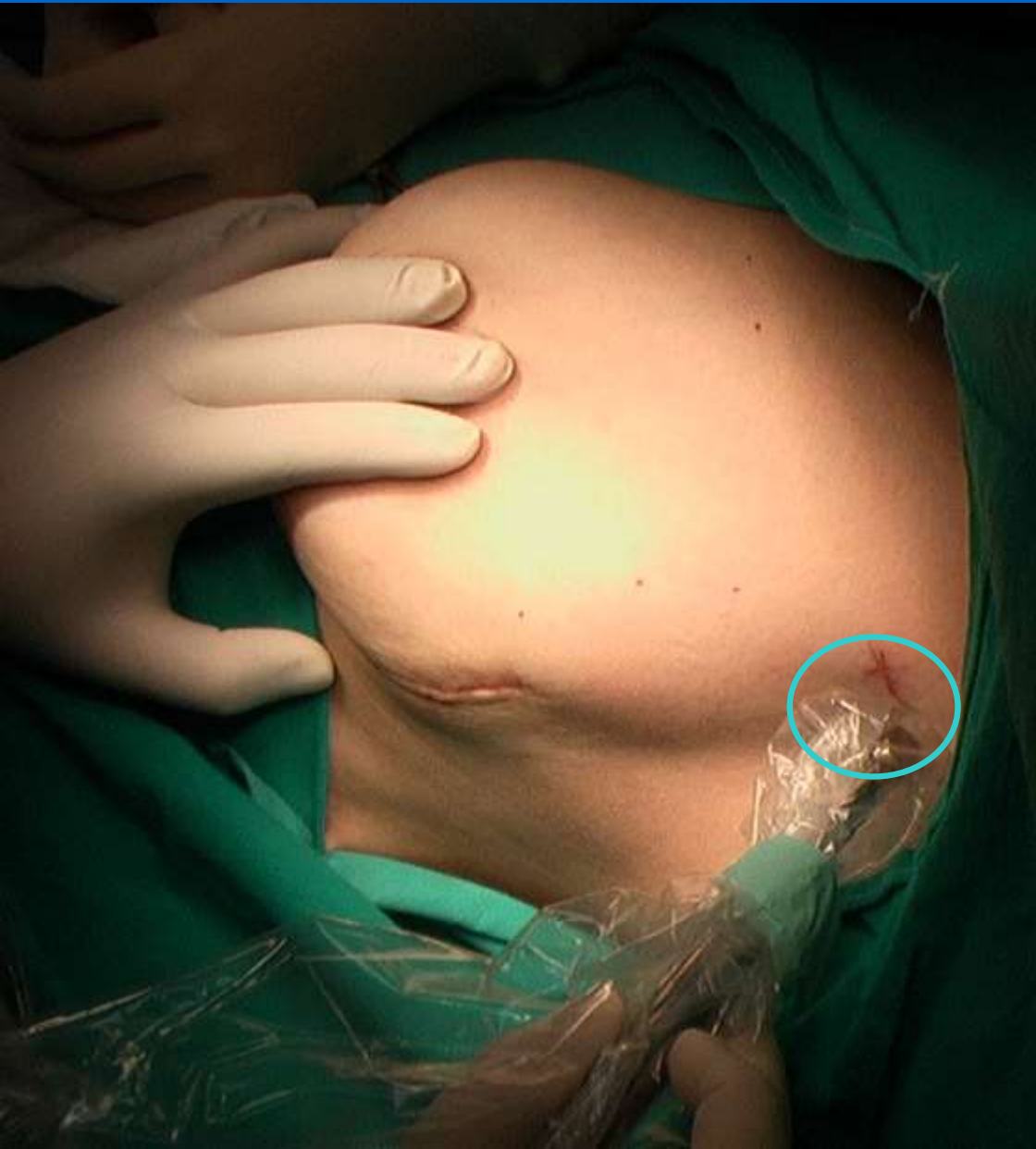
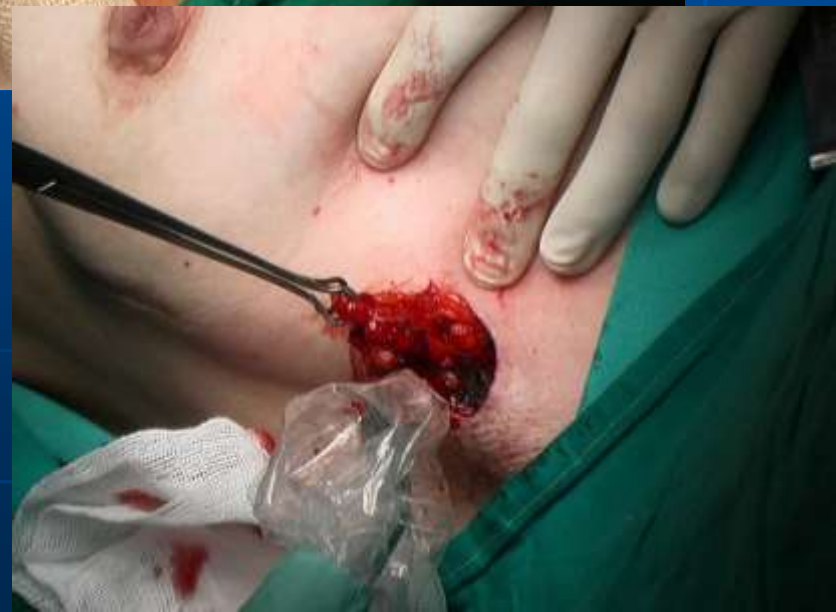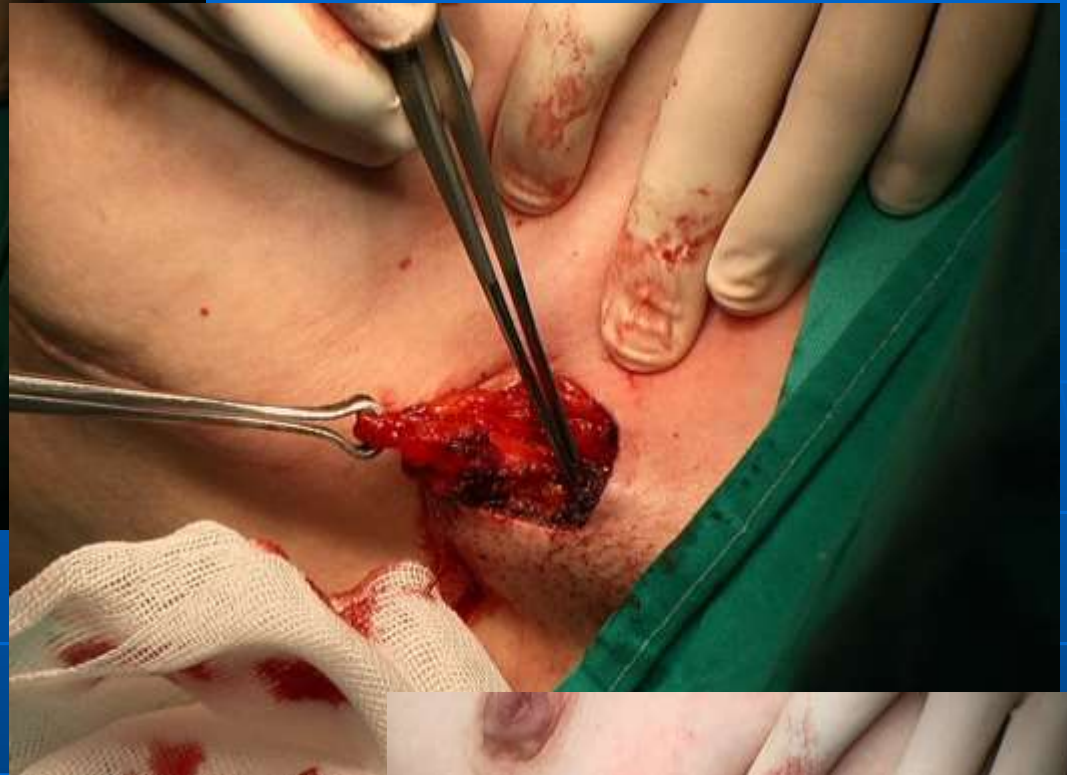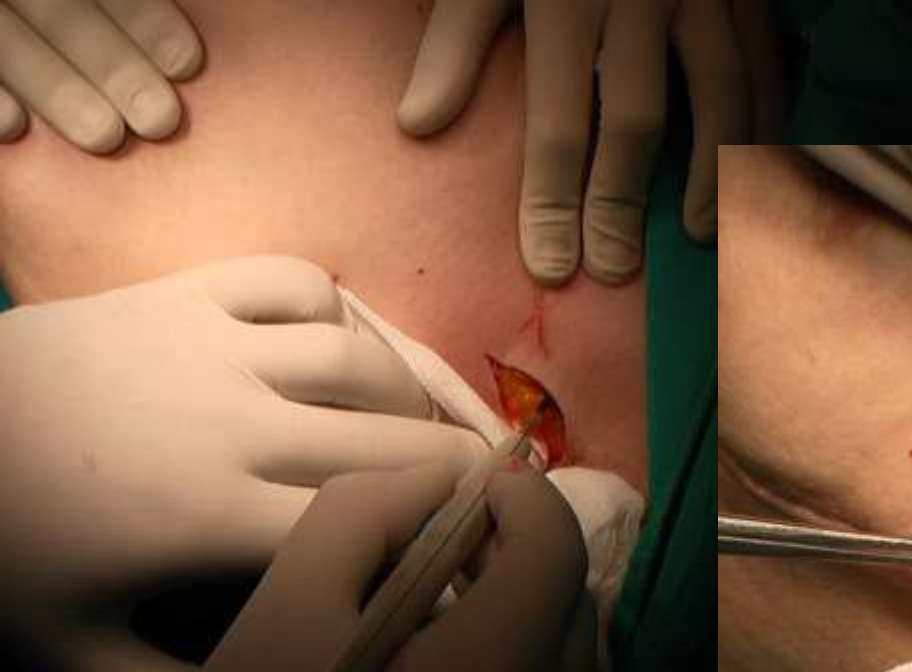120min-Co 209K

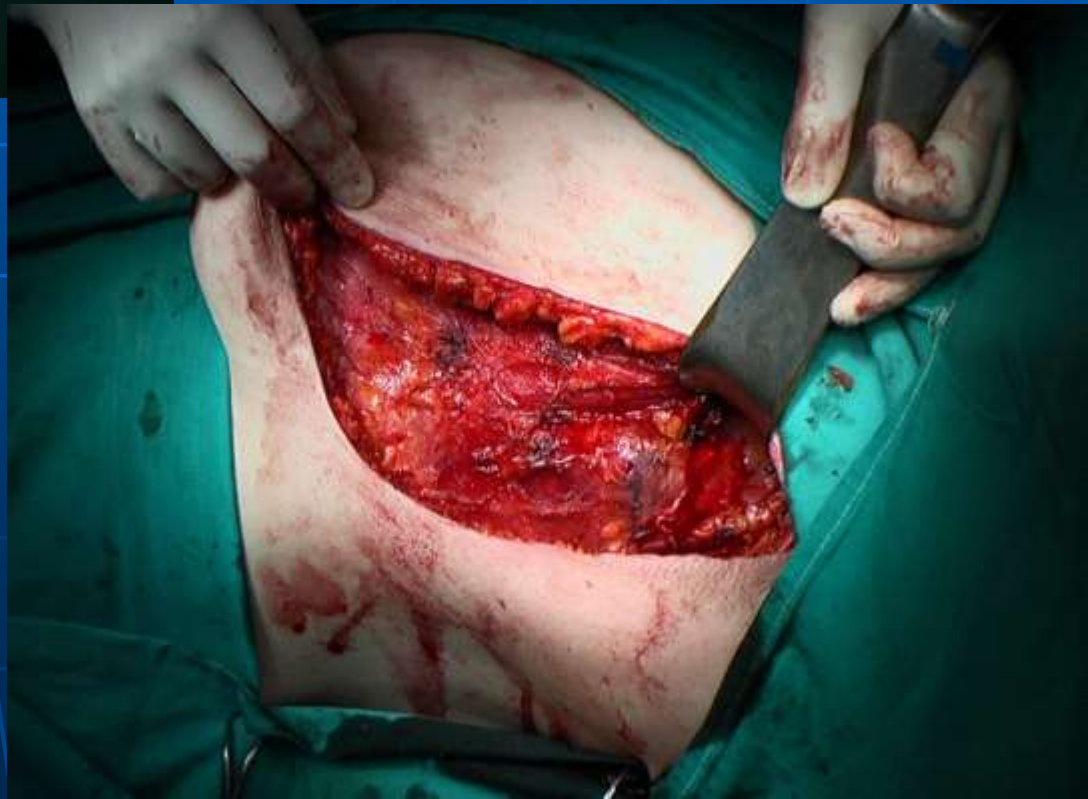
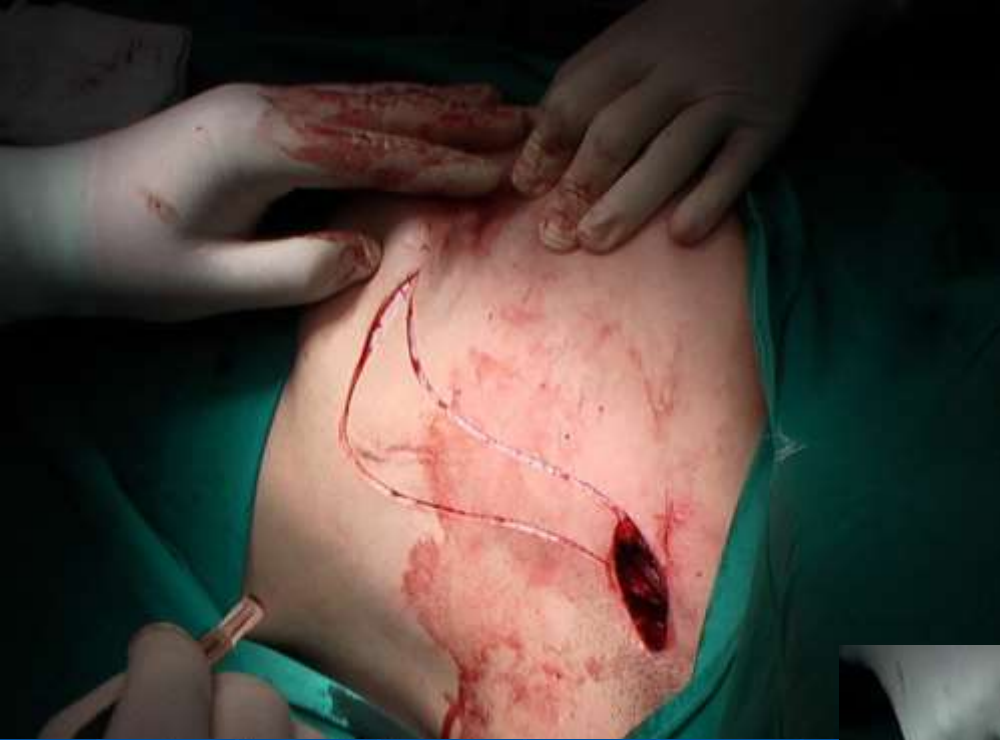
120min-AP-Co 186K

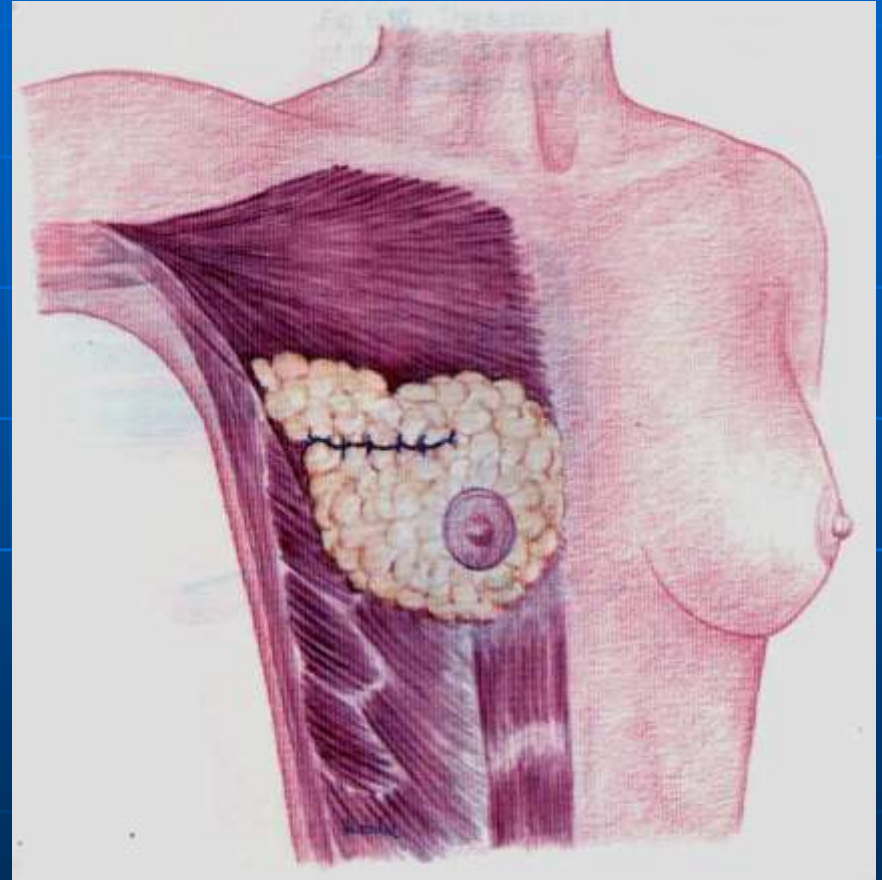
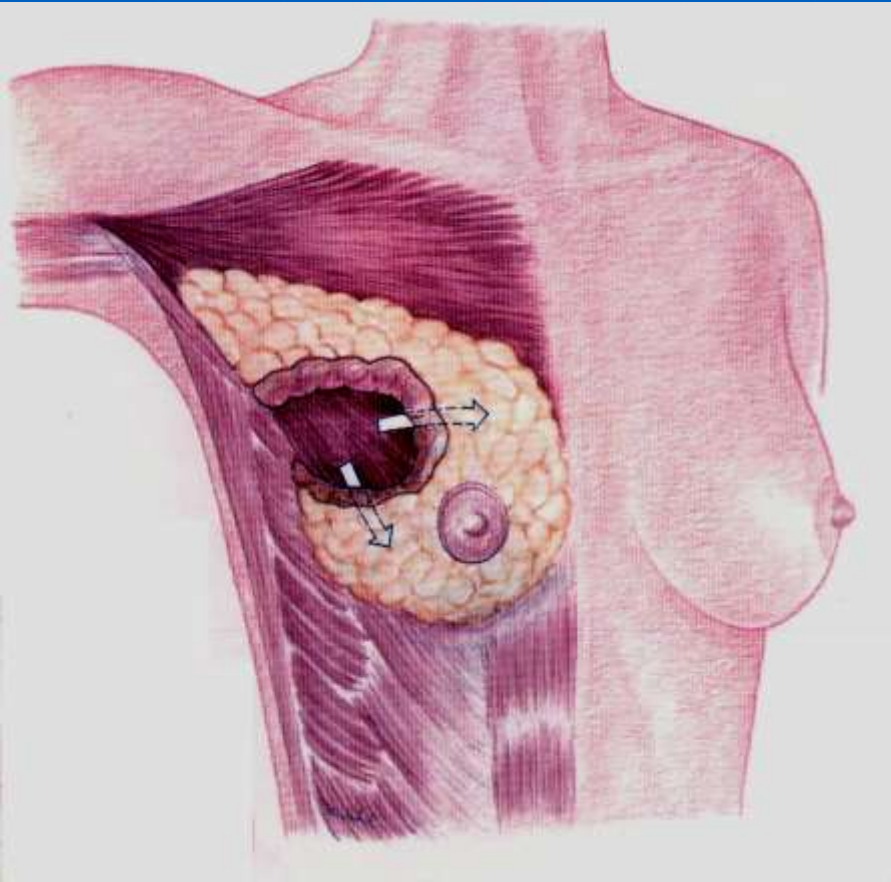




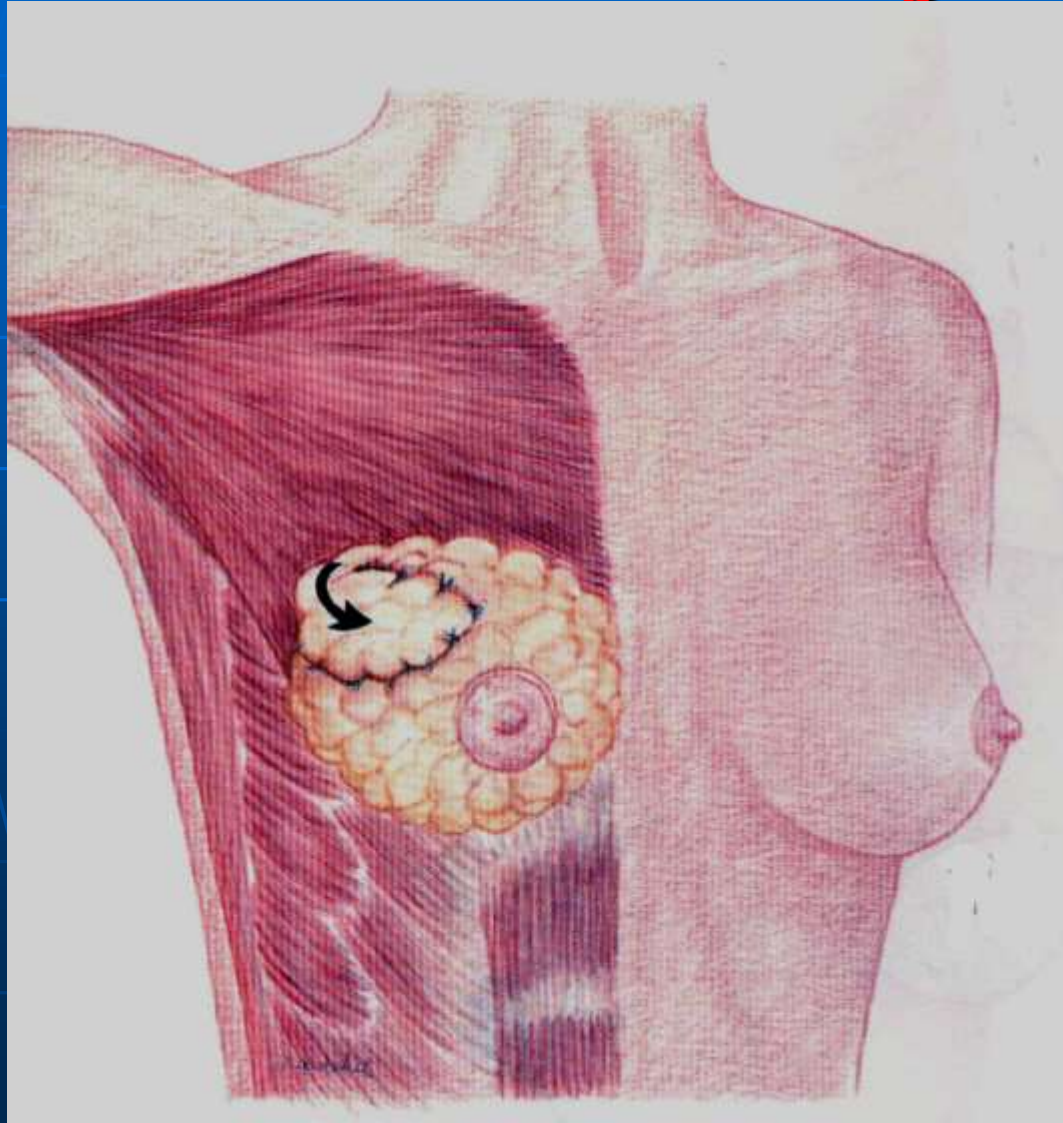




# Rekonstrukcija na dojka posle kvadrantektomija

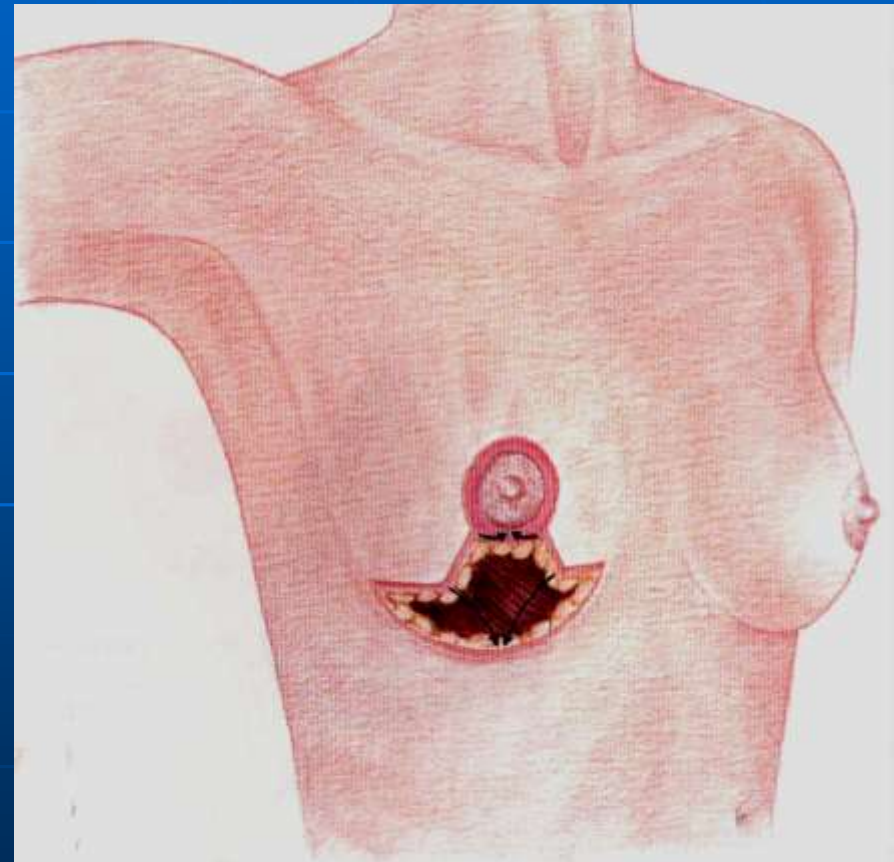
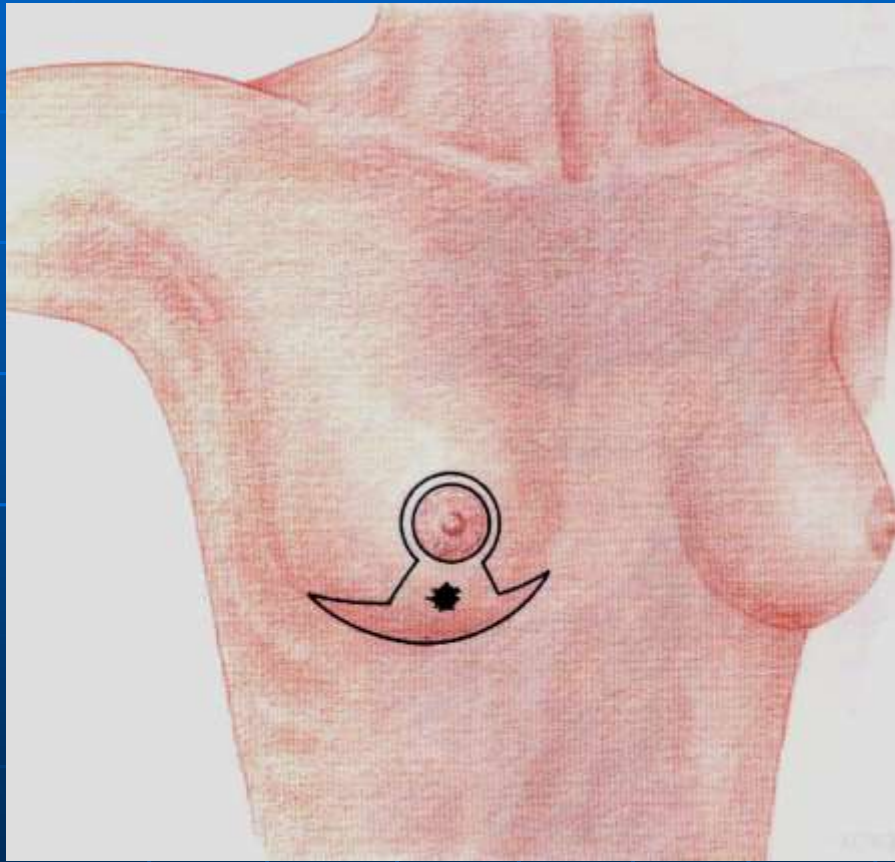


# Rekonstrukcija na dojka posle kvadrantektomija

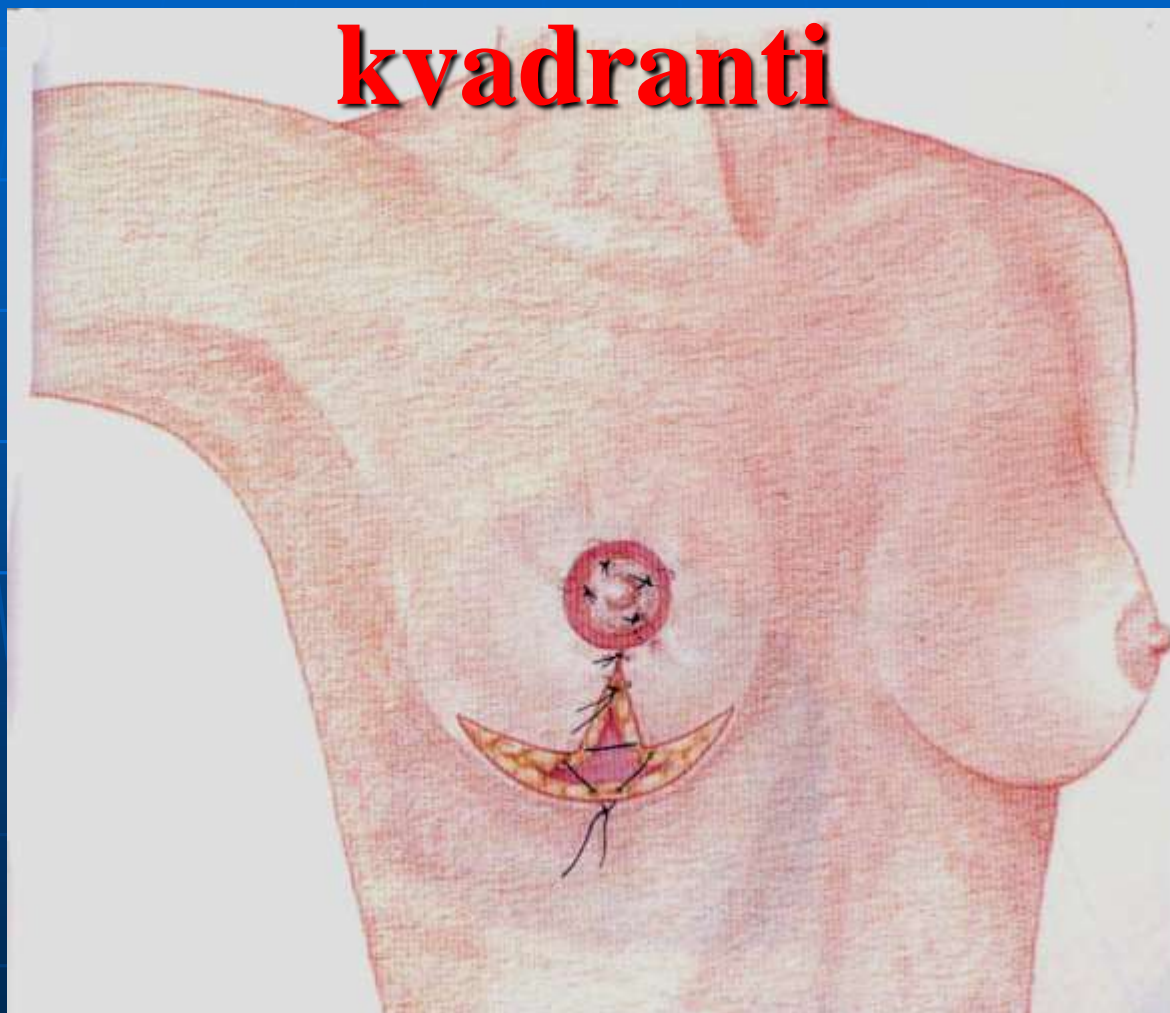



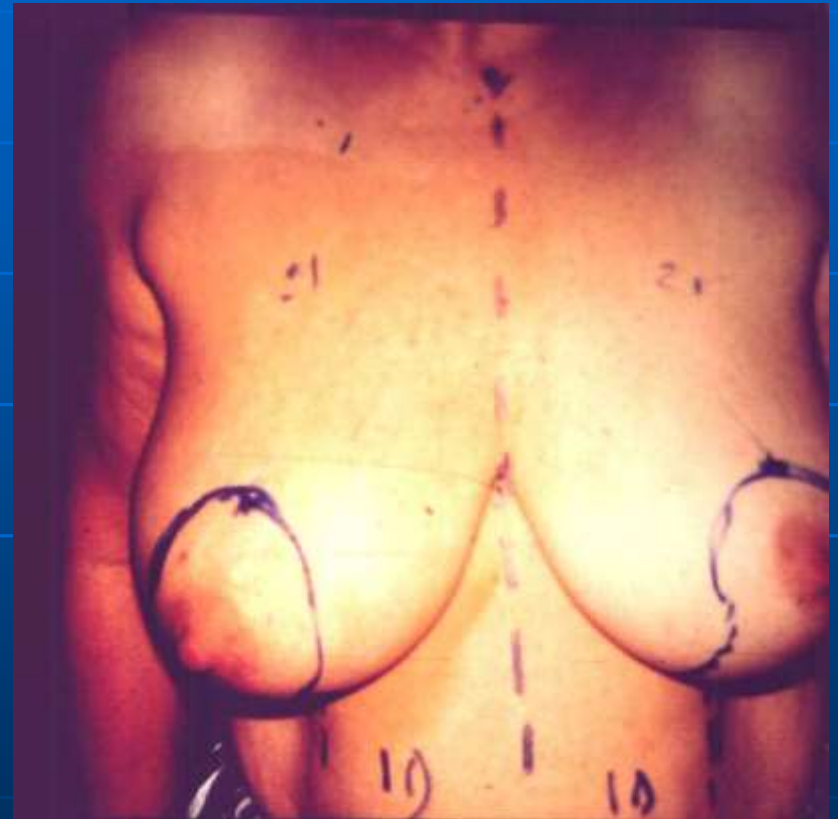
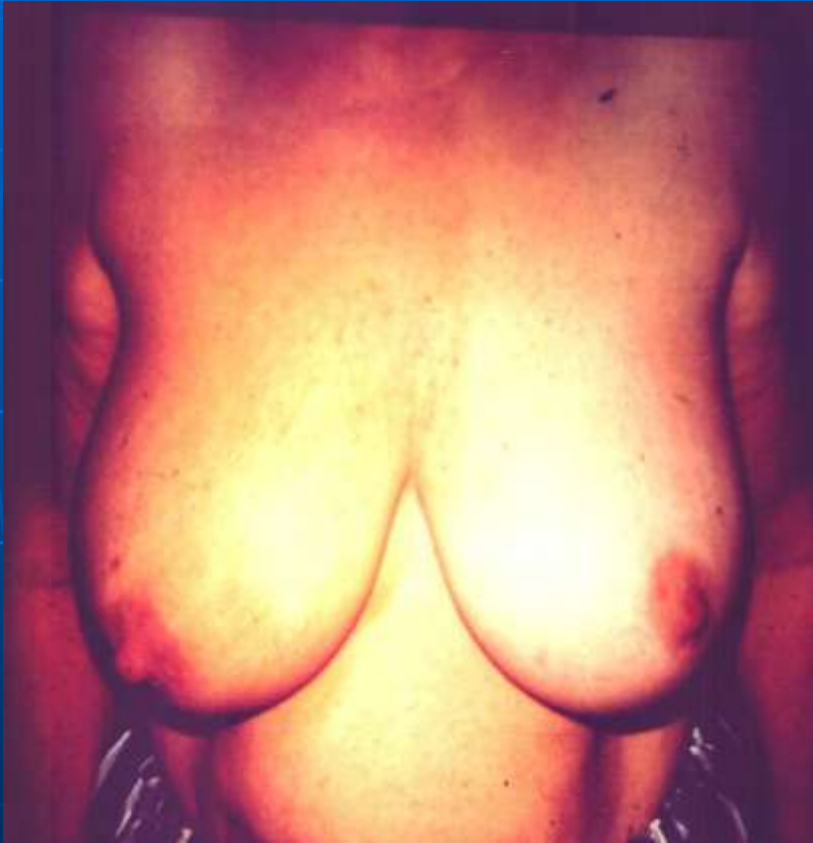# Konzervirna~ka operacija pri tumor lociran vo dolni kvadranti



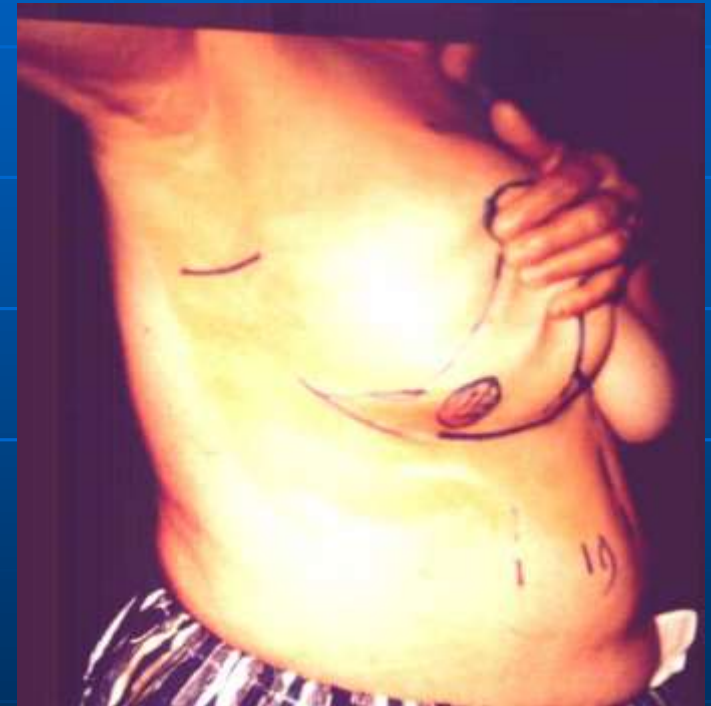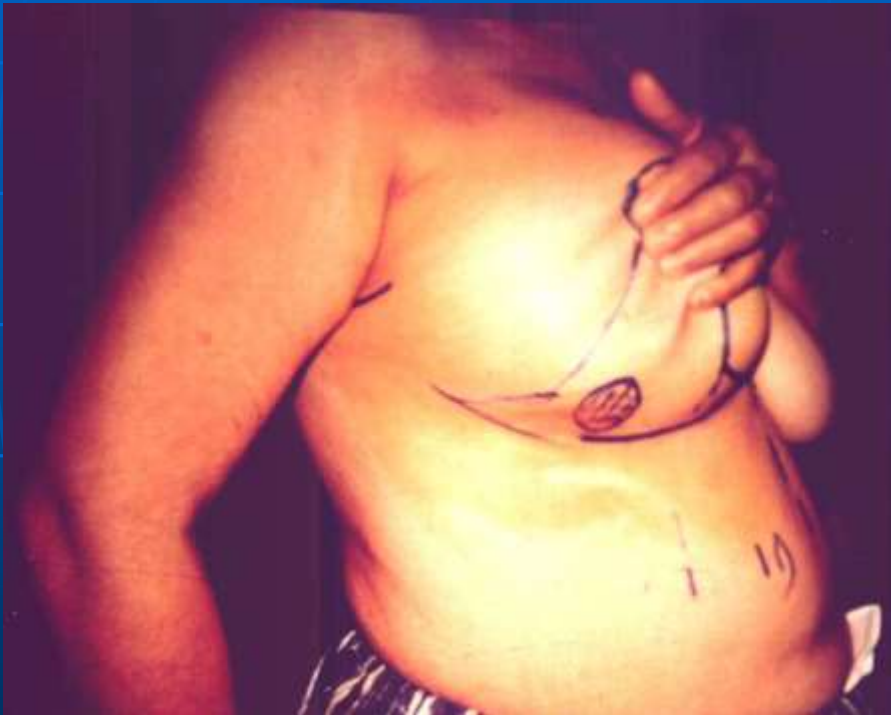
# Konzervira~ka operacija pri tumor lociran vo dolni kvadranti



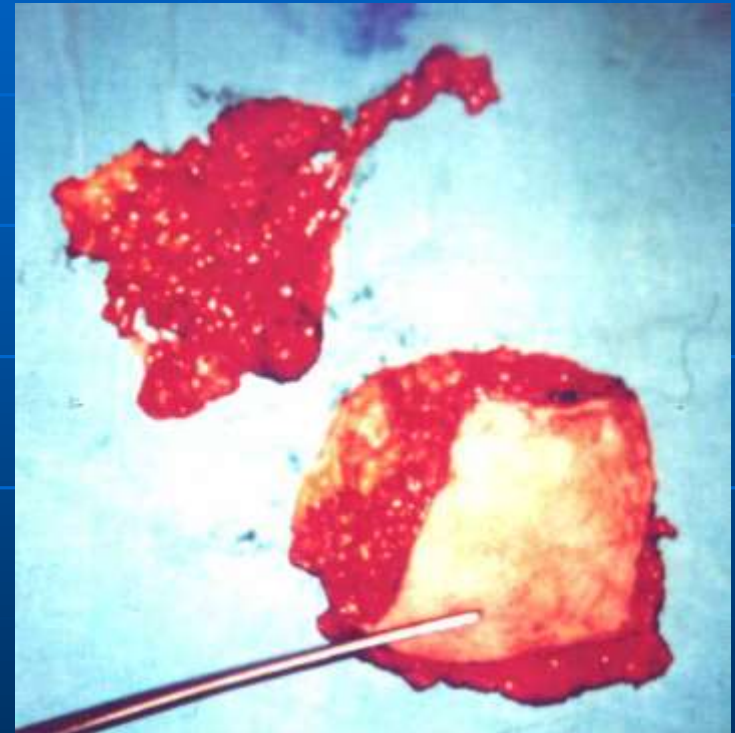
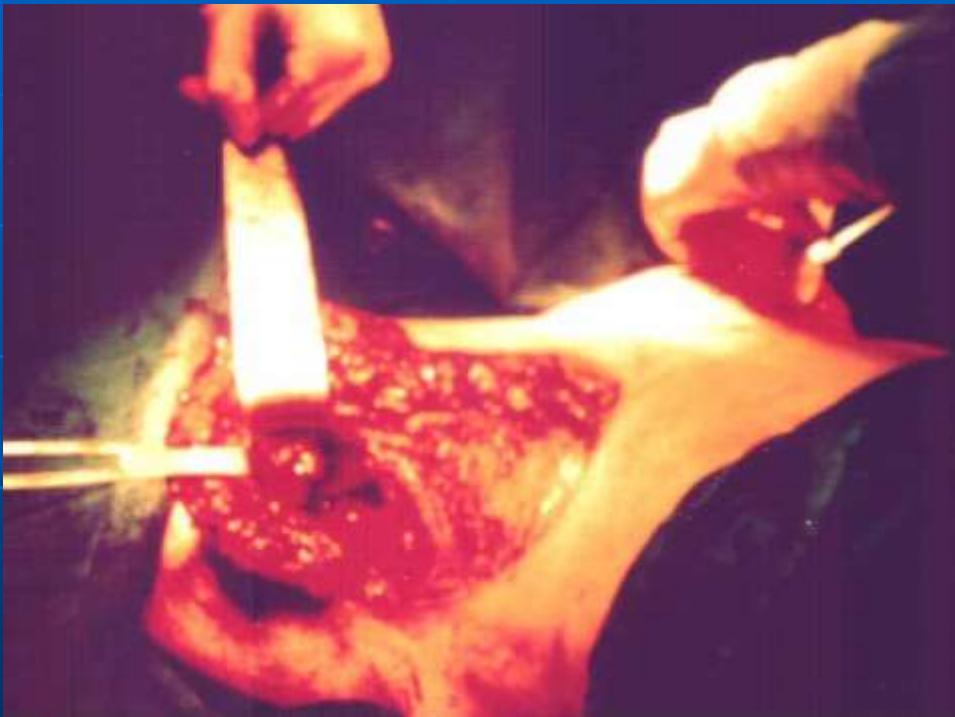
# Bilateralna mamoplastika so aksilarna limfadenektomija desno



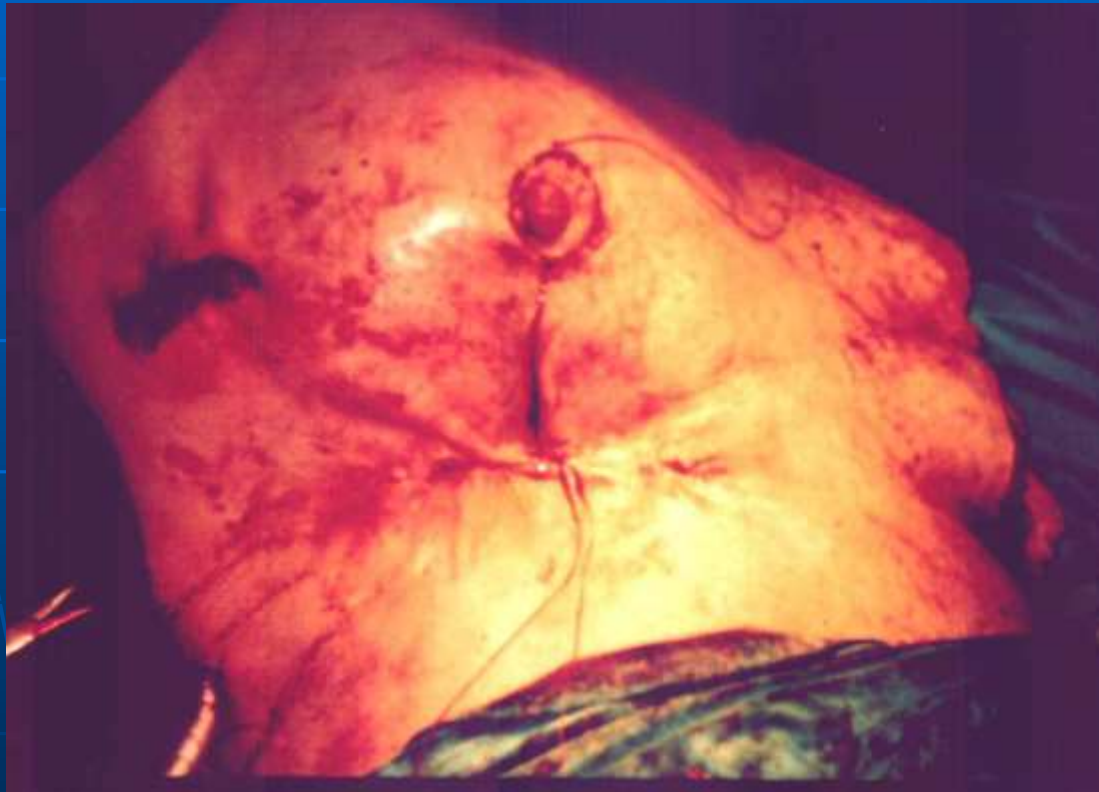# Bilateralna mamoplastika so aksilarna limfadenektomija desno



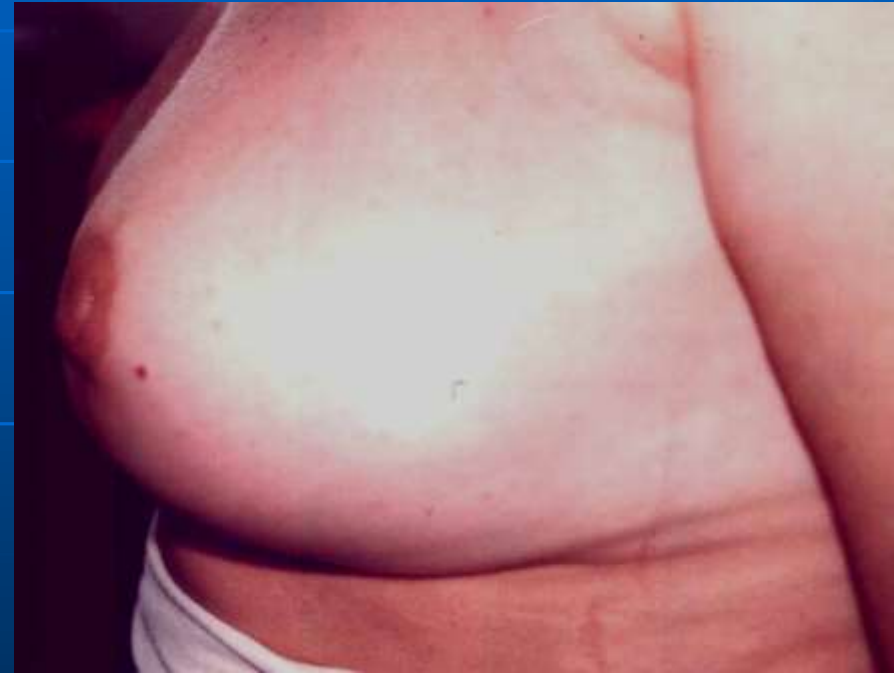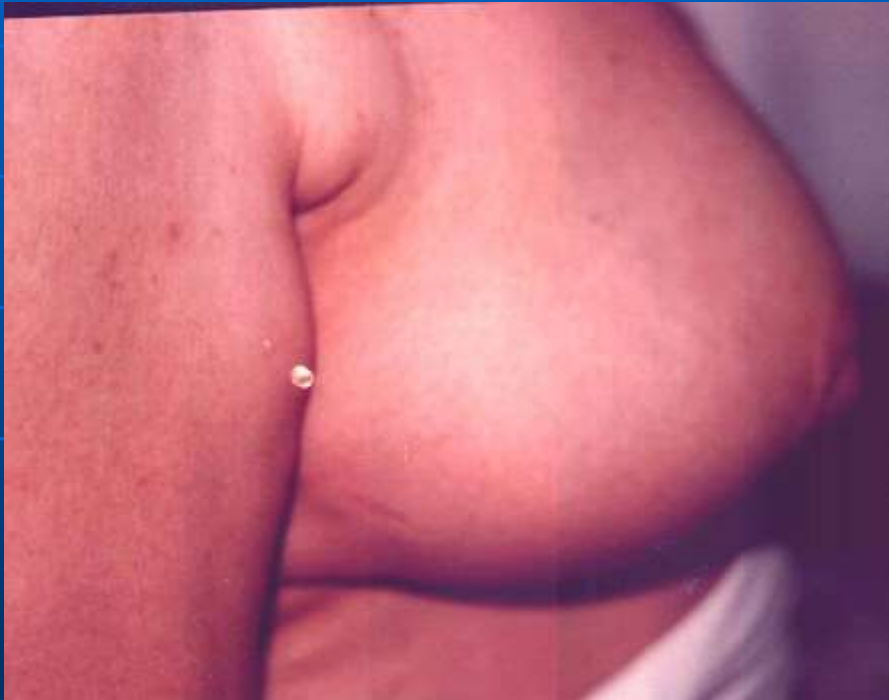# Bilateralna mamoplastika so aksilarna limfadenektomija desno



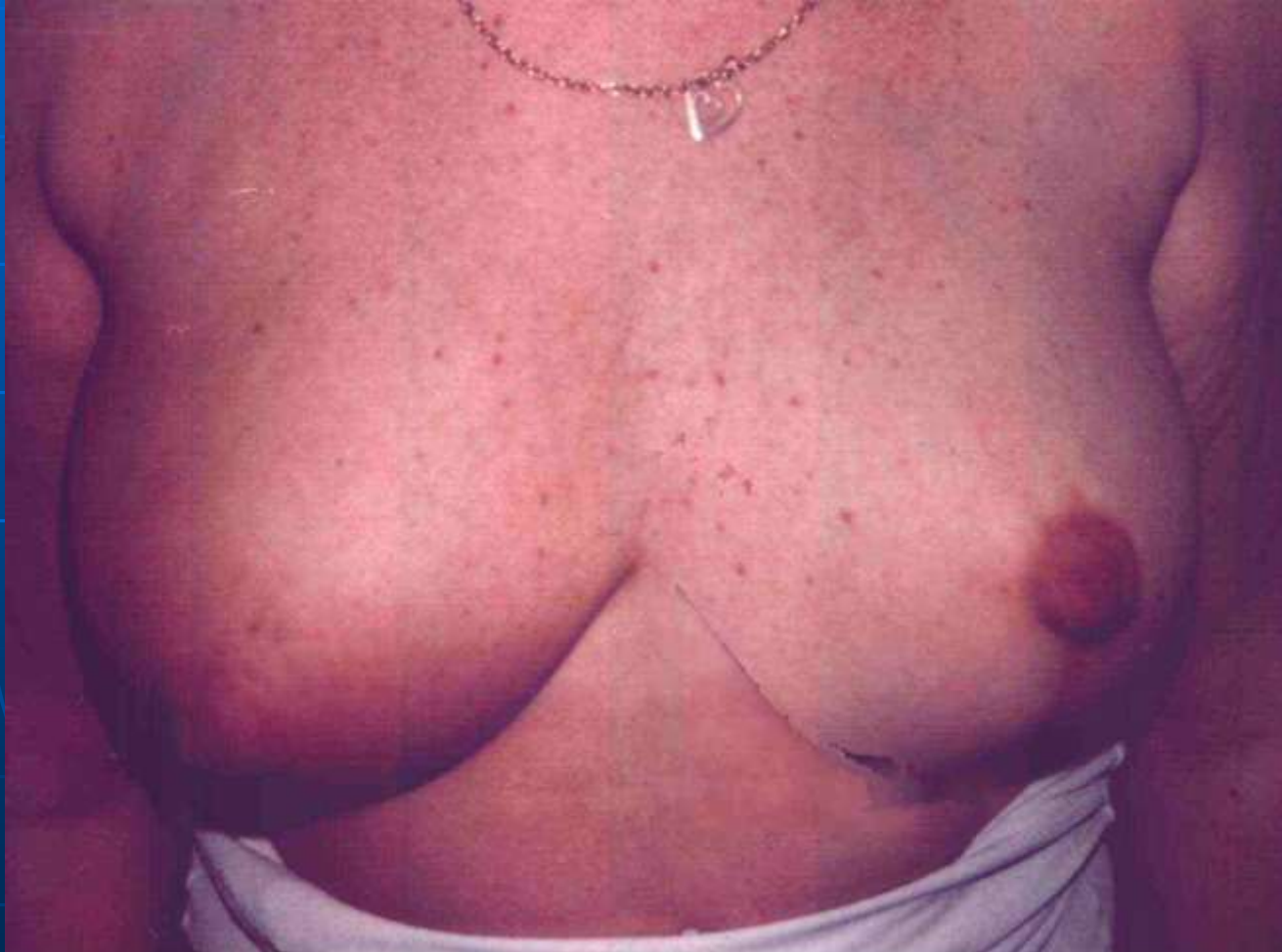# Bilateralna mamoplastika so aksilarna limfadenektomija desno



# Bilateralna mamoplastika so aksilarna limfadenektomija desno

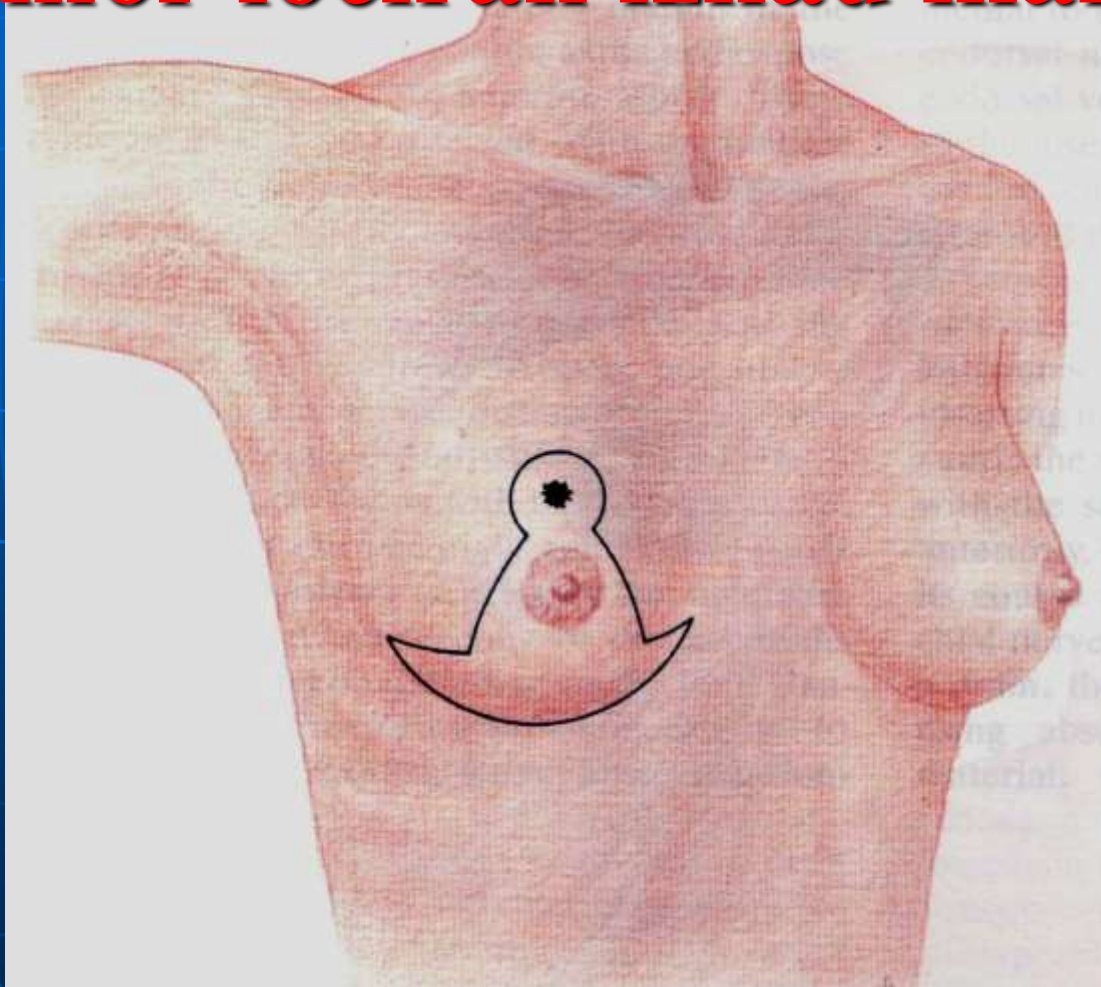


# Bilateralna mamoplastika so aksilarna limfadenektomija desno

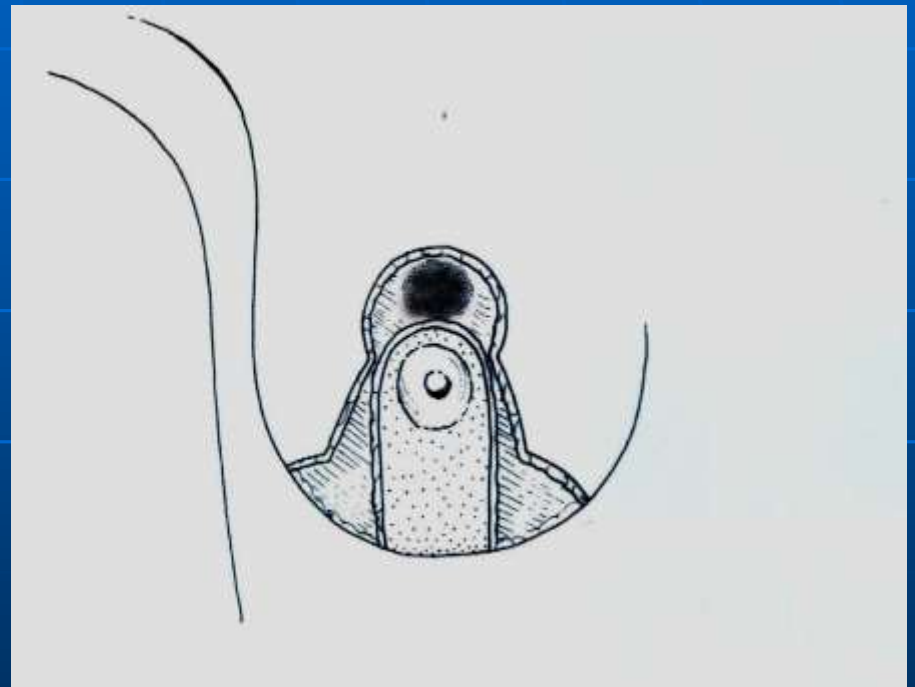
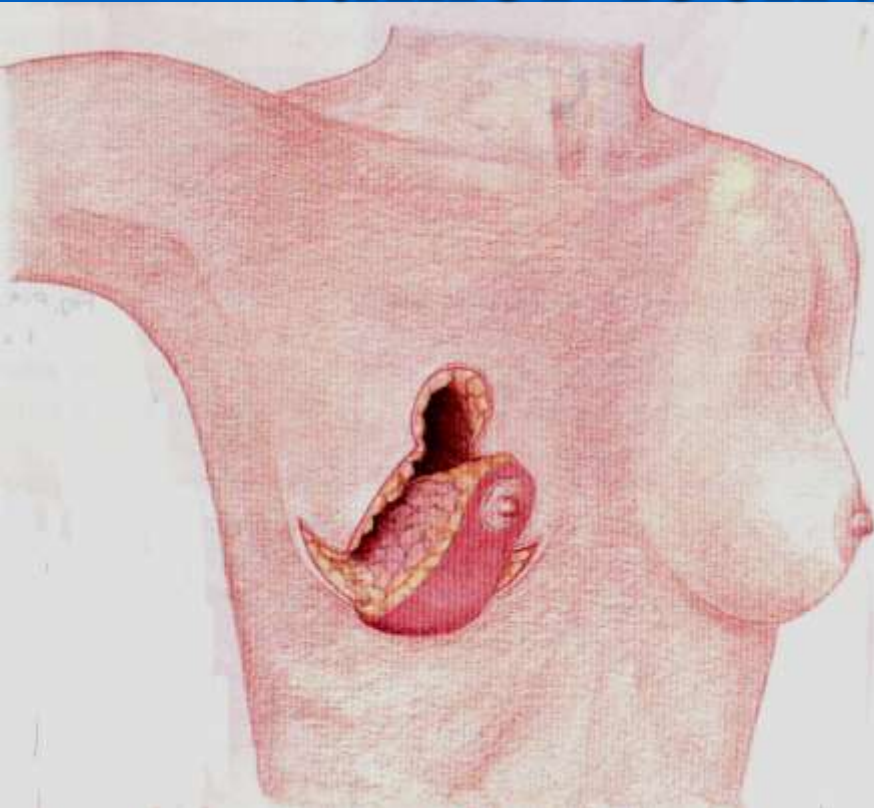




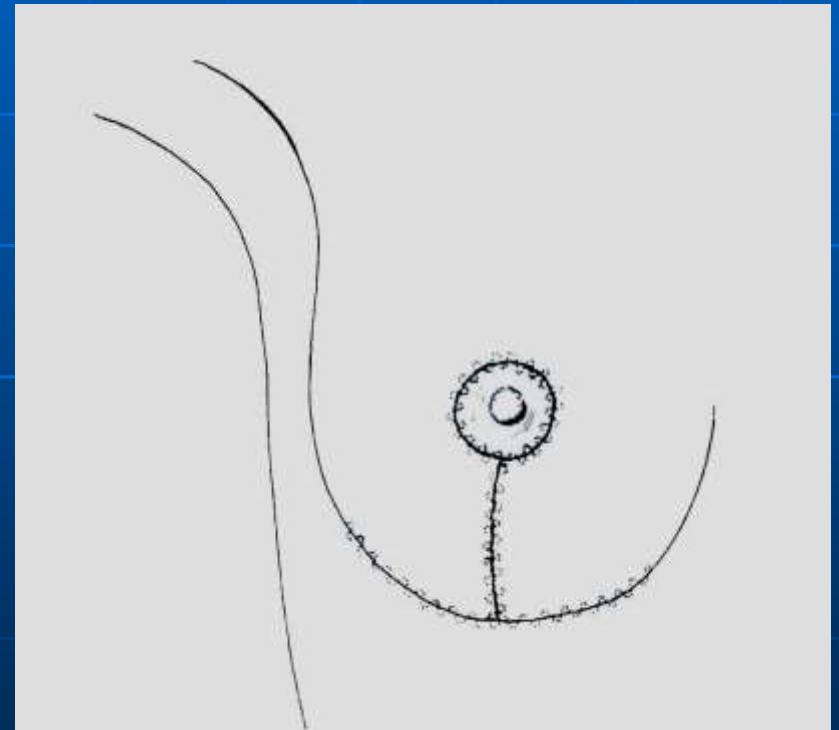
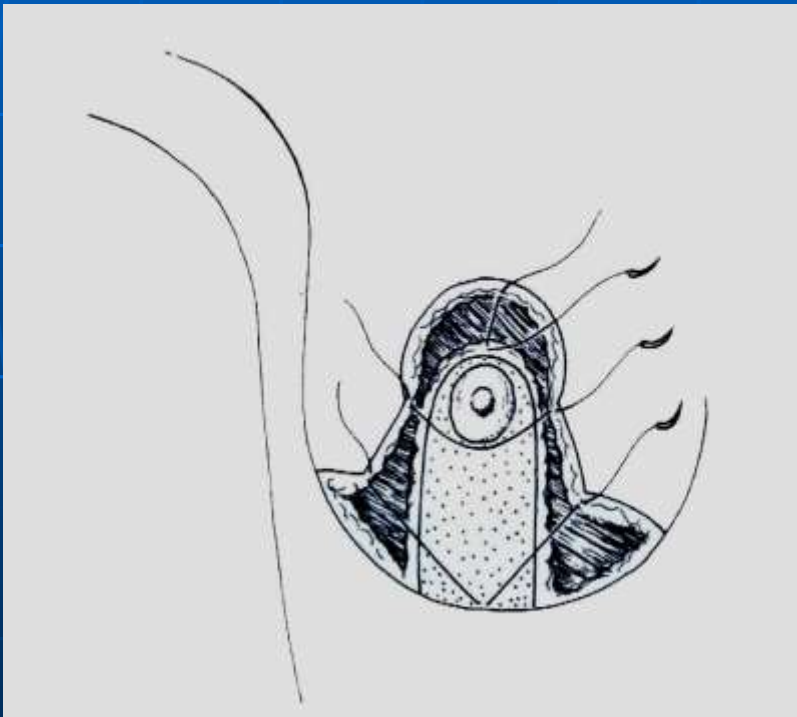
# Konzervira~ka operacija pri tumor lociran iznad mamila



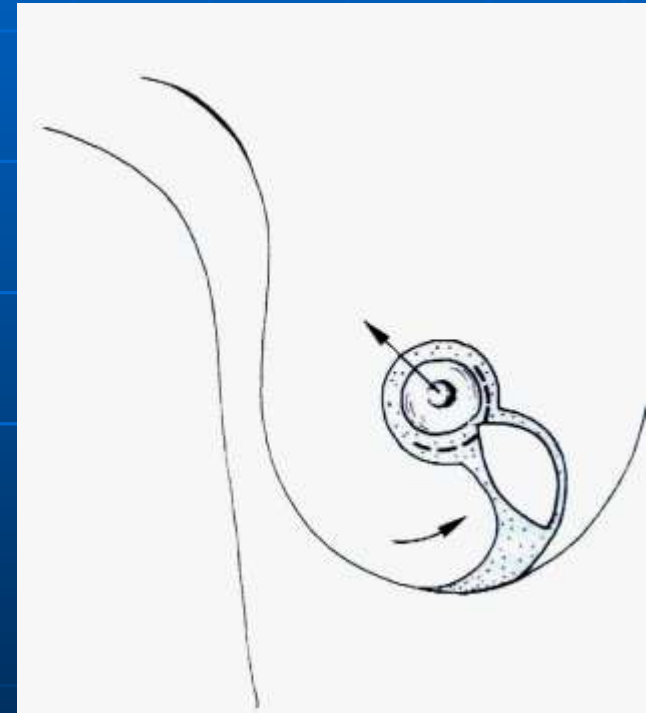
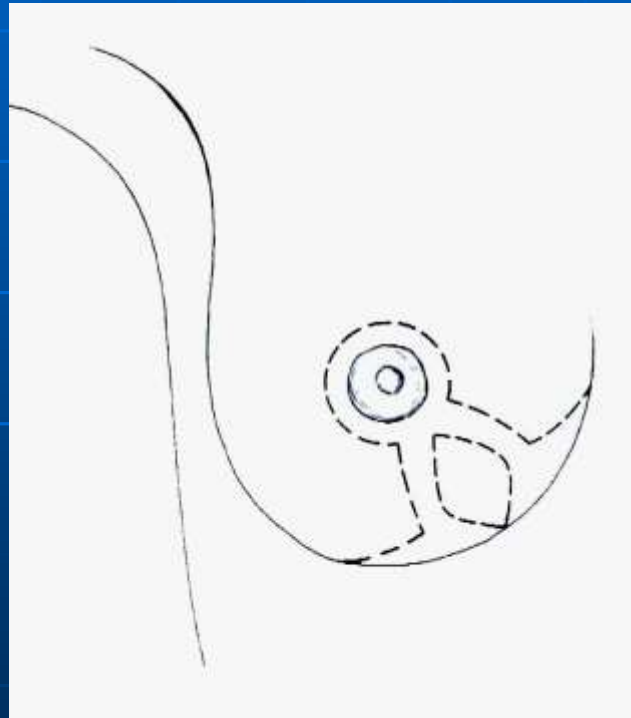
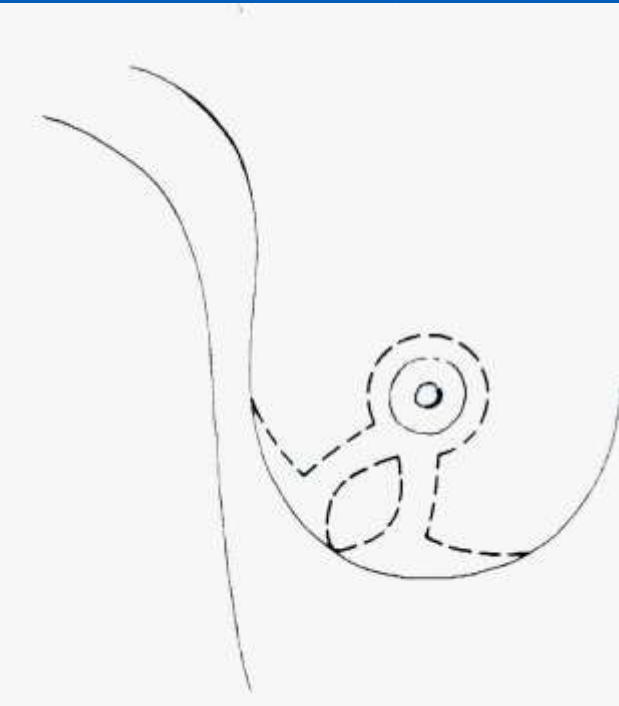
# Konzervira~ka operacija pri tumor lociran iznad mamila



# Konzervira~ka operacija pri tumor lociran iznad mamila

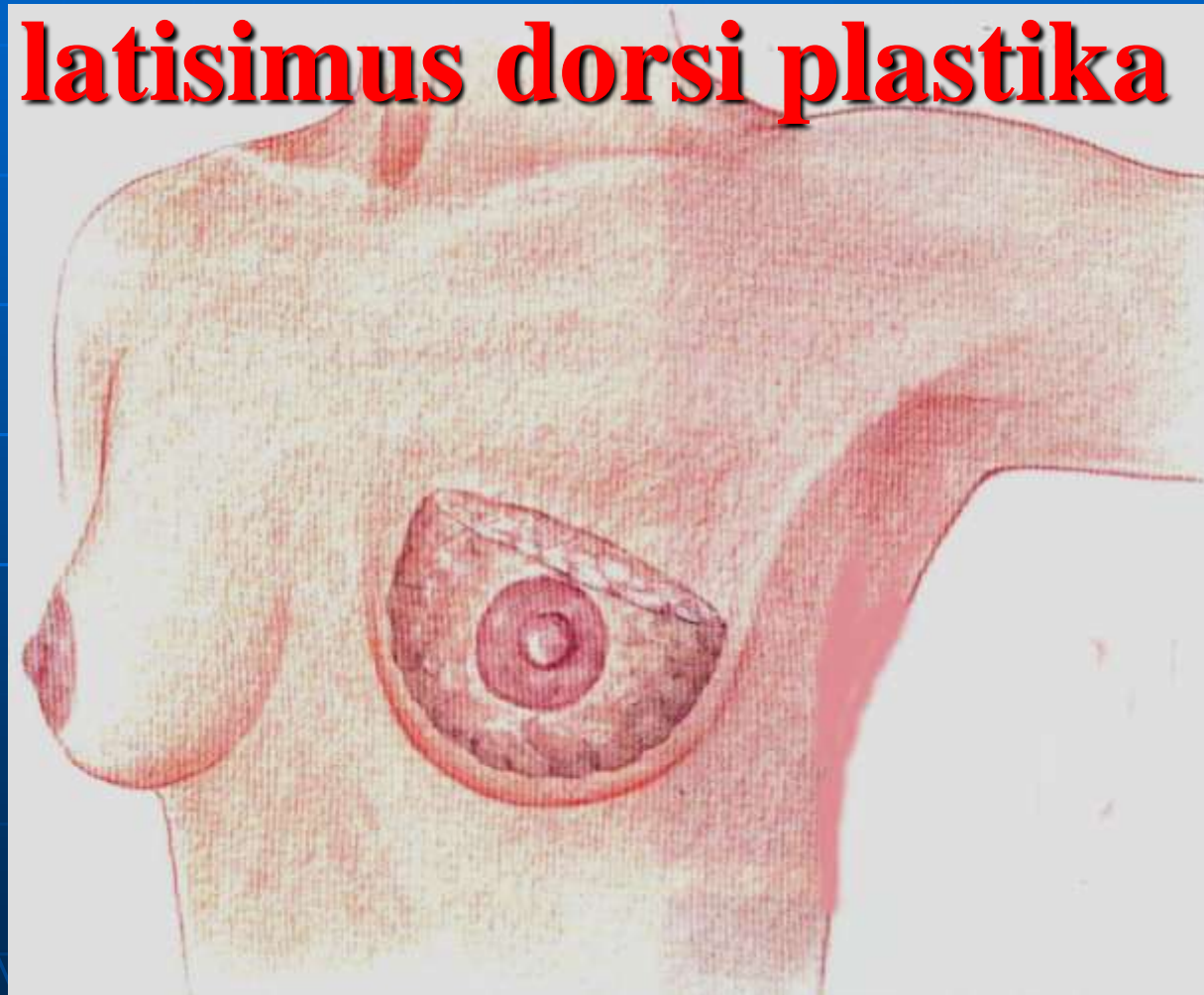

# Konzervira~ka operacija pri tumor lociran vo dolnolateralen i dolnomedijalen kvadrant



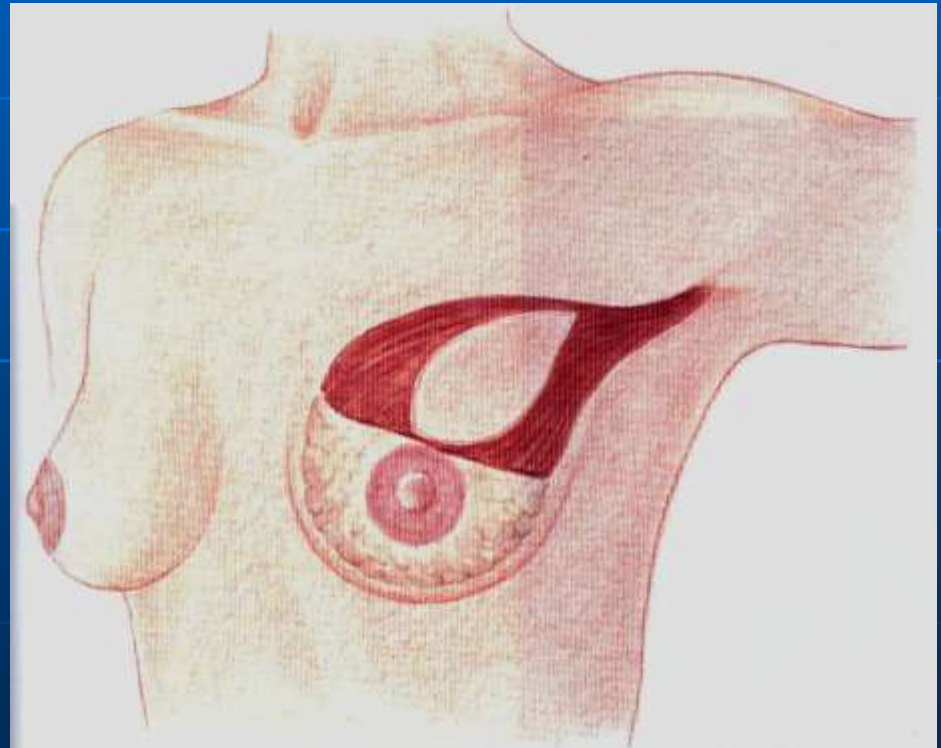

**Konzervira~ka operacija pri tumor  
lociran vo gorni kvadranti so m.**

**latisimus dorsi plastika**

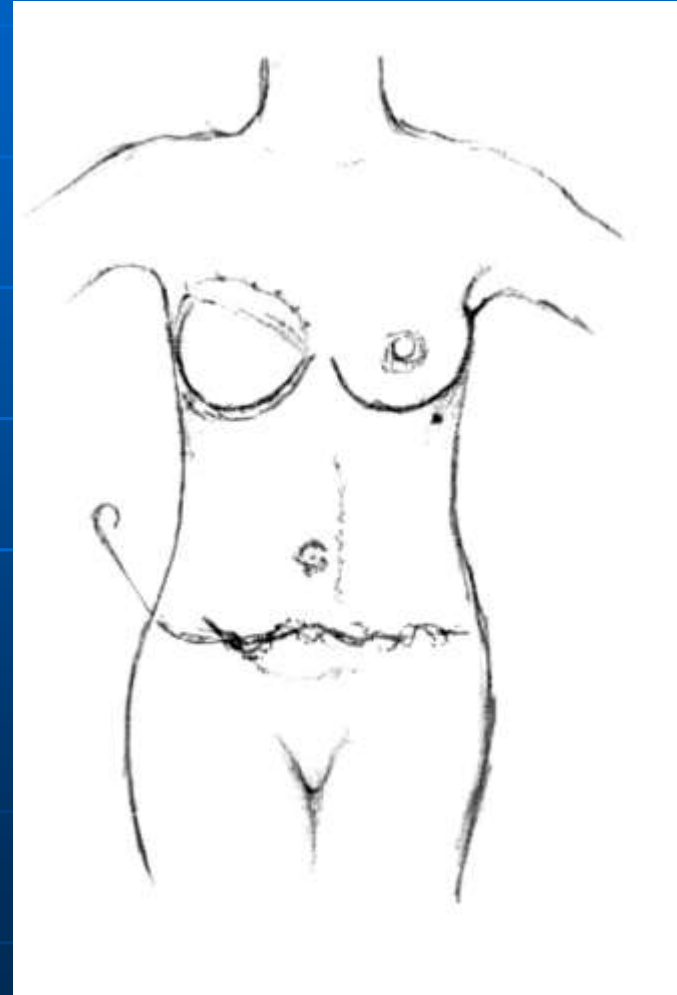
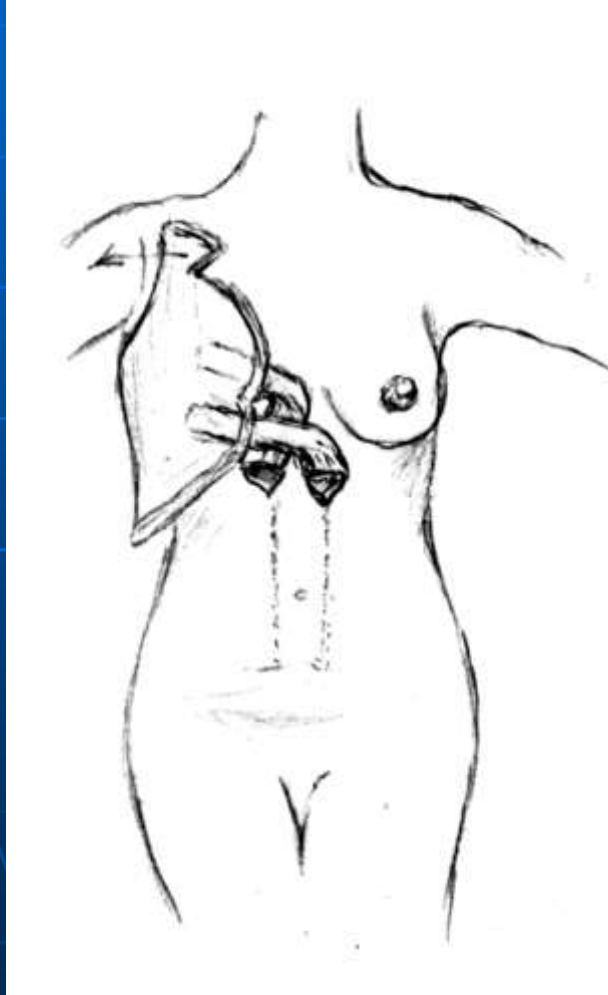


# Konzervira~ka operacija pri tumor lociran vo gorni kvadranti so m.

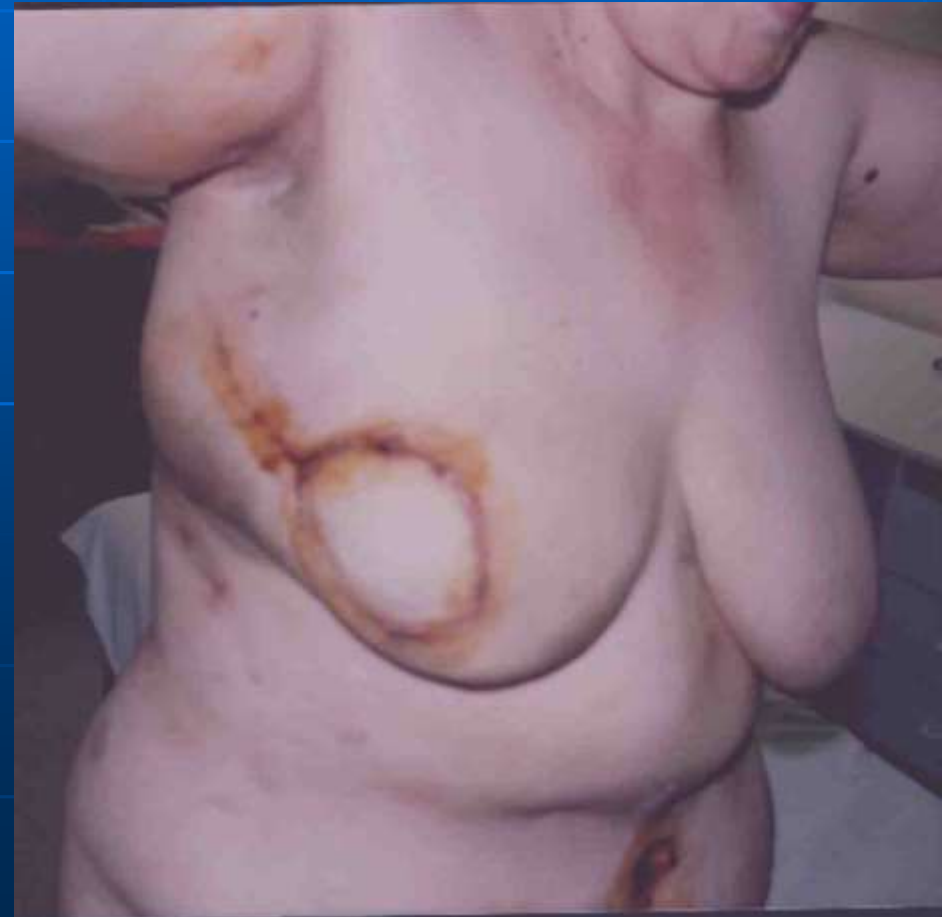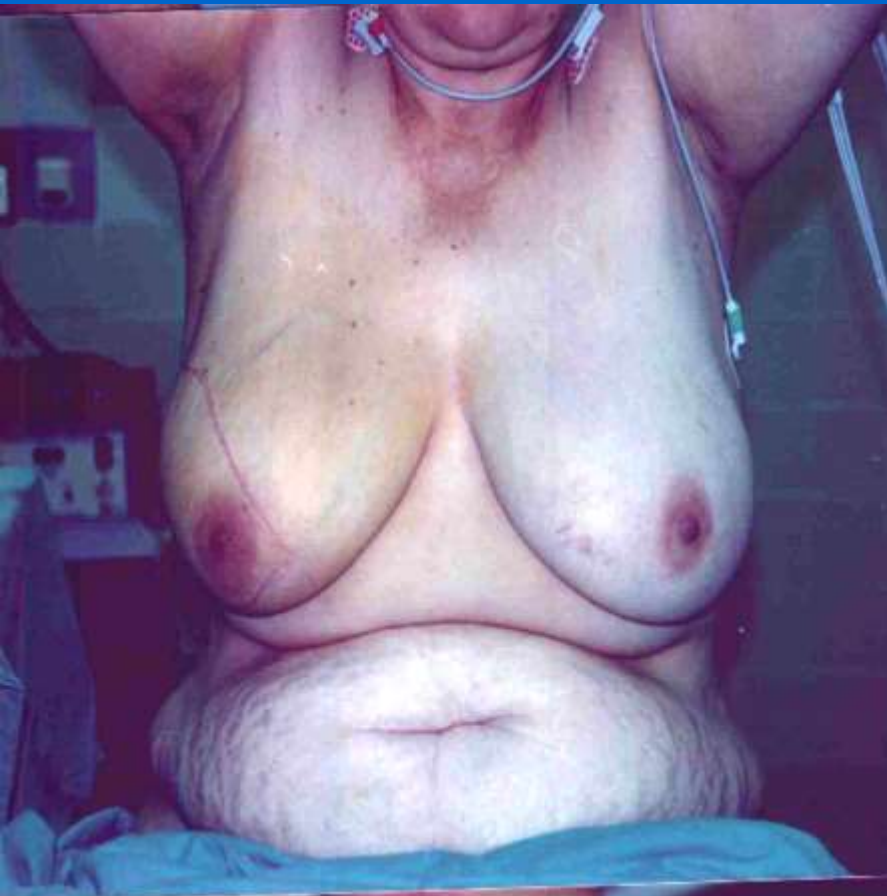
## latisimus dorsi plastika



# Mastektomija so TRAMP plastika

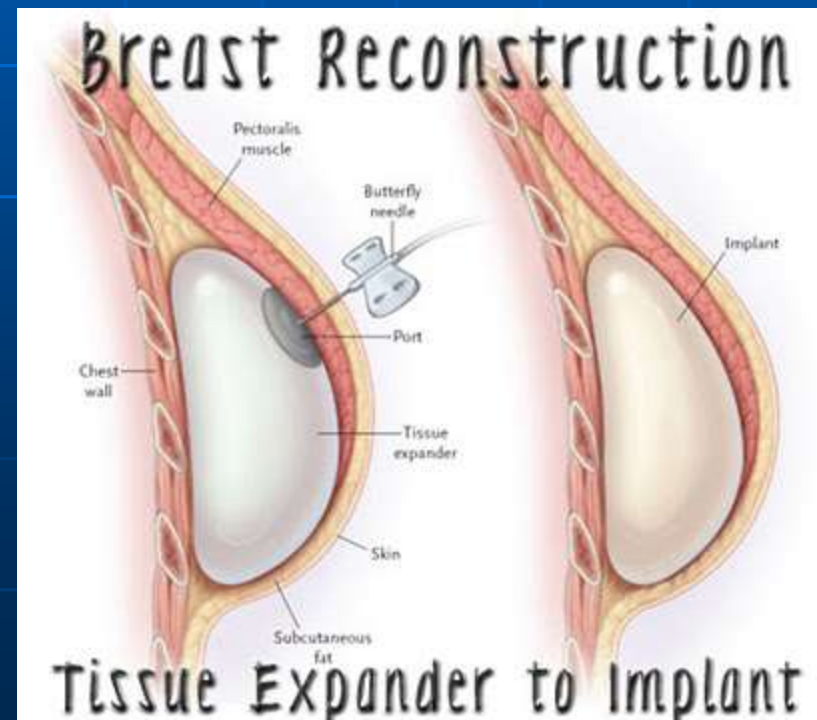
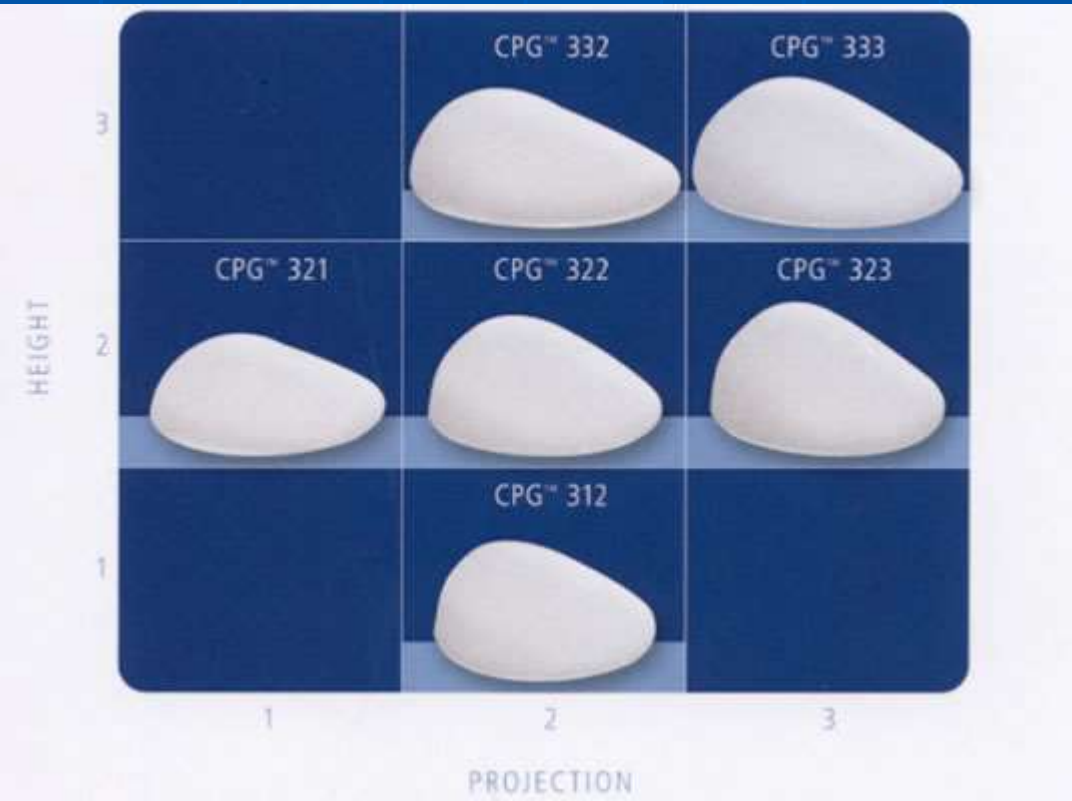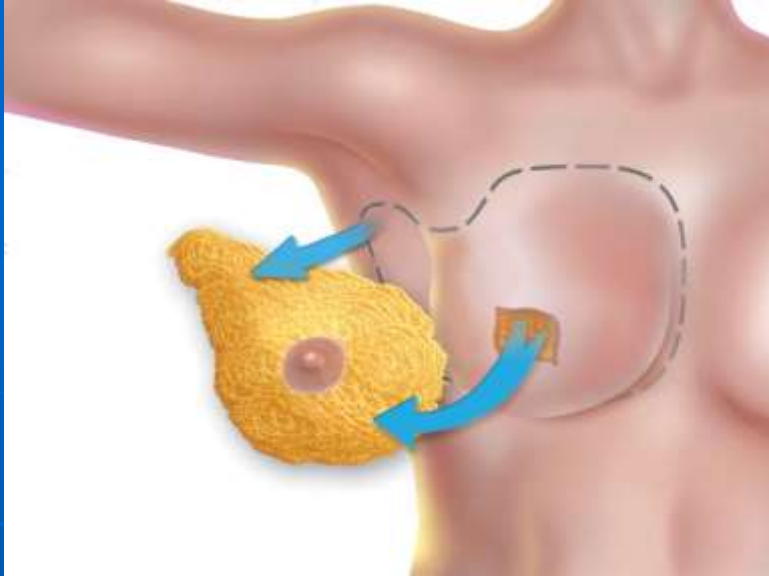


# Mastektomija so TRAMP plastika

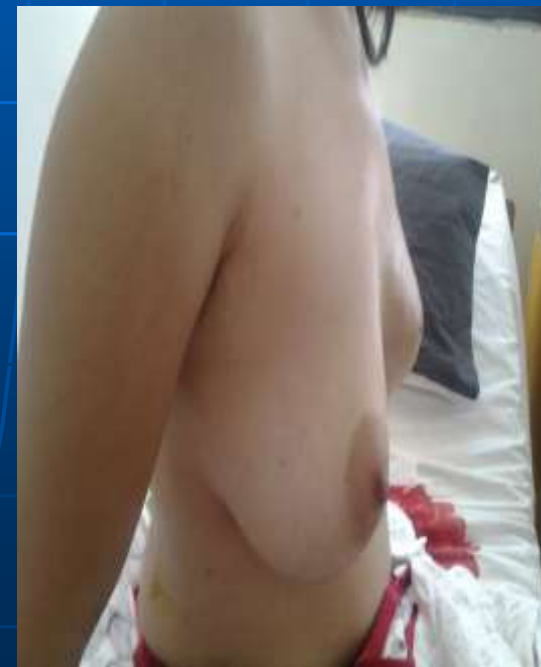
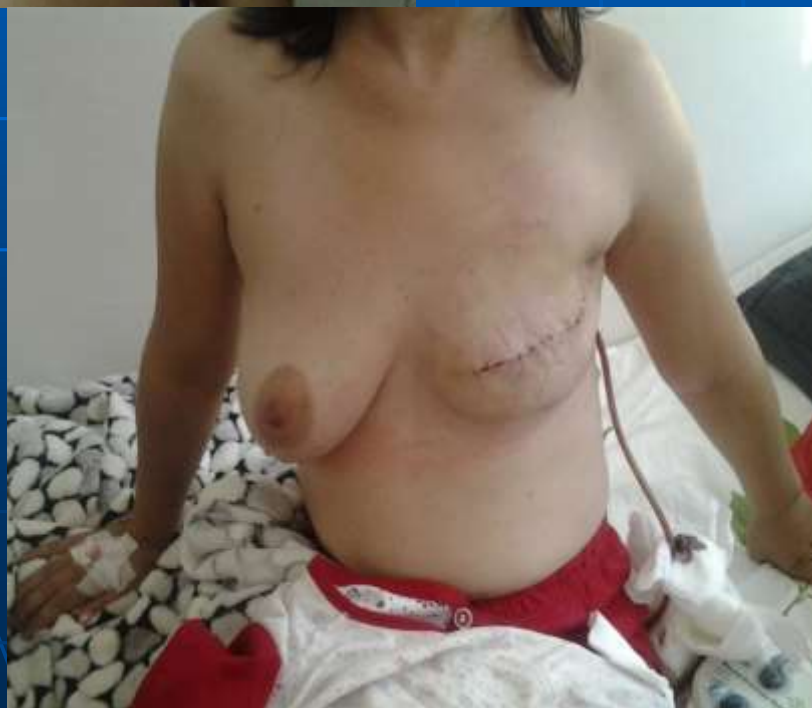


# Mastektomija so implantacija na silikonska proteza



# Mastektomija so implantacija na silikonska proteza



# HIRUR[KA TERAPIJA

## 1. TUMERECTOMIA

+/- AKSILARNA LIMFADENCTOMIJA

## 2. KONZERVIRANJE OPERACIJE

- LYMPEKTOMIJA
- SEGMENTRESEKCIJA
- QUADRANTECTOMIA
- PARCIJALNA MASTEKTOMIJA

+/- AKSILARNA LIMFADENCTOMIJA

## 3. RADIKALNA MASTEKTOMIJA

- SIMPLEKS MASTEKTOMIJA
- MODIFICIRANA RADIKALNA MASTEKTOMIJA (MADDEN, PATAY)
- RADIKALNA MASTECTOMIA (HALSTED)
- SUPERRADIKALNA MASTECTOMIA (URBAN)

+/- AKSILARNA LIMFADENCTOMIJA

## 4. OPNA LOKALNI RECIDIVI/ MS

HISTOLO[KA  
DG.

pTNM  
stadium

??

ZRA^NA  
TERAPIJA

HEMOTERA-  
PIJA

HORMONO-  
TERAPIJA

IMUNOTE-  
RAPIJA

SIMPTOMA-  
TSKA

VOZRAS  
-premenopauza  
-postmenopauza

# Terapiski protokol

Stadium	QU	M	AD	RT	Adjuvant	Hormon	Imuno
<b>0</b>	<b>+</b>	<b>+++</b>	<b>-</b>	<b>+/-</b>	<b>-</b>	<b>*</b>	<b>*</b>
<b>I</b>	<b>+++</b>	<b>+</b>	<b>+++</b>	<b>+/-</b>	<b>-/++</b>	<b>+*</b>	<b>+*</b>
<b>II</b>	<b>++</b>	<b>++</b>	<b>+++</b>	<b>+/-</b>	<b>+++</b>	<b>+*</b>	<b>+*</b>
<b>III</b>	<b>-</b>	<b>+++</b>	<b>+++</b>	<b>+++</b>	<b>+++</b>	<b>+*</b>	<b>+*</b>
<b>IV</b>	<b>Biopsy</b>	<b>-</b>	<b>-</b>	<b>+++</b>	<b>+++</b>	<b>+*</b>	<b>+*</b>

# ZRA^NA TERAPIJA

# Zra~na terapija

- **Sir Geoffrey Keynes zra~nata terapija vlijae na malignite tumori 1937**
- **Klini~ka primena na zr~nata terapija vo onkologijata 1960**

# HEMIOTERAPIJA

# Hemioterapija

- Hemioterapijata se primenila od **Farber** vo tretman na leukemiite **1948**
- Tretman na malignom na dojka vo **60-70** godini na **XX** vek



# Hemioterapija

1. Hemioterapijata go zgolemuva kako vreme bez recidiv ("recurens free interval") taka i vkupnoto **pre`ivuvawe**.
2. **Polihemoterapijata** e mnogu poefektivna od monohemioterapijatata.
3. Primena na **pove}e ciklusi** (3-6) e poefektivna od primena na samo eden ciklus na terapija.

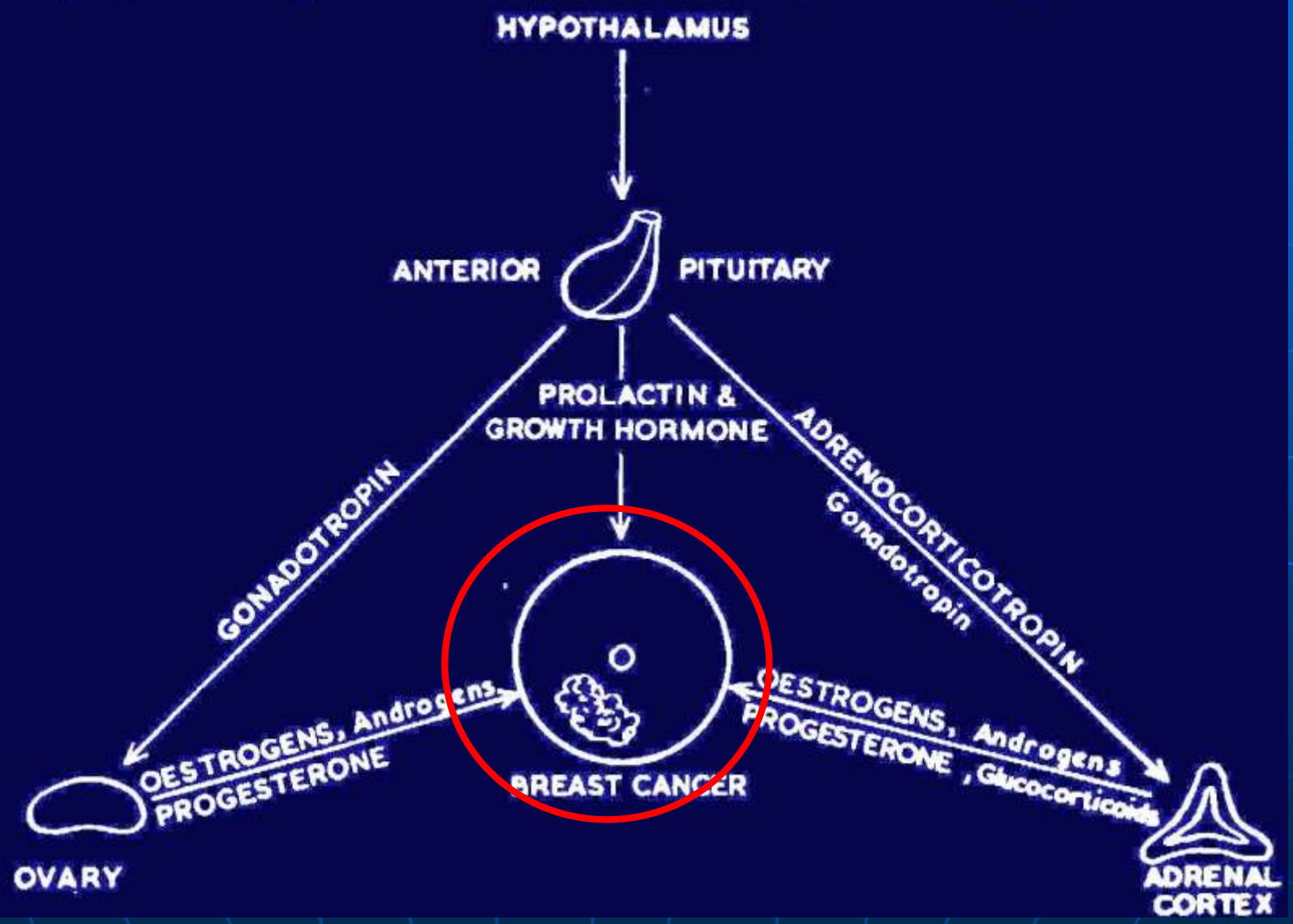
# Hemioterapija

4. Kaj povečeto primeneti {emi na terapija nema zna~ajno podobruvawe ako se davat podolgo od **3-6 meseci**,

5. Primenata na antraciklini (doksirubicin ili adriamicin) **AC protokol** se poefektivni vo tretmanot na malignom na dojka sporedeno so klasi~niot **CMF**

# HORMONOTERAPIJA

# Predmenopauzalna hormonska kontrola



# Hormonska terapija

Hormonskata terapija treba da go onevozmò i dejstvoto na estrogenite vrz tumorot, odnosno nivnoto vrzuvawe so soodvetniot receptor prisaten na povr{inata na kletkata.

-davawe lekovi koi go **blokiraat receptorot na povr{inata na malignata kletka (tamoxifen).**

# Hormonska terapija

-**supresija na sintezata na estrogeni** preku davawe na **aromataza inhibitori (anastrozole)** kaj `eni vo postmenopauza, odnosno **LHRH agonisti- (goserelin)** kaj `eni vo premenopauza.

-**destrukcija na ovariumite**, kaj premenopauzalni `eni. Istata mo`e da se izvede so hirur{ka ekstirpacija, zra~no ili hemiski so davawe hemioterapija.

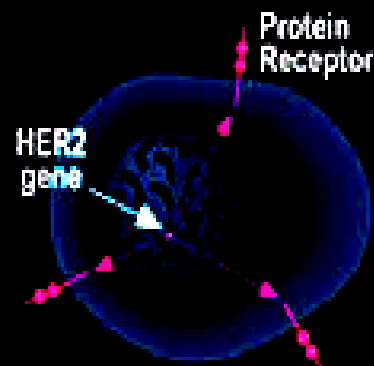
# Imunoterapija / genska terapija

- Herceptin

# Imunoterapija

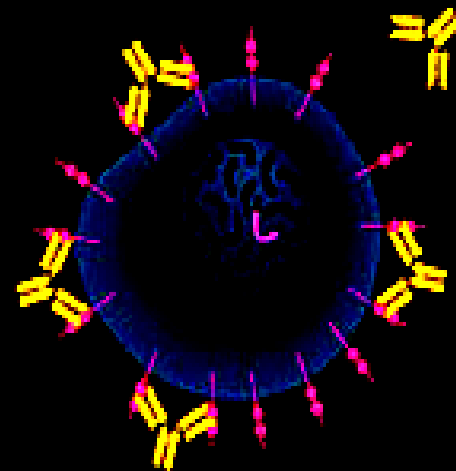

## HER2 Overexpressing Cancer Cell

Cancerous breast tissue cells that overexpress (or overproduce) the HER2 gene produce extra protein receptors on the cell surface which triggers the cell to divide and multiply at an accelerated rate thus contributing to tumor growth.



## Normal Cell

In normal breast tissue cells, the HER2 gene produces a protein receptor on the cell surface. These growth factor-like receptors are thought to play a role in normal cell growth by signaling the cell to divide and multiply.

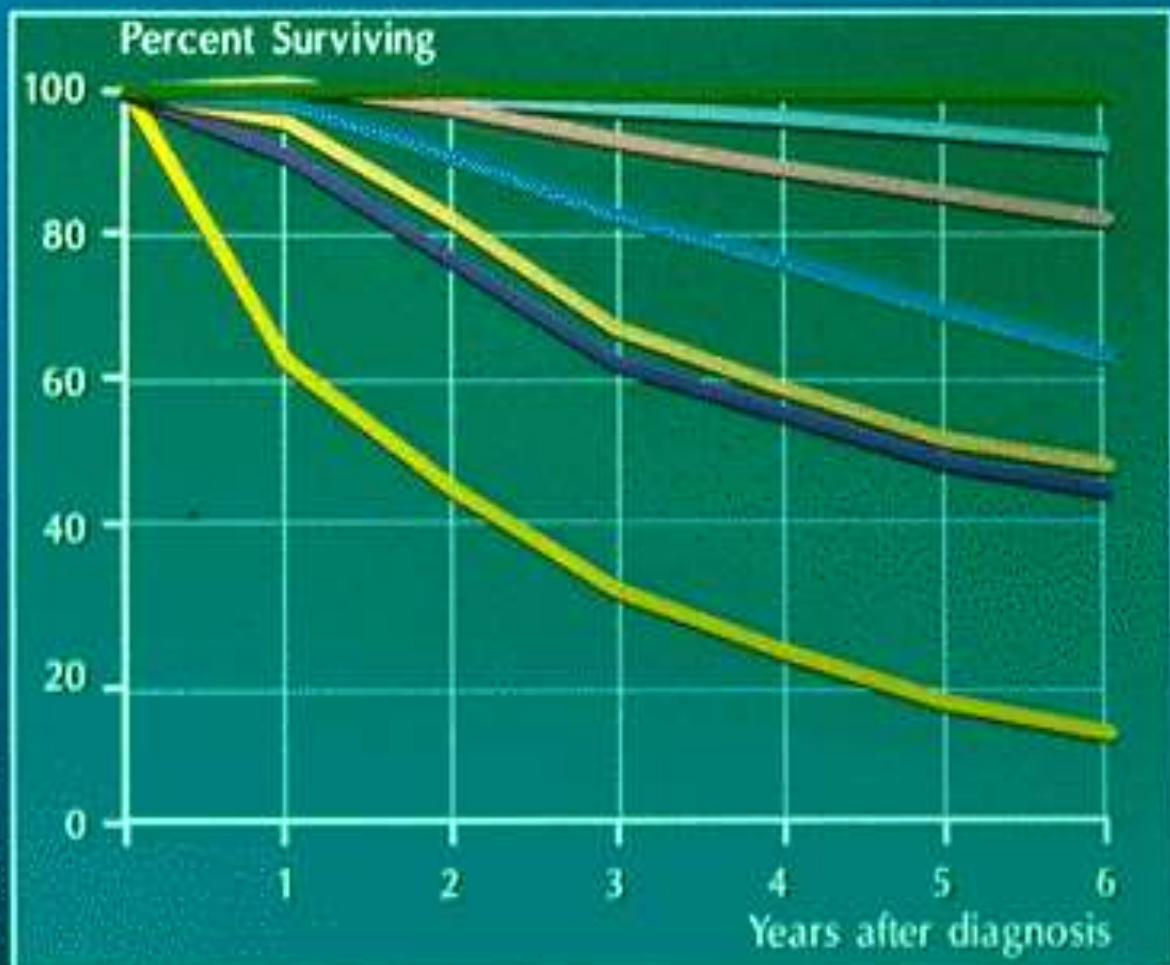


## Herceptin® (Trastuzumab)

Herceptin (a Her2 antibody) binds to numerous HER2 receptor sites found on the cell surface, blocking the receptor sites and possibly preventing further growth by interrupting the growth signal. As a result, the HER2 antibody may slow progression of the disease.



# BREAST CANCER SURVIVAL BY STAGE



- Stage 0
- Stage I
- Stage IIA
- Stage IIB
- Stage IIIA
- Stage IIIB
- Stage IV

<b>primarno mesto na malignom</b>	<b>5-godi{no pre`ivuvawe</b>
<b>bel drob</b>	<b>14%</b>
<b>kolon-rektum</b>	<b>63%</b>
<b>dojka</b>	<b>85%</b>
<b>prostata</b>	<b>93%</b>



*Is she out of door?*

